

Aus dem Institut für Pathologie
(Direktor: Prof. Dr. med. C. Röcken)
Sektion Hämatopathologie und Lymphknotenregister
(Leiter: Prof. Dr. med. W. Klapper)
im Universitätsklinikum Schleswig-Holstein, Campus Kiel
an der Christian-Albrechts-Universität zu Kiel

Characterization of follicular dendritic cells
in non-Hodgkin lymphomas
by multicolor fluorescence staining and digital image analysis

Inauguraldissertation
zur Erlangung der Doktorwürde
der Medizinischen Fakultät
der Christian-Albrechts-Universität zu Kiel

vorgelegt von

Mi Kyung Jin

aus Seoul, Republik Korea

Kiel 2011

Erster Berichterstatter: Prof. Dr. med. W. Klapper

Zweiter Berichterstatter: PD. Dr. med. C. Schrader

Tag der mündlichen Prüfung: 29.05.2012

Zum Druck genehmigt: Kiel, den 29.05.2012

gez. Prof. Dr. med. I. Leuschner

Contents

Abbreviations	II
1 Introduction	1
1.1 Follicular dendritic cells and their functions	1
1.2 Follicular dendritic cells in non-Hodgkin lymphomas	5
1.3 Aim of the study	7
2 Materials and methods	8
2.1 Case selection	8
2.2 Fluorescence immunohistochemistry	9
2.2.1 Preparation of microscopic sections	9
2.2.2 Fluorescence immunohistochemistry	10
2.2.3 Antibodies, chemicals and utensils	12
2.3 Analytical methods	14
2.3.1 Digital image analysis	14
2.3.2 Statistical analysis	16
3 Results	18
3.1 Morphological results	18
3.2 Clinical results	24
4 Discussion	27
5 Summary	37
6 Appendix	39
7 References	42
Acknowledgements	49
Curriculum vitae	50

Abbreviation

Ab	antibody
Ag	antigen
AIDS	acquired immune-deficiency syndrome
AITL	angiimmunoblastic T cell lymphoma
APES	aminopropyltriethoxysilane
AR	antigen retrieval
BAFF	B cell activating factor of the TNF family
BLys	B lymphocyte stimulator
BM	bone marrow
BSA	bovine serum albumin
°C	degree Celsius
CD	cluster differentiation
CHOP	cyclophosphamide, doxorubicin, vincristine, and prednisone
CR	complement receptor
DZ	dark zone
ECOG	Eastern Cooperative Oncology Group
FDC	follicular dendritic cell
FFPE	formalin-fixed, paraffin-embedded
FL	follicular lymphoma
FLIPI	Follicular Lymphoma International Prognostic Index
g	gram
GC	germinal center
GLSG	German Low-Grade Lymphoma Study Group
Hb	hemoglobin
HCl	hydrochloride
HSA	human serum albumin
IC	immune complex
ICAM-1	intercellular adhesion molecule-1
Ig	immunoglobulin
IL	interleukin
l	liter
LDH	lactate dehydrogenase
LFA-1	lymphocyte function-associated antigen-1
LZ	light zone

MCP	mitoxantron, chlorambucil, prednisone
MHC	major histocompatibility complex class
MCL	mantle cell lymphoma
mg	milligram
NaCl	sodium chloride
NaOH	sodium hydroxide solution
NHL	non-Hodgkin lymphoma
OS	overall survival
PBS	phosphate-buffered saline
SD	standard deviation
TNF	tumor necrosis factor
TRIS	tris(hydroxymethyl)aminomethane
TSE	transmissible spongiform encephalitis
TTF	time-to-treatment failure
ULN	upper limit of normal
VCAM-1	vascular cell adhesion molecule-1
VLA-4	very-late activation antigen 4
WHO	World Health Organization

1 Introduction

1.1 Follicular dendritic cells and their functions

Germinal centers (GC) are sites of antibody affinity maturation within the follicles of lymph nodes and other secondary lymphoid organs. They are compartmentalized into two major zones: dark and light zones. In the dark zones (DZ) large centroblasts rapidly proliferate and undergo somatic mutation of their antibody variable region genes. Whereas in the light zones (LZ) small centrocytes compete for binding antigen on follicular dendritic cells (FDC) and receive signals from helper T cells to survive and differentiate into high affinity antibody secreting plasma cells or memory B cells (Allen, Cyster, 2007a).

Follicular dendritic cells represent a unique population of non-lymphoid accessory cells inside germinal centers defined by the following features: (a) they are localized within the primary and secondary lymphoid follicles under reactive conditions (Allen, Cyster, 2008; Maeda et al., 2002; Park, Choi, 2005; Yoshida et al., 1993); (b) morphologically they have long dendritic extensions between B cells and form a cellular network by reciprocal connections of their intricately entangled cytoplasmic processes with frequent desmosome-like connections to sustain the architecture of lymphoid follicles (Kasajima-Akatsuka, Maeda, 2006; Maeda et al., 2002); (c) functionally they have the ability to trap and retain antigens for long periods of time in the form of immune complexes (IC) (El Shikh et al., 2006); and (d) they express a variety of molecules involved in the proliferation and differentiation of lymphocytes, especially of B cells, and promote their survival (Allen, Cyster, 2008; El Shikh et al., 2006; Park, Choi, 2005).

The cellular interactions between FDC and germinal center B cells are carried out in

co-operation with a variety of molecules (Figure 1). The first group of molecules comprises pairs of adhesion molecules; intercellular adhesion molecule-1 (ICAM-1) (CD54) on FDC with lymphocyte function-associated antigen-1 (LFA-1) on B cells and vascular cell adhesion molecule-1 (VCAM-1) on FDC with very-late activation antigen 4 (VLA-4) on B cells. They enhance cell-cell contacts and thus facilitate the anti-apoptotic functions of FDC (Park, Choi, 2005). The second group comprises anti-apoptotic molecules produced by FDC such as tumor necrosis factor (TNF) superfamily ligand BAFF (B cell activating factor of the TNF family), also known as BLys (B lymphocyte stimulator). They are required for B cell maturation and prevent apoptosis of GC B cells (Park, Choi, 2005; Schiemann et al., 2001; Thompson et al., 2000). The third group of molecules comprises those related to the proliferation of GC B cells such as 8D6 and membrane-bound interleukin (IL)-15 (Park et al., 2004; Park, Choi, 2005). Another important functional group of molecules include those involved in immune complex display. FDC do not internalize, process and present antigen in the context of major histocompatibility complex class II (MHC II), but present intact antigen-antibody (Ag-Ab) in the form of immune complexes on their surfaces. They are held by Fc binding receptors such as CD23 or complement receptors such as CD21 and CD 35 (Allen, Cyster, 2008; Park, Choi, 2005).

The dark and light zones of GC are two different compartments with regard to the proliferation and differentiation of GC B cells with its specific microenvironment. In the dark zone, rapidly dividing centroblasts produce non-proliferating centrocytes that are thought to migrate to the light zone of the germinal center and either differentiate into memory B cells or antibody-secreting cells or undergo apoptotic cell death (Freedman et al., 1995; Rademakers, 1992; Schwickert et al., 2007). In accordance with the function of the GC compartments, there is a different distribution pattern of

distinct FDC subtypes in the light and dark zones of GC (Li, Choi, 2002). FDC are present at a much higher density in the light zone than in the dark zone (less than 2% of the cell population) (Freedman et al., 1995; Yoshida et al., 1993). And the light zone FDC strongly express Fc fragment-binding proteins such as CD23 and CD32 and complement receptors such as CD21 (CR2) and CD35 (CR1) in comparison to the dark zone FDC, suggesting functional and phenotypical heterogeneity of FDC in GC (Yoshida et al., 1993).

In the GC, where the major events of anamnestic humoral immune responses are thought to take place, the interaction between FDC and B cells, especially the ability of FDC to present immune complexes to GC B cells, is assumed to play a pivotal role in the selection of antigen-specific B cells and their clonal expansion (Kasajima-Akatsuka, Maeda, 2006; Allen et al., 2007a; Allen et al., 2007b). Even though the fundamental biology and behavior of FDC have not yet been fully defined, it seems very likely that the integrity of FDC networks not only significantly influences GC reactions, but also plays a central role in the pathogenesis of several diseases e.g. lymphoma, acquired immune-deficiency syndrome (AIDS), transmissible spongiform encephalitis (TSE) and autoimmune diseases such as rheumatoid arthritis (Li, Choi, 2002; Kosco-Vilbois, 2002; Park, Choi, 2005). Thus, it gives us rise to study more closely the altering FDC function and its consequences.

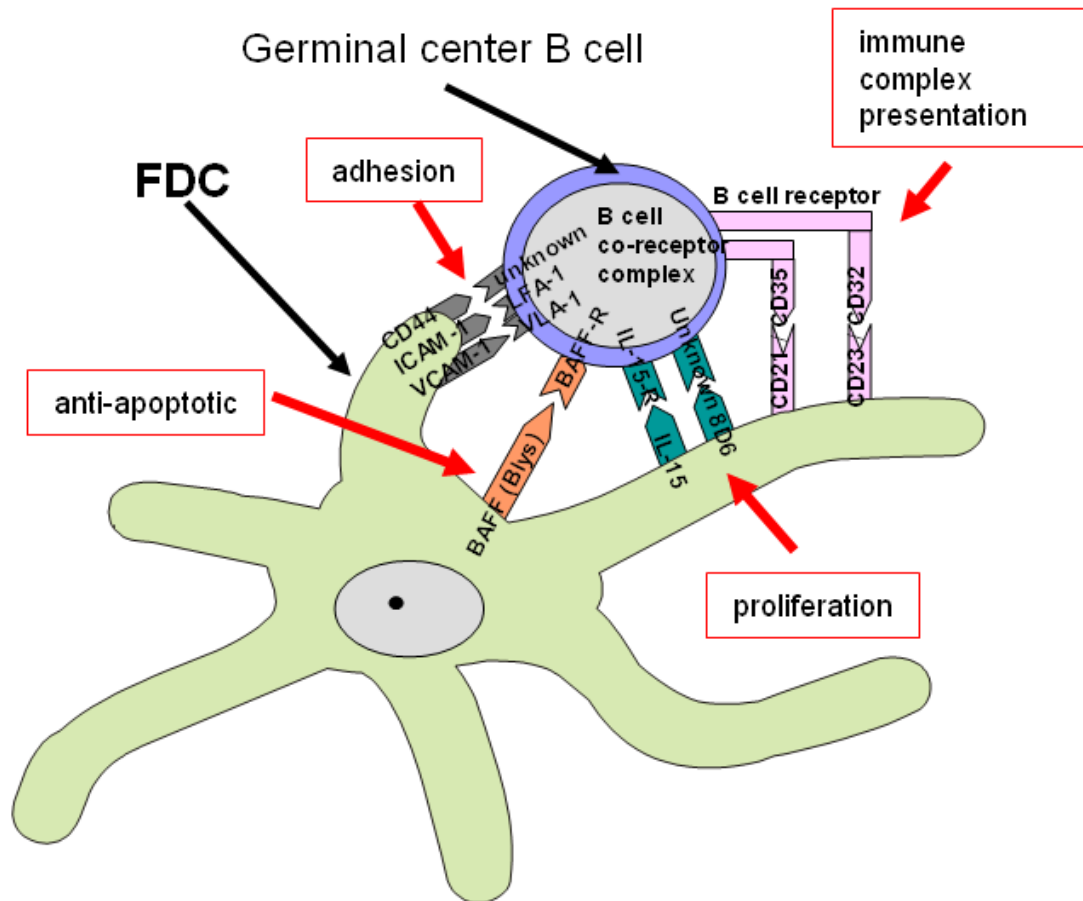


Figure 1: Interaction between FDC and GC B cell. FDC interact with GC B cells via several mechanisms including adhesion molecules such as ICAM-1 and VCAM-1, B cell anti-apoptotic TNF superfamily ligand BAFF, Fc binding proteins such as CD23 and complement receptors such as CD 21 for immune complex presentation and 8D6 and membrane-bound interleukin (IL)-15 for B cell proliferation.

1.2 Follicular dendritic cells in non-Hodgkin lymphomas

FDC form a three-dimensional network in the GC, a dynamic microenvironment where antigen-activated B cells expand and undergo events associated with antibody affinity maturation and the majority of B cell lymphomas originate from (Allen, Cyster, 2008; Küppers et al., 1999; Park, Choi, 2005). Because of the intimate relationship between FDC and B cells, FDC is expected to affect B cells and even play a role in pathogenesis of neoplastic lymphoproliferations in yet uncertain way (Bagdi et al., 2001). In certain B cell non-Hodgkin lymphomas (NHL) FDC can be detected among the reactive bystander cells of the tumor (Bagdi et al., 2001). Whereas in marginal zone lymphomas FDC are considered to represent remnants of GC that have been colonized by lymphoma cells, it has been suggested that FDC in mantle cell lymphoma (MCL), follicular lymphoma (FL) and angioimmunoblastic T cell lymphoma (AITL) are newly generated and have proliferated during lymphoma growth and expansion (Swerdlow et al., 2008).

Structural alterations in the network of FDC such as atypical shape or expansion are also frequently found in malignant lymphoma and can be useful adjunct in the diagnostic immunophenotyping of the malignant lymphomas (Bagdi et al., 2001). In FL the abnormal follicles demonstrate dense, sharply defined and expanded FDC networks reminiscent of those seen in the normal germinal centers. They are exclusively found within malignant follicles and absent in the interfollicular lymphoma compartment as well as in diffusely growing FL (Bagdi et al., 2001; Klapper et al., 2007). In MCL loosely arranged, weakly developed FDC network in nodular or diffuse patterns are observed (Bagdi et al., 2001, Schrader et al., 2006). And the most common morphological subtype of AITL (pattern 3) shows a prominent diffuse proliferation of FDC network with frequent incorporation of proliferating postcapillary venules, an important hallmark of the disease since this pattern has not been found

in any other T cell lymphomas hence facilitating the differential diagnosis (Attygalle et al., 2002; Bagdi et al., 2001).

The immunophenotype of FDC in reactive and neoplastic lymphoid tissues has been characterized, and reduced expression of markers of mature FDC was noted in FL and MCL (Bagdi et al., 2001; Chang et al., 2003). Recently, gene expression profiling, a quantitative method, has revealed that the expression of FDC-related genes is associated with the clinical course in follicular lymphoma (Dave et al., 2004). Another study has shown that the growth pattern and distribution of FDC in mantle cell lymphoma are associated with the clinical outcome (Schrader et al., 2006). Thus, further study of the altering FDC function may provide invaluable information for understanding and classifying malignant lymphomas and a target for clinically manipulating disease.

1.3 Aim of the study

Inspired by the recent findings about the accessory functions of FDC and the close relationship between FDC and B cells, we decided to study the different immunophenotypes of FDC and its morphological and clinical correlation. Since FDC are large cells with long dendritic extensions and hardly detectable cell bodies, the quantification of the extent of FDC networks or the immunophenotype of FDC using conventional staining and light microscopy is highly observer-dependent. Thus, we developed a method employing multicolor immunofluorescence staining followed by digital image analysis to detect FDC with its dendritic extensions.

The aims of our study were:

1. To characterize differences and similarities between the FDC immunophenotypes in the functional compartments of the reactive GC,
2. to characterize differences and similarities between the FDC immunophenotypes in NHL which contained FDC as reactive bystander cells, namely FL, MCL and AILT, and compare them with those in GC in order to gain insights into a possible role of FDC in lymphoma development and
3. to quantify the extent of FDC networks precisely in an example of NHL, namely FL, and to correlate the extent of FDC networks with clinical outcome in FL.

2 Materials and methods

2.1 Case selection

Formalin-fixed, paraffin-embedded (FFPE) tissue samples from representative examples of tonsils (n = 10), follicular lymphoma grades 1 or 2 (n = 5), mantle cell lymphoma, classical type (n = 7), and angioimmunoblastic T cell lymphoma (n = 5) were selected from the files of the Lymph Node Registry in Kiel. The lymphoma biopsy specimens were anonymized according to the ethical guidelines of the Medical Faculty of the University of Kiel (institutional review board) for retrospective analysis of archived material. All cases were classified according to the WHO classification by means of morphological examination and immunophenotyping on paraffin sections (Swerdlow et al., 2008).

For clinical correlation, 108 formalin-fixed, paraffin-embedded lymph node biopsy specimens were analyzed from the patients with advanced stage follicular lymphoma recruited between May 1996 and December 2000 for the trial “CHOP versus MCP” of the German Low-Grade Lymphoma Study Group (GLSG) from the reference pathology departments in Kiel, Würzburg, Frankfurt and Lübeck (Nickenig et al., 2006). The admission criteria to the study were the age >18 and an untreated follicular lymphoma in Ann-Arbor-Stage III or IV. Furthermore, the necessity of a therapy must exist, characterized by at least one of the following criteria: 1. B-symptoms, 2. hematopoietic insufficiency, 3. rapid progress of the disease, 4. Bulk-formation.

In this study only primary biopsies obtained before any treatment for advanced stage FL were analyzed. All studies were performed on full sections of the biopsy specimen. For analysis of patient material from the GLSG trials, informed consent of the patients

was available. After the randomization, all of the patients were either assigned to CHOP (cyclophosphamide, doxorubicin, vincristine and prednisone) or MCP (mitoxantron, chlorambucil and prednisone) therapy.

Parameter	Value	No.	%	% of all study patients*
Age	≥ 60	29	21	26
Sex	Male	60	44	50
Stage (n = 136)	IV	94	69	71
B-symptoms (n = 136)	present	53	39	40
Spleen involvement (n = 126)	present	35	28	35
BM involvement	present	91	66	67
extranodal sites	> 1	19	14	23
Involved nodal areas (n = 136)	> 4	104	76	68
ECOG performance status	> 1	7	5	10
LDH	> ULN	40	29	30
Hb (n = 135)	< 120 g/l	20	15	19
FLIPI (n = 135)	Low	21	16	14
	Intermediate	57	42	40
	High	57	42	46

* All patients with advanced follicular lymphoma registered to the trial

Table 1: Clinical baseline characteristics of the population studied in this report (n = 137) compared with all patients with advanced stage follicular lymphoma registered in the trial (n = 538).

Abbreviations: BM = bone marrow, ECOG = Eastern Cooperative Oncology Group, LDH = lactate dehydrogenase, Hb = hemoglobin, FLIPI = Follicular Lymphoma International Prognostic Index, ULN = upper limit of normal.

2.2 Fluorescence immunohistochemistry

2.2.1 Preparation of microscopic sections

Four-micrometer thick sections of the tonsil or lymph node formalin-fixed and paraffin-embedded tissues were mounted on 3-aminopropyltriethoxy silane (APES)-

coated slides and subsequently incubated at 37°C overnight. They were deparaffinized in xylol for 10 minutes and rehydrated in a series of degraded ethanol (100%-100%-100%-96%-96%-70%).

Antigen retrieval:

Because of the superior preservation of morphology, formalin-fixed, paraffin-embedded tissue remains the medium of choice for most clinical and research studies. However, the fixation in formalin can result in the loss of immunoreactivity of the antigens (Key, 2006). To detect the reactive epitopes in formaldehyde-fixed material previous antigen retrieval (AR) is required. Antigen retrieval or antigen recovery is a technique performed to expose antigens which have become masked by the tissue fixation process. There are various protocols available, such as heat exposure or enzyme application. In this study, several antigen retrieval methods were tested to obtain reliable staining for each marker. The slides with tissue sections to be used for double staining were boiled in citric acid buffer at pH 3.0 for 4 minutes in a pressure cooker. This procedure yielded staining patterns for each antibody that were comparable to single staining. The extent of FDC networks in study samples to be used for clinical correlation was assessed by single staining using Ki-M4p or CD23. The epitopes for Ki-M4p were unmasked by digesting the sections with protease XXIV at pH 7.5 for 20 minutes, for CD23, the previous protocol with citric acid buffer was applied. After the antigen retrieval, the slides were transferred without delay to cold running water for washing and then immersed in phosphate-buffered saline (PBS) buffer.

2.2.2 Fluorescence immunohistochemistry

Pan-FDC marker, Ki-M4p

A number of monoclonal antibodies that detect FDC have been developed to define

their unique immunophenotype. Some of them, such as X-11 and 12B1 are known to detect FDC located in the light zone of GC (LZ pattern) whereas anti-S100 α is only reactive for FDC located in the dark zone of GC (DZ pattern). In this study, we have applied Ki-M4p, a mouse monoclonal antibody detecting FDC network through the whole of the lymphoid follicle, as pan-FDC marker (Maeda et al, 2002; Parwaresch et al., 1983).

Primary antibodies such as rabbit anti-human CD23, rabbit anti-human CD35 and goat anti-human CD54 were diluted 1:50 in 1%-bovine serum albumin (BSA), the matching fluorescent secondary antibodies were diluted 1:50 in 1%-human serum albumin (HSA). Ki-M4p was applied as undiluted cell culture supernatant from our laboratory (Parwaresch et al., 1983).

The staining protocols were carefully established to avoid non-specific staining of cells other than FDC. The incubation of the first primary antibodies such as Ki-M4p or CD23 was performed overnight in a moisturized chamber at room temperature. Matching fluorescence-labeled secondary antibodies (Alexa Fluor 488 or Alexa Fluor 594; Invitrogen, Carlsbad, CA, USA, diluted 1:100) were incubated on the sections in a moisturized chamber for 60 minutes at room temperature. Afterwards, the sections were thoroughly washed with PBS three to four times and covered manually using fluorescent mounting medium.

For double staining, Ki-M4p was combined with one of the following antibodies: rabbit anti-human CD23 (Neomarkers, Fremont, CA, USA), rabbit anti-human CD35 (Santa Cruz Biotechnology, Santa Cruz, CA, USA) or goat anti-human CD54 (R&D Systems, Minneapolis, MN, USA).

Second primary antibodies such as CD23, CD35 and CD54 were then incubated on the already with Ki-M4p stained sections in a moisturized chamber for 60 minutes at

room temperature. Afterwards, the sections were thoroughly washed with PBS buffer three to four times. Matching fluorescent secondary antibodies (Alexa Fluor 594 anti-rabbit IgG for CD23 and CD35; Alexa Fluor 594 anti-goat IgG for CD54) were then incubated on the sections in a moisturized chamber for 60 minutes at room temperature. Afterwards, the sections were thoroughly washed with PBS buffer four to five times. The sections were covered manually applying fluorescent mounting medium and the cover glass was encircled with a transparent nail polish to protect the fluorescent dye. Subsequently, the sections were preserved in a refrigerator.

2.2.3 Antibodies, chemicals and utensils

Antibodies	Sources
Mouse anti-human Ki-M4P	Department of Hematopathology, University of Kiel, Germany
Rabbit anti-human CD23 (SP23)	NeoMarkers, No. RM-9123-S
Rabbit anti-human CD35 (H-300)	Santa Cruz Biotechnology, No. sc-20924
Goat anti-human ICAM-1/CD54	R&D Systems, No. BBA17
Alexa Fluor 488 F(ab') ₂ fragment of goat anti-mouse IgG (H+L)	Invitrogen, No. A11017
Alexa Fluor 488 donkey anti-rabbit IgG (H+L)	Invitrogen, No. A21206
Alexa Fluor 594 donkey anti-rabbit IgG (H+L)	Invitrogen, No. A21207
Alexa Fluor 594 donkey anti-goat IgG (H+L)	Invitrogen, No. A11058

Table 2: Antibodies and their sources

Buffers	Fabrication formula
Citrate buffer	2,1 g Citric acid-monohydrate in 1 l distilled water, titrated with NaOH (2 mol/l) and HCl (2 mol/l) until either pH 3 is reached
TBS buffer	9,0 g TRIS- Base , 68,5 g TRIS-HCl, 87,8 g NaCl in 10 l distilled water
Protease	0,02 g Protease XXIV (Sigma, P-8038) in 200 ml TBS-buffer, pH 7,5 at 37°C
PBS buffer	100 ml of 10x concentrated PBS diluted with 900 ml of distilled water

Table 3: Buffers, solutions and fabrication formula

Chemicals	Manufacturer
Bovine serum albumin	Sigma, No. A-4503
Citric acid-monohydrate	Merck, No. 1.00244
Distilled water	DeltaSelect, No. 23705-12A
Ethanol	Merck, No. 1.00983
Fluorescent mounting medium	DakoCytoformation, No. S3023
Hydrochloride (HCl, 2 Mol)	Merck, No. 1.09063
Nail polish	Essence, multi dimension 01
PBS 10x, pH7,2, CaCl ₂ , MgCl ₂	GIBCO, No. 70013-016
Protease XXIV	Sigma, No. P-8038
Sodium chloride (NaCl)	Walter & Co
Sodium hydroxide solution (NaOH, 2 Mol)	Merck, No. 1.09136
TRIS base	Sigma, No. T-1503
TRIS HCl	Sigma, No. T-3253
Xylo	Merck, No. 1.08681

Table 4: Chemicals and their sources

Human serum albumin was available by courtesy of the Institute of Transfusion Medicine, University of Kiel. It was frozen in 1ml-aliquots at – 20 °C after inactivation for 30 minutes at 65 °C in water bath.

Utensils	Manufacturer
Axioplan 2 imaging and Axiophot 2 Universalmikroskop	ZEISS
Cover glass 24 x 50mm	Menzel Gläser
Glass slide	Marienfeld, No. 1000200
Glove Nitra-Tex	Ansell, No. 4400013/70052
Glove Peha-Soft	Hartmann, No. 942162
Incubator	Memmert
Lamp N HBO 100	ZEISS, No. 000000 1007-980 ZEISS, No. 000000 1002-928
Mercury vapor short arc lamp	OSRAM, No. 380301-9350
Microscopic slide HistoBond, PES-coated, 76x26x1mm	Marienfeld, No. 0810000
Objective: Plan-NEOFluar 20x/0,50	ZEISS

Pipets	Eppendorf
Pressure cooker	TEFAL
Sliding microtome	Reichert-Jung, No. Hn 40
SPOT slider - RT Realtime	Visitron Systems GmbH, No. 998258
Water bath	Köttermann

Table 5: Utensils and their sources

2.3 Analytical methods

2.3.1 Digital image analysis

Software	Manufacturer
Adobe Photoshop 7.0	Adobe Systems
analySIS™ FIVE	Olympus Soft Imaging System
MetaView Imaging Software	Visitron Systems GmbH, No. 5826
GraphPad prism	Graph Pad Prism Software Inc.

Table 6: Software and their sources

In every section, five independent areas containing a GC in tonsils, a malignant follicle in FL or areas with FDC networks in MCL or AITL were selected and photographed at a magnification of x 200 (Axioscope 40 microscope Zeiss, Jena, Germany, equipped with an Image View Camera, Soft Imaging Systems Olympus, Hamburg, Germany and MetaView Imaging Software, Visitron Systems GmbH, Puchheim, Germany) at room temperature. To ensure that areas with FDC were analyzed exclusively, the GC or FDC-containing areas were cut out of the pictures by means of Adobe Photoshop 7.0 and pasted into a separate blank image with a white background. The dark zone of the GC can be easily identified because of the reduced FDC network and was isolated from the rest of the GC in the same manner. All images were analyzed using the software analySIS™ (Soft Imaging Systems Olympus, Hamburg, Germany). For this purpose, the area that stained positively for each or both antibodies was measured in square pixels. The percentage of all FDC

co-expressing CD23, CD35 or CD54, as assessed by the pan-FDC marker Ki-M4p, was calculated (% co-expression). All values are expressed as means with the standard deviation (SD) indicated.

For correlation of FDC networks with clinical outcome in FL, we looked for a measure of the density of the FDC network within the follicles. For this, the area covered by the FDC within 5 representative malignant follicles was quantified analogous to the double staining and expressed as FDC covered area in relation to the whole area of the neoplastic follicle.

Phase analysis (Soft Imaging System GmbH, 2002):

Phase analysis of analySIS™ is a quantitative evaluation of area with regard to each separate color phase. The definition of numerous color ranges which are assigned to individual phases is a prerequisite.

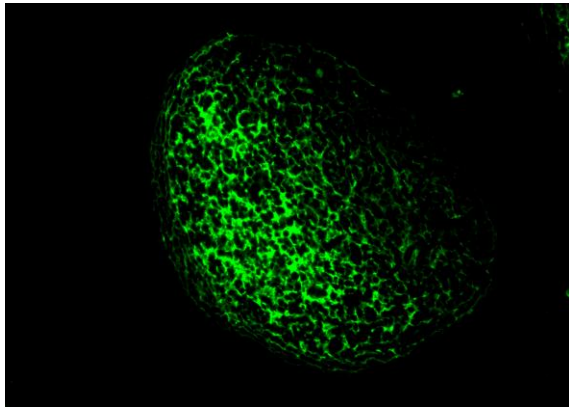
How to conduct phase analysis:

- 1) Load a Photoshop image (from the step 2.3.1) you wish to analyze into the active image buffer.
- 2) Select the [Image>Set Color Thresholds...](#) command to define the color ranges for the separate phases.
- 3) Delete all phases already defined except one. To do this, select an entry from the [Phase](#) list and click the [Delete](#) button. As soon as only one phase is defined the [Delete](#) button will become inactive.
- 4) Define the phase using the [Include Pixel](#) or [Exclude Pixel](#) buttons.
- 5) Click the [New](#) button to add a second phase. A new entry will be added to the [Phase](#) list. The new phase will automatically be colored in a color not yet taken. If you like, you can alter the color by selecting one from the [Color](#) palette. The newly-added phase will now be activated.

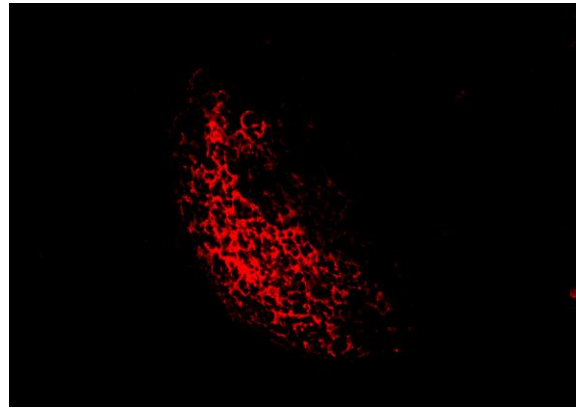
- 6) Define the color range for the second, third, fourth etc. phases.
- 7) Confirm the new threshold setting by clicking on **OK**.
- 8) Select the **Measure > Phase Analysis** command. Your image analysis program will create a measurement sheet showing the absolute area and proportional area (in %) of all the phases. Save the measurement sheet as an appropriate name.
- 9) Select the **Measure > Phase Color Coding** command to generate a false-color image based on the color phases defined. The color of the phase will correspond to the header color in the measurement sheet.
- 10) Now load the next image you wish to analyze.
- 11) Select the **Measure > Phase Analysis** command. The thresholds currently set are still valid. Phase analysis will be conducted based on these thresholds. The measurement values will be appended to the existing sheet.

2.3.2 Statistical analysis

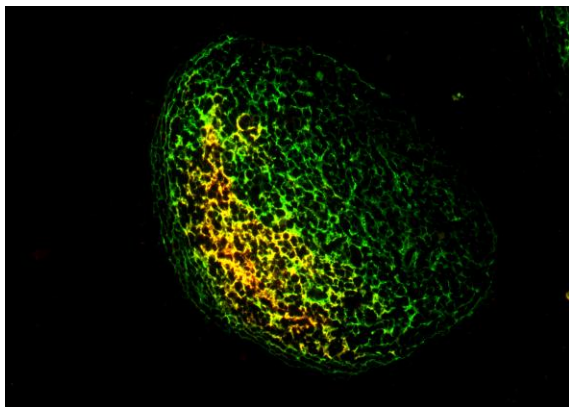
Co-expression was compared by means of t-tests using GraphPad prism (Graph Pad Prism Software Inc., San Diego, CA, USA). To assess the prognostic impact of FDC networks on overall survival (OS) and time-to-treatment failure (TTF), Kaplan-Meier curves were calculated and group comparisons were done by means of the log-rank test. The prognostic impact of numerical parameters was assessed by univariate and adjusted Cox regression.



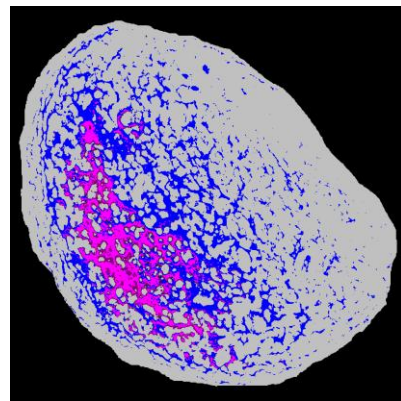
(A) Ki-M4p



(B) CD23



(C) CD23+Ki-M4p



(D) Phase Analysis

Figure 2: Representative examples of fluorescent double staining using the pan-FDC marker Ki-M4p (A, single staining), CD23 (B, single staining), Ki-M4p and CD23 (C, double staining) and quantitative image analysis “Phase analysis” (D) with software analySIS™ to assess the extent of co-expression.

3 Results

3.1 Morphological results

Aim 1: Characterization of FDC immunophenotypes in reactive GC

GC of lymphoid follicles contain two different microenvironmental zones: the dark zone and the light zone. The dark zone at the base of the follicular center contains tightly packed centroblasts whereas the light zone at the apex contains non-dividing centrocytes. The follicular dendritic cell network extends throughout the GC, but is much sparser in the dark than in the light zones (Freedman et al., 1995; Carbone et al., 2009). In accordance with the function of the GC compartments and the different distribution pattern of FDC, heterogeneity of FDC immunophenotypes in reactive GC is expected (Li, Choi, 2002). Here, we studied the FDC immunophenotypes in the dark zone, light zone and in the whole GC applying pan-FDC marker, Ki-M4p and other FDC functional groups such as CD23, CD35 and CD54. As a control of our fluorescence double staining method for quantifying FDC protein expression, five GC were analyzed in each of 10 hyperplastic tonsils. The dark zone of the GC was analyzed separately and compared to the entire GC, which is dominated by the dense FDC networks of the light zone. Since the light zone contained more FDC than the dark zone as shown in Figure 3, the values for the whole follicle resembled mainly light zone FDC. In all analyses, the area detected by the marker Ki-M4p was larger than the area staining for CD23, CD35 or CD54, indicating that Ki-M4p is useful as a pan-FDC marker (Parwaresch et al., 1983). As shown in Figure 4 and in Table 7, the dark zone FDC displayed reduced co-expression of the Fc-receptor/CD23 (8.5%, SD 5.2), complement receptor 1/CD35 (20.2%, SD 6.9) and ICAM-1 (intercellular adhesion molecule-1)/CD54 (19.0%, SD 6.8), compared to the

FDC in the entire follicle (CD23: 32.1%, SD 10.8; CD35: 38.9%, SD 15.7; CD54: 37.2%, SD 10.8), and the differences were statistically significant ($P < 0.0001$, $P = 0.0029$ and $P = 0.0003$, respectively, t-test). These data are in line with the published literature, which are based mainly on the analysis of mouse GC and confirm our method for detecting protein expression semi-quantitatively in FDC (Bagdi et al., 2001; Chang et al., 2003; Yoshida et al., 1993).

Reactive GC

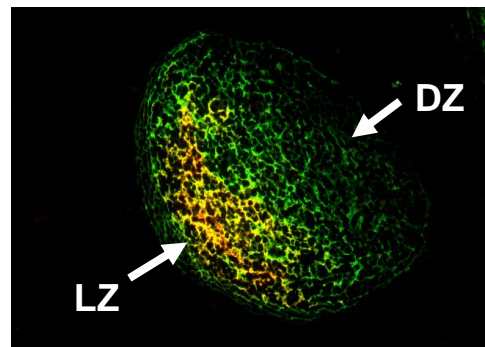


Figure 3: Representative example of fluorescence double staining using the pan-FDC marker Ki-M4p (green) and CD23 (red) in a reactive germinal center (GC). In the light zone (LZ), FDC are present in a much higher density than in the dark zone (DZ).

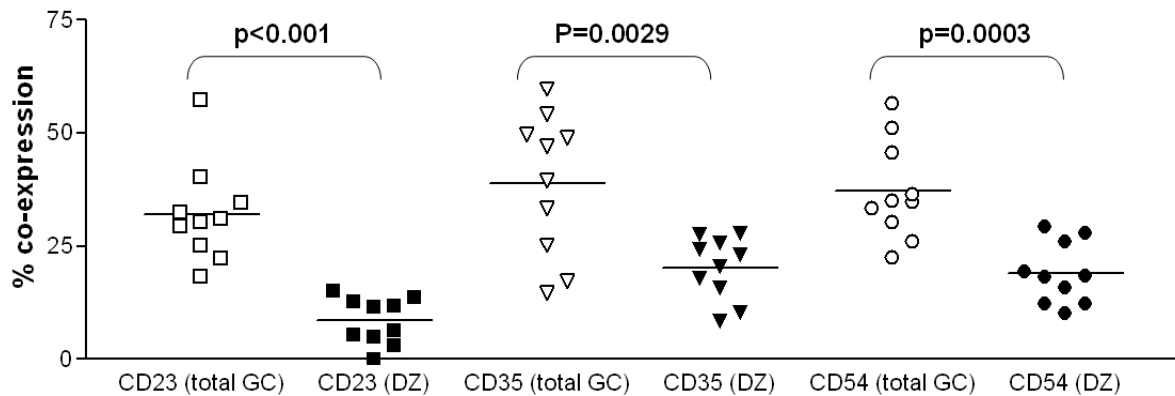


Figure 4: Quantitative analysis of co-expression of CD23, CD35 and CD54 on follicular dendritic cells (FDC) in the entire germinal center (total GC) or the dark zone (DZ) in tonsils. The FDC in the dark zone (DZ) of the GC display a reduced expression of the Fc-receptor (CD23), complement receptor 1 (CD35) and adhesion molecule ICAM-1 (CD54), compared to the FDC in the whole follicle (total GC), which is dominated by the light zone FDC. *P*-values were obtained using t-tests. Horizontal bars indicate the mean.

	Ki-M4p/CD23	Ki-M4p/CD35	Ki-M4p/CD54
Total reactive GC	32.1 (SD 10.8)	38.9 (SD 15.7)	37.2 (SD10.8)
DZ of reactive GC	8.5 (SD 5.2)	20.2 (SD 6.9)	19.0 (SD 6.8)

Table 7: Co-expression on FDC. All values as % co-expressing FDC area. GC = germinal center, DZ = dark zone, SD = standard deviation.

Aim 2: Characterization of FDC immunophenotypes in NHL

Staining pattern

The staining pattern of FDC networks in FL, MCL and AITL showed considerable difference regarding the extent, distribution and morphology. Figure 6 shows

representative examples of the staining pattern. In FL, the FDC network was dense and sharply defined inside the abnormal follicles reminiscent of those seen in the normal GC. Furthermore, FDC network was absent in the interfollicular lymphoma compartment. In MCL, FDC network was very weakly developed and of either small nodular or diffuse pattern which made locating the FDC network for our study difficult. Finally, in AITL, the FDC networks showed a diffusely expanding feature with irregular shape with frequent incorporation of postcapillary venules. These data were in line with the published literature (Attygalle et al., 2002; Bagdi et al., 2001; Klapper et al., 2007; Schrader et al., 2006).

Membrane-bound FDC functional groups

Compared with the FDC in the GC as a whole, the FDC in FL, AITL and MCL displayed significantly reduced expression of CD23 (FL: $P = 0.0012$, AITL: $P = 0.0214$ and MCL: $P = 0.0418$), CD35 (FL: $P = 0.0067$, AITL: $P = 0.002$, and MCL: $P = 0.001$) and CD54 (FL: $P = 0.0017$, AITL: $P = 0.0003$ and MCL: $P = 0.0007$). Figure 5 and Table 8 provide a summary of all data. The level of co-expression of the above mentioned markers in the lymphomas was comparable to that of the FDC in the dark zone of the GC (Table 8), with the exception of CD23, which was expressed at significantly higher levels in the FDC of AITL and MCL than in the dark zone of the GC ($P = 0.0031$, and $P = 0.0054$, respectively).

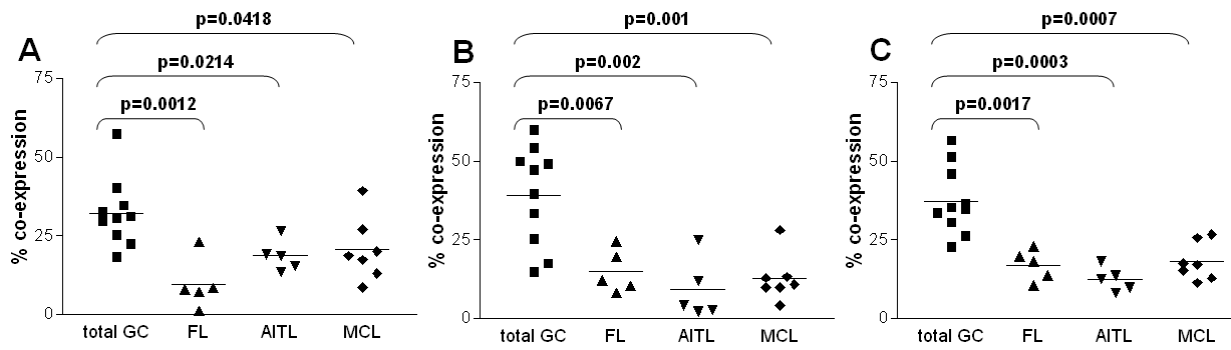


Figure 5: Quantitative analysis of co-expression of CD23 (A), CD35 (B) and CD54 (C) on FDC in the entire germinal center (total GC), follicular lymphoma (FL), angioimmunoblastic T cell lymphoma (AITL) and mantle cell lymphoma (MCL). FDC in FL, AITL and MCL display quantitatively reduced expression of CD23, CD35 and CD54 compared to the FDC in the entire GC. The levels of CD35 and CD54 co-expression in the lymphomas are comparable with the FDC in the dark zone of the GC (*P*-values not significant using a t-test, data shown in Table 8). *P*-values were obtained using t-tests. Horizontal bars indicate the mean.

	Ki-M4p/CD23	Ki-M4p/CD35	Ki-M4p/CD54
Total reactive GC	32.1 (SD 10.8)	38.9 (SD 15.7)	37.2 (SD10.8)
DZ reactive GC	8.5 (SD 5.2)	20.2 (SD 6.9)	19.0 (SD 6.8)
FL	9.5 (SD 8.1)	14.9 (SD 6.9)	17.0 (SD 4.9)
AITL	18.6 (SD 4.9)	9.2 (SD 9.7)	12.4 (SD 3.9)
MCL	20.6 (SD 10.1)	12.7 (SD 7.4)	18.6 (SD 7.4)

Table 8: Co-expression on FDC. All values as % co-expressing FDC area. GC = germinal center, DZ = dark zone, FL = follicular lymphoma, AITL = angioimmunoblastic T cell lymphoma, MCL = mantle cell lymphoma, SD = standard deviation.

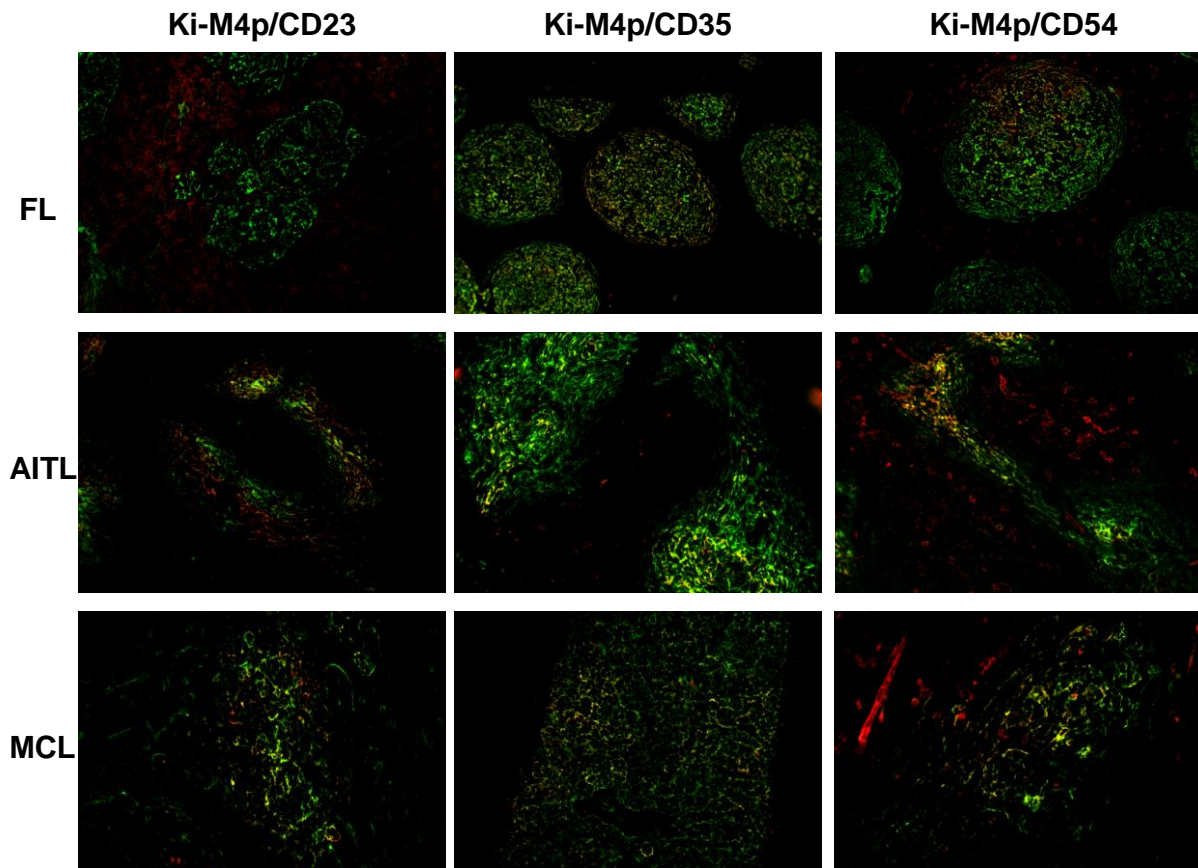


Figure 6: Representative examples of fluorescence double staining using the pan-FDC marker Ki-M4p (green) and co-expression (yellow) of CD23 (red), CD35 (red) and CD54 (red) in representative examples of follicular lymphoma (FL), angioimmunoblastic T cell lymphoma (AITL) and mantle cell lymphoma (MCL).

3.2 Clinical results

Aim 3: Correlation between the extent of FDC networks and clinical outcome in follicular lymphoma

Follicular lymphoma, the second most common subtype of NHL after diffuse large B cell lymphoma, is an indolent lymphoma characterized by long median overall survival, even without therapy, and rare spontaneous remissions. However, a considerable number of patients die within the first two years after the onset of the disease (Álvarez et al., 2006; Klapper et al., 2007). In the current work, we quantified the extent of FDC networks in the malignant follicles of primary biopsies obtained from patients with advanced stage FL recruited for the prospective randomized trial “CHOP versus MCP” of the German Low-Grade Lymphoma Study Group (GLSG) before any treatment has begun. We detected the FDC networks using single staining for the pan-FDC marker Ki-M4p or CD23. The area detected by the staining varied throughout the cohort examined for Ki-M4p (median 7.33 square pixels, minimum 2.52, maximum 24.48, n = 102) and CD23 (median 10.86 square pixels, minimum 2.70, maximum 51.50, n = 81). The prognostic impact of numerical parameters was assessed by univariate and adjusted Cox regression. However, there was no association between the extent of the FDC network measured by Ki-M4p or CD23 with clinical outcome, as measured by time-to-treatment failure (TTF) and overall survival (OS) (univariate and adjusted Cox regression, data shown in Table 9).

(A)

Univariate Cox Regression

Variable	total	Hazard ratio	hrlowercl	hruppercl	probchisq
KiM4p	100	0.7	0.4	1.3	0.26
CD23	79	0.8	0.6	1.1	0.13

Adjusted Cox Regression

Parameter	variable	Hazard ratio	hrlowercl	hruppercl	Probchisq
KiM4p		1.0	0.9	1.0	0.33
	Age	1.0	1.0	1.0	0.58
	Lnreg	1.1	1.0	1.2	0.13
	ecogrisk	1.3	0.4	4.9	0.66
	Hb	1.0	1.0	1.0	0.07
	LDH	1.4	0.8	2.4	0.18
CD23		0.8	0.6	1.0	0.09
	Age	1.0	1.0	1.0	0.59
	Lnreg	1.1	1.0	1.2	0.07
	ecogrisk	0.9	0.2	5.4	0.95
	Hb	1.0	1.0	1.0	0.04
	LDH	1.5	0.8	2.8	0.17

(B)

Univariate Cox Regression

Variable	Total	Hazard ratio	hrlowercl	hruppercl	Probchisq
KiM4p	102	1.0	0.9	1.1	0.80
CD23	81	1.0	0.6	1.7	0.97

Adjusted Cox Regression

parameter	variable	Hazard ratio	hrlowercl	hruppercl	probchisq
KiM4p		1.0	0.9	1.1	0.94
	age	1.0	0.9	1.0	0.50
	Inreg	0.9	0.8	1.1	0.40
	ecogrisk	3.1	0.6	17.2	0.20
	Hb	1.0	0.9	1.0	0.17
	LDH	2.2	1.1	4.5	0.02
CD23		1.0	0.6	1.7	0.99
	Age	1.0	0.9	1.0	0.69
	Lnreg	0.9	0.7	1.1	0.23

ecogrisk	3.6	0.6	20.1	0.15
Hb	1.0	0.9	1.0	0.16
LDH	2.0	1.0	4.2	0.06

Table 9: Prognostic relevance of the extent of FDC networks in malignant follicles of follicular lymphoma. There was no association between the extent of the FDC networks measured by Ki-M4p or CD23 with clinical outcome, as measured by time-to-treatment failure (TTF) (A) and overall survival (OS) (B) estimated by univariate and adjusted Cox regression model.

Abbreviations: hrlowercl = hazard ratio lower confidence limit, hruppercl = hazard ratio upper confidence limit, probchisq = probability of chi squared distribution, lnreg = lymph node region, ecogrisk = Eastern Cooperative Oncology Group risk/performance status, Hb = hemoglobin, LDH = lactate dehydrogenase.

4 Discussion

FDC and their function

Germinal centers are the main sites where high affinity antibody secreting plasma cells and memory B cells generate from. It is organized into two major zones, the dark and light zone (Allen, Cyster, 2007a). The dark zones contain large centroblasts that rapidly proliferate and undergo somatic mutation of their antibody variable region genes. Whereas in the light zones small centrocytes compete for binding antigen on follicular dendritic cells and receive signals from helper T cells to survive and differentiate (Allen, Cyster, 2007a).

FDC represent a unique population of non-lymphoid accessory cells localized within the germinal centers of primary and secondary lymphoid follicles under reactive conditions (Allen, Cyster, 2008; Maeda et al., 2002; Park, Choi, 2005). They form a cellular network with long dendritic extension between GC B cells, trap and present antigens in form of immune complexes and interact with B cells with a variety of molecules involved in the proliferation, differentiation and survival of B cells (Allen, Cyster, 2008; El Shikh et al., 2006; Kasajima-Akatsuka, Maeda, 2006; Maeda et al., 2002; Park, Choi, 2005). The adhesion molecules such as CD44, CD54 and CD166 enhance B cell adherence to FDC, Fc binding receptors (CD23, CD32) and complement receptors (CD21, CD35) present immune complexes to B cells (Allen, Cyster, 2008; Park, Choi, 2005). In addition to that, FDC express 8D6 and membrane-bound IL-15 which stimulate B cell proliferation and transmit anti-apoptotic signals to proliferating B cells via BAFF/BLys and Notch ligands DII1 and Jg6 (Hase et al., 2004; Park et al., 2004; Park, Choi, 2005; Yoon et al., 2009). In accordance with the function of GC, which consists of a dark zone where densely

packed centroblasts rapidly proliferate and a light zone comprised of non-proliferating centrocytes that either differentiate or undergo apoptosis, FDC also show a differentiated distribution pattern and immunophenotype within the GC (Freedman et al., 1995; Li, Choi, 2002). The FDC in the light zone are predominantly involved in immune complex presentation and selection of B cells that produce high-affinity immunoglobulin directed against the antigen presented by the FDC. Thus, FDC are present at a much higher density in the light zone than in the dark zone and the light zone FDC strongly express molecules involved in immune complex display such as Fc fragment-binding proteins (CD23 and CD32) and complement receptors (CD21 and CD35) (Freedman et al., 1995; Yoshida et al., 1993). FDC in the dark zone is sparse and their function is less clearly defined, however the reduced expression of CD23 and CD21 on FDC in the dark zone indicate that immune complex presentation and B cell selection is not the predominant function of the FDC in the dark zone, suggesting functional and phenotypical heterogeneity of FDC within GC (Yoshida et al., 1993). Instead, FDC in the dark zone might provide anti-apoptotic and growth factors creating an ideal microenvironment for the rapidly dividing centroblasts supporting both their proliferation and survival (Choe et al., 2000; Park, Choi, 2005). GC development, the site of memory B cells and initial plasma cell differentiation in the secondary antibody response, depend on FDC networks and their immune complex display. Because of their close association and interaction with B cells, FDC are key players in the initiation and maintenance of anamnestic antibody responses and the alteration of their function may contribute to deficits or deficiency in the immune responses and development of immune system related-diseases e.g. lymphoma, acquired immune-deficiency syndrome (AIDS), transmissible spongiform encephalitis (TSE) and autoimmune diseases such as rheumatoid arthritis (Li, Choi, 2002; Gribben, 2010; Kosco-Vilbois, 2002; Park, Choi, 2005). Even though FDC

frequently feature in the microenvironment of several non-Hodgkin lymphomas, the follicular dendritic cell sarcoma is curiously a rare disease with a neoplastic proliferation of cells showing morphologic and immunophenotypic features of FDC outside of the lymphoid follicles (Swerdlow et al., 2008).

FDC in aging

It is a well known phenomenon that the specific antibody response decline in aging. Because of the crucial role FDC play in the formation of GC, selection and differentiation of memory B cells and maintenance of secondary antibody response, one might speculate that this phenomenon is also associated with age-related changes in FDC networks such as reduced immune complex (IC) presentation. However, Aydar et al. has shown that old FDC express near normal levels of Fc binding proteins and complement receptors, indicating that the lack of IC presentation is not likely attributable to the lack of Fc and complement receptors, but, at least in part, to the reduced transport of IC to the FDC reticulum by antigen-presenting cells and the reduced ability of old FDC to protect the retained antigen from macrophages in comparison with young FDC (Aydar et al., 2002; Szakal et al., 1990, 1992). Furthermore, aged FDC produce fewer iccosomes (immune complex-coated bodies) for delivery of antigen to B cells for endocytosis, antigen processing and presentation to T cells. Moreover, the number of FDC reticula is reduced and the GC size and numbers are decreased (Szakal et al., 1990, 1992, 2002). Thus, senescence leads to the appearance of atrophic FDC that trap and retain little immune complexes, generate few iccosomes and memory B cells and induce a reduced number of GC (Aydar et al., 2002). The age-related depression of FDC functions results in the paucity of GC in aged individuals characterized by a progressive decline in responsiveness to exogenous antigen that may contribute to an increased morbidity

and mortality in the elderly (Aydar et al., 2002; Szakal et al., 1990; Szakal et al., 1992). The methods developed within this project might be useful to address the question of ageing phenotypes of FDC, too.

Methods for FDC detection and characterization

Although the detection of FDC by immunohistochemical methods is a standard procedure in diagnostic hematopathology, FDC remain a challenging cell type due to their morphology and phenotypical heterogeneity inside GC. Since FDC are large cells with long dendritic extensions and hardly detectable cell bodies, the quantification of the extent of FDC networks or the immunophenotype of FDC using conventional staining and light microscopy is highly observer-dependent. Furthermore, because of their different immunophenotype in the dark and light zone of GC, not every monoclonal antibody is reactive for FDC in the entire GC. Gene expression profiling studies, which have demonstrated that the expression of genes derived from non-lymphoma bystander cells such as dendritic cells might be prognostically relevant, is unfortunately not applicable to formalin-fixed, paraffin-embedded (FFPE) tissue, the medium of choice for most clinical and research due to their superior preservation of morphology (Dave et al., 2004; Key, 2006). However, quantification of follicular dendritic cells and their protein expression in FFPE tissues might not only be important for understanding and classifying malignant lymphomas, but also for examining their possible role as prognostic marker and a target for immune modulation as well as treatment of B cell tumors of GC origin. Thus, we established a method for semiquantitative assessment of the extent of FDC networks and of protein expression in FDC employing multicolor immunofluorescence staining followed by digital image analysis to detect FDC with its dendritic extensions. We applied Ki-M4p, a mouse monoclonal antibody detecting FDC network through the

whole of the lymphoid follicle, as pan-FDC marker (Maeda et al, 2002; Parwaresch et al., 1983) and antibodies detecting representative functional groups of FDC such as Fc fragment-binding proteins (CD23), complement receptors (CD35) and adhesion molecules (CD54). In all analyses, the area detected by the marker Ki-M4p was larger than the area staining for CD23, CD35 or CD54, indicating that Ki-M4p is useful as a pan-FDC marker (Parwaresch et al., 1983). And our method reproduced the findings from the published literature with regard to the expression of CD23, CD35 and CD43 in the normal GC which showed reduced expression in the dark zone (Bagdi et al., 2001; Chang et al., 2003; Yoshida et al., 1993).

Unfortunately, we were unable to establish reliable staining protocols for other important FDC functional groups, BAFF/BLys, Notch ligands and IL-15, membrane-bound molecules involved in transmitting anti-apoptotic and pro-proliferative signals to B cells (Park et al., 2004; Park, Choi, 2005, Yoon et al., 2009). Since the published literature on BAFF expression by FDC show unexpected nuclear, instead of membrane, staining patterns, we assume that reliable BAFF antibodies for FFPE tissues are currently not available (Hase et al., 2004). Because of their involvement in mediating the survival and proliferation of GC B cells, possibly also of malignant B cells in NHL, future studies will have to focus on evaluating the quantitative expression of these proteins on FDC in reactive and neoplastic lymphoid follicles and examine whether the functions mediated by them are altered in the FDC found in NHL.

FDC in lymphoma and their possible role in lymphomagenesis

The preferential localization of lymphoma cells in the GC, a dynamic microenvironment where antigen-activated B cells expand and undergo events associated with antibody maturation, suggests a unique relationship between B cells

and their microenvironment (Allen, Cyster, 2008; Küppers et al., 1999; Park, Choi, 2005). Recent study has shown that the interactions between FDC and GC B cells rescue the selected B cell clones from apoptosis (Park, Choi, 2005; Thompson et al., 2000). Further differentiation of selected B cells toward either plasma cells or memory B cells is also dependent on FDC (Allen, Cyster, 2008; El Shikh et al., 2006; Park, Choi, 2005). Because of the intimate relationship between FDC and B cells, FDC is expected to affect B cells and even play a role in pathogenesis of neoplastic lymphoproliferations in yet uncertain way (Bagdi et al., 2001). In certain B cell non-Hodgkin lymphomas (NHL) FDC can be detected among the reactive bystander cells of the tumor (Bagdi et al., 2001). Whereas in marginal zone lymphomas the FDC are considered to represent remnants of GC that have been colonized by lymphoma cells, it has been suggested that FDC in mantle cell lymphoma (MCL), follicular lymphoma (FL) and angioimmunoblastic T cell lymphoma (AITL) are newly generated and have proliferated during lymphoma growth and expansion (Swerdlow et al., 2008). Structural alteration in the network of FDC such as atypical shape or expansion are also frequently found in malignant lymphoma and can be useful adjunct in the diagnostic immunophenotyping of the malignant lymphomas (Bagdi et al., 2001). In FL the abnormal follicles demonstrate dense, sharply defined and expanded FDC networks reminiscent of those seen in the normal germinal centers. They are exclusively found within malignant follicles and absent in the interfollicular lymphoma compartment as well as in diffusely growing FL (Bagdi et al., 2001; Klapper et al., 2007). In MCL loosely arranged, weakly developed FDC network in nodular or diffuse patterns are observed (Bagdi et al., 2001, Schrader et al., 2006). And the most common morphological subtype of AITL (pattern 3) shows a prominent diffuse proliferation of FDC network with frequent incorporation of proliferating postcapillary venules, an important hallmark of the disease since this pattern has not been found

in any other T cell lymphomas hence facilitating the differential diagnosis (Attygalle et al., 2002; Bagdi et al., 2001).

The immunophenotype of FDC in reactive and neoplastic lymphoid tissues has been characterized, and reduced expression of markers of mature FDC was noted in FL and MCL (Bagdi et al., 2001; Chang et al., 2003). In our study, we were able to demonstrate that the expression of all functional markers examined, namely CD23, CD35 and CD54, was also reduced in the FDC found in FL, AITL and MCL, resembling the FDC of GC dark zone. This suggests that FDC in FL, AITL and MCL are not primarily involved in immune complex presentation and selection of B cells like the FDC of GC light zone, but their function could take after the function of dark zone FDC and provide stimulating factors for B cell proliferation and survival. Tsunoda et al. have suggested that FDC networks in FL of grade 1 and 2 may be similar to those in the GC light zone and FDC networks in FL of grade 3 to those in the dark zone, based on the expression profile of calcium binding proteins, S100 and caldesmon (Tsunoda et al., 1999). Our finding, the similar immunophenotype of the dark zone FDC in comparison with those in FL, AITL and MCL, is in contrast to this earlier report and indicates a closer relation between the FDC in NHL and the dark zone FDC in morphology and function.

FDC as prognostic marker in non-Hodgkin lymphomas

The microenvironment is the compilation of accessory cells that work as a team through cell-cell contacts and active molecular crosstalk to provide a functional scaffolding to parenchymal cells. It can be instrumental to the survival and propagation of malignant cells by producing growth factors, inducing new vessel formation for nutrients and immune tolerance to avoid immune-mediated elimination (Burger et al., 2009). GC with its special microenvironmental organization comprised

of a variety of cell populations, including T cell subsets, macrophages and FDC, linked by topographical and functional relationships, is not only the main source of immunity against invading microorganisms, but also the main origin of B cell lymphomas (Klein, Dalla-Favera, 2008; Küppers et al., 1999). Several gene expression profiling studies and immunohistochemical analyses in lymphoma biopsy samples have confirmed that the biological behavior and tumor progression may be influenced by the tumor microenvironment (Carbone et al., 2009; Dave et al., 2004; Glas et al., 2007). Recently, Dave et al. have revealed that the expression of FDC-related genes is associated with the clinical course in follicular lymphoma (Dave et al., 2004). Another study has shown that the growth pattern and distribution of FDC in mantle cell lymphoma are associated with the clinical outcome (Schrader et al., 2006). Goven et al. have demonstrated that FDC are able to avoid the spontaneous apoptosis of FL malignant B cells preventing the activation of different caspases (Goval et al., 2008). All of these findings highlight the role of FDC as accessory cells in tumor microenvironment and their influence on malignant cells.

Follicular lymphoma, the second most frequent NHL in adults worldwide, is an indolent lymphoma with a median survival of approximately 10 years following diagnosis. However, the clinical course of FL patients is very heterogeneous; some patients have an aggressive illness that is fatal in less than one year while others may live more than 20 years (Álvaro et al., 2006; Klapper et al., 2007; Staudt, Dave, 2005). Thus, the identification of prognostic marker would provide useful information for deciding on treatment strategies in individual FL patients. In the current work, we quantified the extent of FDC networks in the malignant follicles of FL and correlated it to the clinical outcome. Although our technique allows an accurate quantification of the extent of FDC networks within malignant follicles of FL, we were unable to demonstrate an association between the extent of FDC networks and prognosis.

However, a simple comparison and cross validation of this research finding with the results from gene expression profiling studies are limited since gene expression profiling reflects complex biological processes involving multiple cell types whereas our immunohistochemical stainings detect one cell type, namely FDC, only (Dave et al., 2004; Staudt, Dave, 2005). Moreover, interactions of T cells with FDC might influence the expression of FDC protein, CD23 and thus, also the result of gene expression signature (Sukumar et al., 2006). Furthermore, it should be noted that the patient selection and end points are essentially different between study groups, precluding strong conclusions based on such comparisons (Dave et al., 2004; Glas et al., 2007). Finally, we have not assessed the shape of FDC networks and expression levels of other important functional groups such as CD35 and CD54 which might also be of prognostic relevance (Glas et al., 2007).

The dependence of the malignant cells on external signals from the microenvironment, such as antigens, cytokines and cell-cell interactions, is indisputable even though the precise nature of the relevant cell populations and the molecular mechanisms involved in lymphoma progression have not yet been clearly defined (Dave et al., 2004; Gribben, 2010). The question whether the specific lymphoma microenvironment develops by infiltration of accessory cells from outside or differentiation of the accessory cells *in loco* e.g. by stimuli provided by malignant cells remain to be solved. Published data on the prognostic significance of cell populations, including T cell subsets, macrophages and FDC have produced conflicting results. Some of this can be explained by the impact of previous treatment on different population of cells within the microenvironment (de Jong et al., 2009; Gribben, 2010). In conclusion, the microenvironment plays a crucial role in influencing the clinical behavior of malignant B cells and therefore, the development and progression of NHL (Burger et al., 2009). It will be a challenge over the coming

years to uncover the complex biological processes in the tumor microenvironment. Despite the difficulties, future studies using quantitative *in situ* methods such as the one presented here will help us to understand which types of reactive bystander cells might be of use as a clinical applicable prognosticator and to develop intelligent treatment strategies targeted to specific biologic mechanisms responsible for the disease progression such as FL.

5 Summary

Follicular dendritic cells represent a unique population of specialized antigen-presenting cells found in the primary and secondary lymphoid follicles under reactive conditions and in certain non-Hodgkin lymphomas among the reactive bystander cells of tumor (Allen, Cyster, 2008; Park, Choi, 2005). Follicular dendritic cells form a three-dimensional network to sustain the architecture of germinal center and play a pivotal role in the selection of antigen-specific B cells and their clonal expansion in the germinal center (Allen, Cyster, 2008; Park, Choi, 2005).

Recently, several gene expression profiling studies and immunohistochemical analyses in lymphoma biopsy samples have revealed that follicular dendritic cell networks might be associated with the clinical outcome in certain non-Hodgkin lymphomas (Carbone et al., 2009; Dave et al., 2004; Glas et al., 2007). We therefore determined semiquantitatively the extent and the immunophenotype of follicular dendritic cells in both reactive germinal centers and non-Hodgkin lymphomas, namely follicular lymphoma, angioimmunoblastic T cell lymphoma and mantle cell lymphoma, using fluorescent double staining followed by digital image analysis.

In all tested non-Hodgkin lymphomas, proteins that are involved in the antigen-dependent interaction of follicular dendritic cells and B cells, such as CD23 and CD35, and in adhesion, such as CD54, were expressed at relatively low levels on follicular dendritic cells, comparable to follicular dendritic cells found in the dark zone of the germinal center, suggesting functional and phenotypical heterogeneity of follicular dendritic cells in germinal centers and non-Hodgkin lymphomas. However, there was no association between the extent of follicular dendritic cell networks with the clinical outcome of 102 patients with follicular lymphoma treated within a

prospectively randomized trial as measured by time to treatment failure or overall survival.

In summary, follicular dendritic cells found in different types of non-Hodgkin lymphomas show quantitatively reduced expression of several proteins, suggesting that there are functional differences between follicular dendritic cells in normal germinal centers and non-Hodgkin lymphomas. The extent of the follicular dendritic cell networks in follicular lymphoma, however, is not useful as a prognostic marker.

6 Appendix

Legends of figures and tables

Figure 1: Interaction between FDC and GC B cell. FDC interact with GC B cells via several mechanisms including adhesion molecules such as ICAM-1 and VCAM-1, B cell anti-apoptotic TNF superfamily ligand BAFF, Fc binding proteins such as CD23 and complement receptors such as CD 21 for immune complex presentation and 8D6 and membrane-bound interleukin (IL)-15 for B cell proliferation.

Figure 2: Representative examples of fluorescent double staining using the pan-FDC marker Ki-M4p (A, single staining), CD23 (B, single staining), Ki-M4p and CD23 (C, double staining) and quantitative image analysis “Phase analysis” (D) with software analySIS™ to assess the extent of co-expression.

Figure 3: Representative example of fluorescence double staining using the pan-FDC marker Ki-M4p (green) and CD23 (red) in a reactive germinal center (GC). In the light zone (LZ), FDC are present in a much higher density than in the dark zone (DZ).

Figure 4: Quantitative analysis of co-expression of CD23, CD35 and CD54 on follicular dendritic cells (FDC) in the entire germinal center (total GC) or the dark zone (DZ) in tonsils. The FDC in the dark zone (DZ) of the GC display a reduced expression of the Fc-receptor (CD23), complement receptor 1 (CD35) and adhesion molecule ICAM-1 (CD54), compared to the FDC in the whole follicle (total GC), which is dominated by the light zone FDC. *P*-values were obtained using t-tests. Horizontal bars indicate the mean.

Figure 5: Quantitative analysis of co-expression of CD23 (A), CD35 (B) and CD54 (C) on FDC in the entire germinal center (total GC), follicular lymphoma (FL),

angioblastic T-cell lymphoma (AITL) and mantle cell lymphoma (MCL). FDC in FL, AITL and MCL display quantitatively reduced expression of CD23, CD35 and CD54 compared to the FDC in the whole GC. The levels of CD35 and CD54 co-expression in the lymphomas are comparable with the FDC in the dark zone of the GC (*P*-values not significant using a t-test, data shown in Table 8). *P*-values were obtained using t-tests. Horizontal bars indicate the mean.

Figure 6: Representative examples of fluorescence double staining using the pan-FDC marker Ki-M4p (green) and co-expression (yellow) of CD23 (red), CD35 (red) and CD54 (red) in representative examples of follicular lymphoma (FL), angioimmunoblastic T cell lymphoma (AITL) and mantle cell lymphoma (MCL).

Table 1: Clinical baseline characteristics of the population studied in this report (n = 137) compared with all patients with advanced stage follicular lymphoma registered in the trial (n = 538).

Table 2: Antibodies and their sources

Table 3: Buffers, solutions and fabrication formula

Table 4: Chemicals and their sources

Table 5: Utensils and their sources

Table 6: Software and their sources

Table 7: Co-expression on FDC. All values as % co-expressing FDC area. GC = germinal center, DZ = dark zone, SD = standard deviation.

Table 8: Co-expression on FDC. All values as % co-expressing FDC area. GC = germinal center, DZ = dark zone, FL = follicular lymphoma, AITL = angioimmunoblastic T cell lymphoma, MCL = mantle cell lymphoma, SD = standard deviation.

Table 9: Prognostic relevance of the extent of FDC networks in malignant follicles of

follicular lymphoma. There was no association between the extent of the FDC networks measured by Ki-M4p or CD23 with clinical outcome, as measured by time-to-treatment failure (TTF) (A) and overall survival (OS) (B) estimated by univariate and adjusted Cox regression model.

7 References

Allen CD, Okada T, Cyster JG: Germinal-center organization and cellular dynamics. *Immunity* 2007a; 27: 190-202.

Allen CD, Okada T, Tang HL, Cyster JG: Imaging of germinal center selection events during affinity maturation. *Science* 2007b; 315: 528-531.

Allen CD, Cyster JG: Follicular dendritic cell networks of primary follicles and germinal centers: phenotype and function. *Semin Immunol* 2008; 20: 14-25.

Álvarez T, Lejuene M, Salvadó MT, Lopez C, Jaén J, Bosch R, Pons LE: Immunohistochemical patterns of reactive microenvironment are associated with clinicobiologic behavior in follicular lymphoma patients. *J Clin Oncol* 2006; 24: 5350-5357.

Attygalle A, Al-Jehani R, Diss TC, Munson P, Liu H, Du MQ, Isaacson PG, Dogan A: Neoplastic T cells in angioimmunoblastic T-cell lymphoma express CD10. *Blood* 2002; 99: 627-633.

Aydar Y, Balogh P, Tew JG, Szakal AK: Age-related depression of FDC accessory functions and CD21 ligand-mediated repair of co-stimulation. *EJ Immunol* 2002; 32: 2817-2826.

Bagdi E, Krenacs L, Krenacs T, Miller K, Isaacson PG: Follicular dendritic cells in reactive and neoplastic lymphoid tissues: a reevaluation of staining patterns of CD21, CD23, and CD35 antibodies in paraffin sections after wet heat-induced epitope retrieval. *Appl Immunohistochem Mol Morphol* 2001; 9: 117-124.

- Burger** JA, Ghia P, Rosenwald A, Caligaris-Cappio F: The microenvironment in mature B-cell malignancies: a target for new treatment strategies. *Blood* 2009; 114: 3367-3375.
- Carbone** A, Gloghini A, Cabras A, Elia G: The germinal center-derived lymphomas seen through their cellular microenvironment. *Br J Haematol* 2009; 145: 468-480.
- Chang** KC, Huang X, Medeiros LJ, Jones D: Germinal center-like versus undifferentiated stromal immunophenotypes in follicular lymphoma. *J Pathol* 2003; 201: 404-412.
- Choe** J, Li L, Zhang X, Gregory CD, Choi YS: Distinct role of follicular dendritic cells and T cells in the proliferation, differentiation and apoptosis of a centroblast cell line, L3055. *J Immunol* 2000; 164: 56-63.
- Dave** SS, Wright G, Tan B, Rosenwald A, Gascoyne RD, Chan WC, Fisher RI, Braziel RM, Rimsza LM, Grogan TM, Miller TP, LeBlanc M, Greiner TC, Weisenburger DD, Lynch JC, Vose J, Armitage JO, Smeland EB, Kvaloy S, Holte H, Delabie J, Connors JM, Lansdorp PM, Ouyang Q, Lister TA, Davies AJ, Norton AJ, Muller-Hermelink HK, Ott G, Campo E, Montserrat E, Wilson WH, Jaffe ES, Simon R, Yang L, Powell J, Zhao H, Goldschmidt N, Chiorazzi M, Staudt LM: Prediction of survival in follicular lymphoma based on molecular features of tumor-infiltrating immune cells. *N Engl J Med* 2004; 351: 2159-2169.
- De Jong** D, Koster A, Hagenbeek A, Raemaekers J, Veldhuizen D, Heisterkamp S, de Boer JP, van Glabbeke M: Impact of the tumor microenvironment on prognosis in follicular lymphoma is dependent on specific treatment protocols.

Haematologica 2009; 94: 70-77.

El Shikh ME, El Sayed R, Szakal AK, Tew JG: Follicular dendritic cell (FDC) FcγRIIB engagement via immune complexes induces the activated FDC phenotype associated with secondary follicle development. *Eur J Immunol* 2006; 36: 2715-2724.

Freedman AS, Wang J, Phifer S, Manie SN: Role of follicular dendritic cells in the regulation of B cell proliferation. *Curr Top Microbiol Immunol* 1995; 201: 83-92.

Glas A, Knoops L, Delahaye L, Kersten MJ, Kibbelaar RE, Wessels LA, van Laar R, van Krieken JH, Baars JW, Raemaekers J, Kluin PM, van't Veer LJ, de Jong D: Gene-expression and immunohistochemical study of specific T-cell subsets and accessory cell types in the transformation and prognosis of follicular lymphoma. *J Clin Oncol* 2007; 25: 390-398.

Goval JJ, Thielen C, Bourguignon C, Greimers R, Dejardin E, Choi YS, Boniver J, de Leval L: The prevention of spontaneous apoptosis of follicular lymphoma B cells by a follicular dendritic cell line: involvement of caspase-3, caspase-8 and c-FLIP. *Haematologica* 2008; 93: 1169-1177.

Gribben JG: Implications of the tumor microenvironment on survival and disease response in follicular lymphoma. *Curr Opin Oncol* 2010; 22: 424-430.

Hase H, Kanno Y, Kojima M, Hasegawa K, Sakurai D, Kojima H, Tsuchiya N, Tokunaga K, Masawa N, Azuma M, Okumura K, Kobata T: BAFF/BLyS can potentiate B-cell selection with the B-cell coreceptor complex. *Blood* 2004; 103: 2257-2265.

Kasajima-Akatsuka N, Maeda K: Development, maturation and subsequent

activation of follicular dendritic cells (FDC): immunohistochemical observation of human fetal and adult lymph nodes. *Histochem Cell Biol* 2006; 126: 261-273.

Key M: *Immunohistochemical staining methods, fourth edition*. Carpinteria: Dako, 2008.

Klapper W, Hoster E, Rölver L, Schrader C, Janssen D, Tiemann M, Bernd HW, Determann O, Hansmann ML, Möller P, Feller A, Stein H, Wacker HH, Dreyling M, Unterhalt M, Hiddemann W, Ott G: Tumor sclerosis but not cell proliferation or malignancy grade is a prognostic marker in advanced-stage follicular lymphoma: the German Low Grade Lymphoma Study Group. *J Clin Oncol* 2007; 25: 3330-3336.

Klein U, Dalla-Favera R: Germinal centers: role in B-cell physiology and malignancy. *Nat Rev Immunol* 2008; 8: 22-33.

Kosco-Vilbois MH: Introduction: FDC in health and disease. *Semin Immunol* 2002; 14: 249.

Küppers R, Klein U, Hansmann M-L, Rajewsky K: Cellular origin of human B-cell lymphomas. *N Engl J Med* 1999; 341: 1520-1529.

Lennert K, Feller A: *Histopathologie der Non-Hodgkin-Lymphome*. Berlin: Springer-Verlag, 1981.

Li L, Choi YS: Follicular dendritic cell-signaling molecules required for proliferation and differentiation of GC-B cells. *Semin Immunol* 2002; 14: 259-266.

Maeda K, Matsuda M, Suzuki H, Saitoh HA: Immunohistochemical recognition of human follicular dendritic cells (FDCs) in routinely processed paraffin sections. *J*

Histochem Cytochem 2002; 50: 1475-1486.

Nickenig C, Dreyling M, Hoster E, Pfreundschuh M, Trumper L, Reiser M, Wandt H, Lengfelder E, Unterhalt M, Hiddemann W: Combined cyclophosphamide, vincristine, doxorubicin, and prednisone (CHOP) improves response rates but not survival and has lower hematologic toxicity compared with combined mitoxantrone, chlorambucil, and prednisone (MCP) in follicular and mantle cell lymphomas: results of a prospective randomized trial of the German Low-Grade Lymphoma Study Group. *Cancer* 2006; 107: 1014-1022.

Park CS, Choi YS: How do follicular dendritic cells interact intimately with B cells in the germinal center? *Immunology* 2005; 114: 2-10.

Park CS, Yoon SO, Armitage R, Choi YS: Follicular dendritic cells produce IL-15 that enhances germinal center B cell proliferation in membrane-bound form. *J Immunol* 2004; 173: 6676-6683.

Parwaresch MR, Radzun HJ, Hansmann ML, Peters KP: Monoclonal antibody Ki-M4 specifically recognizes human dendritic reticulum cells (follicular dendritic cells) and their possible precursor in blood. *Blood* 1983; 62: 585-590.

Rademakers LH: Dark and light zones of germinal centers of the human tonsil: an ultrastructural study with emphasis on heterogeneity of follicular dendritic cells. *Cell Tissue Res* 1992; 269: 359-368.

Schiemann B, Gommerman JL, Vora K, Cachero TG, Shulga-Morskaya S, Dobles M, Frew E, Scott ML: An essential role for BAFF in the normal development of B cells through a BCMA-independent pathway. *Science* 2001; 293: 2111-2114.

Schrader C, Meusers P, Brittinger G, Janssen D, Teymoortash A, Siebmann JU,

- Parwaresch R, Tiemann M: Growth pattern and distribution of follicular dendritic cells in mantle cell lymphoma: a clinicopathological study of 96 patients. *Virchows Arch* 2006; 448: 151-159.
- Schwickert** TA, Lindquist RL, Shakhar G, Livshits G, Skokos D, Kosco-Vilbois MH, Dustin ML, Nussenzweig MC: In vivo imaging of germinal centers reveals a dynamic open structure. *Nature* 2007; 446: 83-87.
- Soft Imaging System GmbH**: *User's guide analySIS®*. Münster: Soft Imaging System GmbH, 2002.
- Staudt** LM, Dave S: The biology of human lymphoid malignancies revealed by gene expression profiling. *Adv Immunol* 2005; 87: 163-208.
- Sukumar** S, Conrad DH, Szakal AK, Tew JG: Differential T cell-mediated regulation of CD23 (Fc epsilonRII) in B cells and follicular dendritic cells. *J Immunol* 2006; 176: 4811-4817.
- Swerdlow** SH, Campo E, Harris NL, Jaffe ES, Pileri SA, Stein H, Thiele J, Vardiman JW: *WHO classification of tumors of the haematopoietic and lymphoid tissues*. Lyon: IARC, 2008.
- Szakal** AK, Taylor JK, Smith JP, Kosco MH, Burton GF, Tew JJ: Kinetics of germinal center development in lymph nodes of young and aging immune mice. *Anat Rec*. 1990; 227: 475-485.
- Szakal** AK, Kapasi ZF, Masuda A, Tew JG: Follicular dendritic cells in the alternative antigen transport pathway: microenvironment, cellular events, age and retrovirus related alterations. *Semin Immunol*. 1992; 4: 257-265.

Szakai AK, Aydar Y, Balogh P, Tew JG: Molecular interactions of FDCs with B cells in aging. *Semin Immunol.* 2002; 14: 267-274.

Thompson JS, Schneider P, Kalled SL, Wang L, Lefevre EA, Cachero TG, MacKay F, Bixler SA, Zafari M, Liu ZY, Woodcock SA, Qian F, Batten M, Madry C, Richard Y, Benjamin CD, Browning JL, Tsapis A, Tschopp J, Ambrose C: BAFF binds to the tumor necrosis factor receptor-like molecule B cell maturation antigen and is important for maintaining the peripheral B cell population. *J Exp Med.* 2000; 192: 129-135.

Tsunoda T, Yamakawa M, Takahashi T: Differential expression of Ca(2+)-binding proteins on follicular dendritic cells in non-neoplastic and neoplastic lymphoid follicles. *Am J Pathol* 1999; 155: 805-814.

Yoon SO, Zhang X, Berner P, Blom B, Choi YS: Notch ligands expressed by follicular dendritic cells protect germinal center B cells from apoptosis. *J Immunol* 2009; 183: 352-358.

Yoshida K, van den Berg TK, Dijkstra CD: Two functionally different follicular dendritic cells in secondary lymphoid follicles of mouse spleen, as revealed by CR1/2 and FcR gamma II-mediated immune-complex trapping. *Immunology* 1993; 80: 34-39.

Acknowledgements

It is a pleasure to thank those who made this dissertation possible.

First of all, I would like to thank our heavenly Father for giving me wisdom and strength and my dear family and Christian for their constant trust and love.

I owe my deepest gratitude to Prof. Dr. med. Klapper, whose encouragement, guidance and support from the initial to the final level enabled me to develop an understanding of the subject. He was the best and challenging mentor one could ever wish for.

This dissertation would not have been possible without Monika Hauberg, Charlotte Botz von Drathen and Michael Weiß and their patient technical instruction and support.

I would like thank Eva Hoster for her excellent statistical analysis.

Last, but not least, I would like to show my gratitude to my best friend and colleague, Karoline Koch, for her support in a number of ways and pleasant companionship.

Curriculum vitae

Personal Details

Date of Birth 26 May 1984

Nationality German

Gender Female

Education

Nov 2007 – present Dissertation

Oct 2003 – Dec 2009 Christian-Albrechts-University, Kiel, Germany
Study of Medicine

1997 – 1999, 2000 – 2003 Hans-Geiger-Gymnasium, Kiel, Germany

Aug 1999 – Jul 2000 Shelby High School, Shelby, USA
Exchange Student Year

1991 – 1997 Nok-Beon Elementary School,
Seoul, Republic of Korea

Employment

Mar 2010 - present Resident physician in IV. Medical Clinic,
University Hospital of Schleswig-Holstein,
Campus Kiel, Germany

Publication

Jin MK, Hoster E, Dreyling M, Unterhalt M, Hiddemann W, Klapper W. Follicular dendritic cells in follicular lymphoma and types of non-Hodgkin lymphoma show reduced expression of CD23, CD35 and CD54 but no association with clinical outcome. *Histopathology* 2011; 58:589-92.