

Department of Neuropediatrics

Director: Professor U. Stephani

In University Clinic Schleswig-Holstein, Campus Kiel

Christian-Albrechts-Universität

**Neuronal networks in West-syndrome as revealed by Source Analysis and Renormalized Partial
Directed Coherence**

Submitted to

Obtain the Doctoral Degree in the

Faculty of Medicine

Christian-Albrechts-Universität, campus Kiel

A Dissertation

By

Natia Japaridze

Kiel 2012

1. Referent: Prof. Dr. Stephani, Klinik für Neuropädiatrie

2. Korreferent: PD. Dr. Lang, Klinik für Neurologie

Tag der mündlichen Prüfung: 26.12.12

gez.: Prof. Dr. Dr. I. Cascorbi

(Vorsitzender der Prüfungskommission)

Contents

1. INTRODUCTION.....	5
1.1 West Syndrome	5
1.1.1 Historical Background	5
1.1.2 Demographic Data	5
1.1.3 Clinical manifestation.....	6
1.1.4 Etiology	7
1.1.5 Pathogenesis.....	9
1.1.6 Electroencephalogram	10
1.1.7 Neuroimaging	11
1.1.8 Management	11
1.1.9 Prognosis.....	12
1.2. Source analyses	12
1.3 Aims of the study.....	13
2. MATERIALS AND METHODS	14
2.1 Subjects	14
2.2 EEG recording.....	18
2.3 Simultaneous EEG-fMRI recordings and data processing	18
2.4 EEG analysis	18
2.4.1 Selection of EEG epochs:	19
2.4.2 Source Analysis	20
2.4.3 Directionality Analysis:.....	22
3. RESULTS.....	23
3.1 Dynamic Imaging of Coherent Sources.....	23
3.1.1 West syndrome group:.....	23
3.1.2 Control group:.....	23
3.2 Renormalized Partial Directed Coherence.....	24
4. DISCUSSION.....	26
4.1 Functional connectivity in hypsarrhythmia.....	26
4.2 Effective connectivity in hypsarrhythmia	27
4.3 Methodological considerations	28
5. CONCLUSION.....	30

6. SUMMARY.....	31
7. APPENDIX.....	32
7.1 Supplementary figures	32
7.2 Supplementary Text	38
8 REFERENCES	38
9. ACKNOWLEDGMENT.....	44
10. CURRICULUM VITAE	46

1. INTRODUCTION

1.1 West Syndrome

West syndrome is a disabling, age-related epileptic encephalopathy which may be attributed to different aetiologies. It is characterised by a unique seizure type - infantile spasms, developmental delay and a pathognomonic EEG pattern of hypsarrhythmia (Dulac, 2001, Hrachovy and Frost, 2003). The hypsarrhythmia is described as a mixture of giant abnormal, arrhythmic and asynchronous brain electrical activity consisting of slow and sharp waves, multi-focal spikes and polyspikes (Commission on Classification and Terminology of the International League Against Epilepsy (1989)). Despite of a poor developmental outcome, treatment difficulties and high association of West syndrome with other severe encephalopathies such as Lennox-Gastaut syndrome, the pathophysiological mechanisms of West syndrome are still poorly clarified. In particular, little is known about neuronal networks underlying hypsarrhythmia.

1.1.1 Historical Background

The English physician Dr. West first described the combination of flexion spasms and psychomotor retardation in his son, who suffered from this condition (West, 1841). In this report Dr West provided information about the mode of onset, the character of the spasms, the phenomenon of spasm clusters, the association with mental and/or motor developmental retardation, and the fact that the disorder is rare (Hrachovy and Frost, 2003). Later Gibbs and Gibbs (1952) recorded and described the unique EEG pattern characteristic for the infantile spasms: hypsarrhythmia (hypsi, from Greek, meaning "high," arrhythmia, from Greek, meaning "lack of rhythm"), which is characterized by random, high-voltage, nonsynchronous spikes and slow wave activity. Over the years the triad of infantile spasms, hypsarrhythmia and retardation became known as West syndrome.

1.1.2 Demographic Data

West syndrome is the most frequent epileptic encephalopathy, a condition in which cognitive, sensory and/or motor functions are altered by epilepsy itself (Dulac, 2005). The incidence ranges from 2.9 to 4.5 per 100,000 live births, with no changes over the last 15 years (Dulac, 2005). Boys (60%) are affected more than girls though reports differ, sometimes giving a 2:1 preponderance of males over

females (Panayiotopoulos, 2005). Although some studies have found no male/female differences, and a few studies have reported an excess of female subjects with this disorder (Hrachovy and Frost, 2003). It has been suggested that the male predominance observed in some studies may simply reflect a larger proportion of male patients in the referral population (Brna et al., 2001).

1.1.3 Clinical manifestation

West syndrome is an age-dependent syndrome, with insidious onset in either an otherwise normal or an already handicapped infant. It begins in infancy, mostly between 4 months and 6 months of life, before the age of 12 months in over 90% of cases (Kellaway et al., 1979). However, the later occurrence, up to 3 years of age, has been emphasized, it is easily overlooked and, therefore, inappropriately treated for many months before the diagnosis is done (Bednarek et al., 1998). Spasms are can be the first manifestation, being isolated at first before they occur typically in clusters. Other types of seizures may precede the spasms by several weeks (Dulac, 2005).

Seizure types

Epileptic (infantile) spasms are the specific and defining type of seizures in West syndrome.

The epileptic spasms are clusters of sudden, brief (0.2–2 s), bilateral, usually symmetrical tonic contractions of the axial and limb muscles. The muscle construction is usually vigorous but may also be mild. The muscle activity in an individual spasm typically consists of two phases, an initial phasic component, usually lasting less than 2sec, followed by a more sustained but less intense tonic component lasting up to 10sec in duration (Hrachovy and Frost, 2003). Infantile spasms usually develop in clusters. During the day 2 - 3 clusters may develop with 20 – 150 spasms per cluster. (Panayiotopoulos, 2005). It is noted that intensity of motor spasms may wax and wane. Diversity between one spasm and another has been well documented by Bisuli et al (2002). The intensity of the spasms sometimes seems to grow progressively, especially at the beginning of the cluster, but then tends to fluctuate variously. The entire phenomenon can be considered as a single seizure, but it is difficult to note a clear relationship between one spasm and another. Fusco and Vigevano (1993) reported that, the interval of time between spasms varies.

Spasms usually develop on awaking, in relatively rare occasions during the NREM sleep. The transitional stage between sleep and wakefulness may be a provocative factor for the spasms

(Panayiotopoulos, 2005). Various factors have been described to precipitate motor spasms. These include handling, loud noise, feeding, infection, excitement, fright, anger, fever, hunger and excessive environmental temperature (Anandam, 1983, Baird, 1959, Chao et al., 1957, Druckman and Chao, 1955, Taylor, 1952). These reports however were largely anecdotal.

Spasms may be flexor, flexor extensor and less frequently extensor dominated. Spasms may involve extensive groups of muscles or be fragmented and involve a small group of muscles thus resulting in flexion of the neck only, abdomen or just the shoulders. In rare cases all the seizures may be constituted only with psychomotor arrest or just a paroxysmal, rapid deviation of the eyes. Spasms may be subtle and manifest with only episodes of yawning, gasping, facial grimacing, isolated eye movements, and transient focal motor activity (Panayiotopoulos, 2005).

Spasms may be symmetrical or asymmetrical. The type of the spasms, whether flexor or extensor, or intensity of the spasms do not have a prognostic or diagnostic value, whereas asymmetric, lateralized or unilateral spasm may be indicative for the underlying, contralateral focal lesion (e.g. focal cortical dysplasia) (Fusco and Vigeveno, 1993). Periods of decreased responsiveness, which have been termed "arrest," may occur after motor spasms and also may occur independently (Hrachovy and Frost, 2003).

Infantile spasms are the main seizure type of the syndrome, although other types of seizures may also develop, such as: tonic, clonic, focal or combination of the focal seizures and spasm.

Psychomotor retardation

In two thirds of the cases delay in psychomotor development, whether mild, moderate or severe can be present before the manifestation of the syndrome. In the rest of the cases development may be normal prior to seizure onset. The deterioration of the development becomes obvious after the seizure onset and is mainly manifested with the loss of head control or visual tracking or fixation. Axial hypotony and loss of visual contact is bad prognostic sign.

1.1.4 Etiology

According to the etiological factor West syndrome is classified as probably genetic, structural / metabolic and of unknown cause (Berg and Scheffer, 2011). The most frequent etiological factors of epileptic spasms are presented in the table 1.

Table 1 Main causes of epileptic spasms

Prenatal	<p>Neurocutaneous disorders</p> <ul style="list-style-type: none"> • Tuberosc sclerosis • Sturge-Weber disease • Incontinentia pigmenti (Bloch-Sulzberger syndrome) • Neurofibromatosis <p>Chromosomal abnormalities</p> <ul style="list-style-type: none"> • Down syndrome • Miller-Dieker syndrome (17p13 chromosomal deletion) <p>Malformations of cerebral development</p> <ul style="list-style-type: none"> • Aicardi syndrome • Agyria (lissencephaly), pachygyria, polymicrogyria, schizencephaly, laminar heterotopia and other diffuse cortical dysplasias <p>Hypoxic-ischaemic encephalopathies</p> <p>Congenital infections</p> <p>Trauma</p>
Perinatal	<p>Hypoxic-ischaemic encephalopathies</p> <p>Congenital infections</p> <p>Trauma</p> <p>Intracranial hemorrhage</p>
Postnatal	<p>Metabolic</p> <ul style="list-style-type: none"> • Pyridoxine dependency • Non-ketotic hyperglycinaemia • Phenylketonuria • Maple syrup urine disease • Mitochondrial encephalopathy <p>Infection</p> <p>Trauma</p> <p>Degenerative disease</p> <p>Drugs (theophylline and anti-allergic agents of histamine H1 antagonists such as ketotifen)</p>

Adapted from "The Epilepsies, seizures, syndromes and management" (Panayiotopoulos, 2005)

1.1.5 Pathogenesis

The pathophysiologic mechanisms underlying infantile spasms are poorly understood. Studies on functional neuroimaging mostly with PET technology in West syndrome have revealed putamen, brainstem and various cortical regions playing an important role in the pathogenesis of hypsarrhythmia (Chugani et al., 1990, Chugani et al., 1992, Chiron et al., 1993, Haginoya et al., 2000, Hrachovy et al., 1981, Morimatsu et al., 1972, Metsahonkala et al., 2002, Neville, 1972, Satoh et al., 1986, Hrachovy and Frost, 2003). Using simultaneous EEG-fMRI recordings, Siniatchkin et al. (2007) have demonstrated recently, that the high-amplitude slow cortical activity in hypsarrhythmia is associated with positive BOLD effects in putamen and brainstem, and that multifocal epileptiform discharges are correlated with positive BOLD effects in occipital cortex and various other cortical areas.

According to the model of infantile spasms proposed by Hrachovy and Frost (1989) disruption of certain monoaminergic or cholinergic areas within the region of the pontine reticular formation involved in control of sleep cycling could be the primary defect in this disorder. This model suggests that clinical seizures would result from phasic interference of descending brainstem pathways that control spinal reflex activity, whereas activity in the ascending pathways from these same brainstem areas that project widely to the cerebral cortex could produce the characteristic EEG features and possibly disturbances of cognitive function as well (Hrachovy and Frost, 2003).

Positron emission tomography (PET) studies had revealed focal or regional metabolic changes in the cortex of many infantile spasm patients, significantly increased metabolic activity in the lenticular nuclei in the majority of subjects, and increased metabolic activity in the brainstem of some patients (Hrachovy and Frost, 2003). Chugani, et al (2002, 1992) proposed that the primary dysfunction in infantile spasms is a focal or diffuse cortical abnormality, which, at a critical stage of development, triggers abnormal function of the serotonergic neurons in the brainstem raphe nuclei. Activation of the raphe-striatal pathway could then result in the observed hypermetabolic changes seen in the lenticular nuclei, whereas the raphe-cortical projections could be responsible for the hypsarrhythmic EEG pattern. According to this model, spasms would result from projections of the activated brainstem regions to the spinal cord neurons as well as from the lenticular activation. This model provides an explanation for the observation that patients with infantile spasms with lesions confined to the cerebral cortex can have their spasms abolished and their EEGs improved after resection of cortical lesions (Chugani et al., 1990, Uthman et al., 1991, Wyllie et al., 1996b, Hrachovy and Frost, 2003). It is still unclear, however, which structures in the described network are primarily responsible for hypsarrhythmia.

Dulac et al (1994) proposed a similar model, postulating that spasms arise from subcortical structures such as the basal ganglia, as a result of functional deafferentation caused by continuous abnormal cortical activity, whereas the EEG pattern, hypsarrhythmia, directly reflects the cortical dysfunction. Avanzini et al. (2002) also favor a mechanism based on cortical-subcortical interaction. Lado and Moshe (2002) have proposed yet another model that postulates that proconvulsant changes are necessary in both cortical and brainstem regions for the disorder to develop (Hrachovy and Frost, 2003).

1.1.6 Electroencephalogram

Interictal EEG – Hypsarrhythmia

Hypsarrhythmia is an interictal, background EEG activity, which develops in two thirds of the cases. It is characterized by chaotic mixture of abnormal, gigantic, arrhythmic and asynchronous slow and sharp waves, multifocal spikes and polyspikes (Panayiotopoulos, 2005). These spikes vary from moment to moment, both in localization and duration. At times they appear to be focal and few seconds later they seem to originate from multiple foci. Occasionally the spikes become generalized, but it never appears a rhythmically repetitive and highly organized pattern (Dulac, 2005). This abnormality is almost continuous during the wakefulness. During sleep there is an increase in spike and polyspike activity, that tend to become more synchronous, and there is a fragmentation of the hypsarrhythmic activity (Dulac, 2005).

The typical pattern of hypsarrhythmia has been reported to occur in 7% to 75% of patients with infantile spasms (Alva-Moncayo et al., 2002, Anandam, 1983, Druckman and Chao, 1955, Jacobi and Neirich, 1992, Jeavons et al., 1970, Kholin et al., 2002, Vacca et al., 1992). In many of the other patients, variations or modifications of the originally described pattern are seen (Hrachovy and Frost, 2003).

Atypical or modified hypsarrhythmia develops in one third of the cases. Its prognostic and diagnostic value is not proven. Hypsarrhythmia may occur with increased intrahemispheric synchronization, where the multifocal spike and sharp wave activity and the diffuse asynchronous slow wave activity are replaced or intermixed with activity that exhibits a significant degree of interhemispheric synchrony and symmetry (Hrachovy and Frost, 2003).

Hemihypsarrhythmia or unilateral hypsarrhythmia is characterized by the presence of hypsarrhythmia, with a consistent amplitude asymmetry between hemispheres. In general asymmetric hypsarrhythmia is associated with underlying structural abnormalities of the brain (Hrachovy and Frost, 2003).

Ictal EEG

Many different ictal EEG patterns corresponding to the spasms have been described (Kellaway et al., 1979). Fusco and Vigeveno (1993) demonstrated that the most characteristic ictal EEG pattern of the spasms in West syndrome consisted with a positive wave over the vertex-central region; a medium-amplitude fast activity at 14–16 Hz, called spindle-like and a diffuse flattening called decremental activity. By carefully studying the correlation between clinical manifestations and ictal EEG in 36 West syndrome cases documented with video-EEG and polygraphic recordings, Fusco and Vigeveno (1993) established that the slow wave was present in all cases and always corresponded to the clinical manifestation of the spasm. The fast activity occurred alone or was followed by the slow wave.

The true spasm consists in a muscular contraction that lasts from 1 to 2 s and reaches a peak more slowly than a myoclonic jerk, but more rapidly than a tonic seizure. It then decreases equally as fast and appears polygraphically as a sort of ‘rhombus’. The ictal EEG counterpart is a high-amplitude slow wave, with an inverse phase reversal over the vertex regions (Vigeveno et al., 2001).

1.1.7 Neuroimaging

Brain MRI should be done in all cases. It’s better to be done prior to the initiation of the treatment with steroids (which may cause brain shrinkage).

1.1.8 Management

Adrenocorticotrophic hormone (ACTH) oral corticosteroids and Vigabatrin are the first line drugs, which in two third of the cases reduce the EEG abnormalities in the first days of the treatment. Although, these drugs do not improve the long term intellectual outcome of these infants.

Lamotrigine, nitrazepam, pyridoxine, sulthiame, valproate and zonisamide are used as a second line drug in case of ineffectiveness of the ACTH, corticosteroids and Vigabatrine.

Hrachovy and Frost (2003) presented a summary of 214 therapeutic trials (1958–2002) and concluded - based on analysis of the available data - that: “1) All of the investigated agents have demonstrated some degree of efficacy in the treatment of infantile spasms. 2) Although both ACTH and corticosteroids are efficacious in treating infantile spasms, most investigators believe that ACTH is relatively more effective. 3) There is no convincing evidence that higher doses of ACTH are more effective than lower dosages of the drug. 4) Vigabatrin and ACTH are relatively equal in their effectiveness. 5) Vigabatrin appears to be particularly effective in treating a subset of infantile spasm patients with tuberous sclerosis. 6) Response to therapy typically occurs within 1 to 2 weeks of initiation of therapy, regardless of the agent. 7) Relapse rates for the majority of studies range from one quarter to one third of patients. 8) There are no definite predictors of acute response to treatment”.

In drug resistant cases neurosurgery is considered effective (Branch and Dyken, 1979, Dolman et al., 1981, Mimaki et al., 1983, Ruggieri et al., 1989, Uthman et al., 1991, Wyllie et al., 1996a, Chugani et al., 1993, Adelson et al., 1992, Hoffman, 2002).

1.1.9 Prognosis

Prognosis is mainly determined by the underlying disorder and its severity. Epileptic spasms itself may have a less prognostic value.

In developed countries mortality is 5%. Death may be due to the underlying disorder or treatment with corticosteroids. It is less often due to the seizures. More than a half of the patients develop other types of the drug resistant seizures. In most common cases West syndrome evolves into the Lennox-Gastaut syndrome or complex focal epilepsy. Half of the patients have permanent motor disabilities and two third have severe cognitive and psychological impairment. Only approximately 5 – 12% of patients have normal mental and motor development (Hrachovy and Frost, 2003).

1.2. Source analyses

Electroencephalography (EEG) is an important tool for studying the temporal dynamics of the human brain's large-scale neuronal circuits (Michel et al., 2004). Good temporal resolution of EEG allows

better interpretation of different parts of neuronal networks, for example, the separation of brain areas with the initial epileptic activity from regions of propagation (Groening et al., 2009, Vulliemoz et al., 2009, Siniatchkin et al., 2010) and better analysis of relationship between activities in different brain regions (Schelter et al., 2009). However, EEG signals measured on the scalp surface do not directly indicate the location of the active neurons in the brain due to the ambiguity of the underlying static electromagnetic inverse problem (Michel et al., 2004). Particularly electrical source imaging of brain activity generated in deep brain structures, such as the subcortical nucleus (e.g. thalamus) was not possible in previous studies (Holmes, 2008, Holmes et al., 2010, Holmes et al., 2004).

New solutions for the inverse problem of the EEG have been developed which improve the localization power of the EEG substantially, even for deep sources and thus enabling us to use EEG data in order to investigate the neuronal networks. Dynamic imaging of coherent sources (DICS) is one of these solutions. DICS is a source analysis method which is able to detect brain regions that are coherent with each other and a reference signal or region (Gross et al., 2001). It works in the frequency domain for EEG and MEG data and is able to describe neuronal networks by imaging power and coherence of oscillatory brain activity using a spatial filter (Gross et al., 2001). Applied to different types of tremor and voluntary motor control, DICS was able to characterize networks including deep structures such as the diencephalon (e.g. the thalamus) the cerebellum and the brainstem in magnetoencephalographic (MEG) studies (Gross et al., 2001, Gross et al., 2002, Timmermann et al., 2003b, Timmermann et al., 2003a, Sudmeyer et al., 2006, Schnitzler et al., 2006) as well as thalamus in a recent EEG study (Moeller et al., 2011 (in press)). However, the interaction between the different network components cannot be resolved by DICS alone (Gross et al., 2002, Hellwig et al., 2000, Hellwig et al., 2001, Hellwig et al., 2003, Schack et al., 2003, Tass et al., 1998, Volkman et al., 1996). In order to analyze the effective connectivity and informational flow between sources, the renormalized partial directed coherence (RPDC) is applied. The RPDC is a parametric technique that has been introduced as being capable of analyzing not only multivariate networks in neuroscience and to infer interrelations therein, but also to allow conclusions about causal dependencies based on Granger causality (Baccala and Sameshima, 2001, Sameshima and Baccala, 1999, Schelter et al., 2009)

1.3 Aims of the study

The objective of this study was to elucidate the network that generates the high-amplitude slow wave activity in infants with infantile spasms and hypsarrhythmia using DICS and RPDC. In order to evaluate the specificity of pathogenetic mechanisms of hypsarrhythmia, these infants were compared with children suffering from complex partial seizures. In order to validate the results obtained

with DICS, we compared the results of electrical source imaging with EEG - fMRI results obtained previously from the same data sets of EEG-fMRI recordings (Siniatchkin et al., 2007).

2. MATERIALS AND METHODS

2.1 Subjects

From our database of EEG-fMRI recordings we selected 8 patients with infantile spasms and hypsarrhythmia (group I, 5 cryptogenic and 3 symptomatic, mean age, 7.62 ± 2.87 months) and 8 patients with drug resistant focal epilepsies (Group II, 3 cryptogenic, 5 symptomatic, mean age, 20.75 ± 12.52 months). Clinical and demographical data of the patients are presented in the table 2.

All patients were recruited from the Department of Neuropediatrics at the University Hospital Schleswig Holstein Campus Kiel and Northern German Epilepsy Centre for Children & Adolescents, Schwentinental/OT Raisdorf, Germany.

In Group I clusters of infantile spasms were the main seizure type and EEG was showing hypsarrhythmia in all patients (Fig. 1). Patients from Group II had partial, drug resistant epilepsies of structural/metabolic or unknown cause. The drug resistance was defined as failure of adequate trials of two tolerated and appropriately chosen and used AED schedules (whether as monotherapies or in combination) to achieve sustained seizure freedom (Kwan et al., 2010). Epilepsy was categorized as of unknown aetiology if clinical, laboratory and neuroradiological investigations failed to identify any causative factor. All patients from the control group had background EEG activity of diffuse, multifocal slow waves and epileptiform abnormalities (Fig. 2).

Table 2. Demographic and clinical Data of the Group I and II

Patients (Gender)	Age	Aetiology	EEG	Seizure types	AED
1(f)	6 m	cryptogenic	hypsarrhythmia	IS	Pyridoxal-5- Phosphat, Folic acid, VGB, Corti-

					sone,
2(m)	12 m	symptomatic ^a	hypsarrhythmia	IS	VGB, VPA
3(m)	11m	cryptogenic	hypsarrhythmia	IS.	VPA,VGB, STM
4(m)	6m	symptomatic ^b	hypsarrhythmia	IS	VGB, VPA
5(m)	12m	cryptogenic	hypsarrhythmia	IS	VGB, LEV
6(m)	6m	cryptogenic	hypsarrhythmia	IS	VGB, STM
7(m)	8m	cryptogenic	hypsarrhythmia	IS	CBZ, VPA, VGB,
8(f)	10m	symptomatic ^c	hypsarrhythmia	IS, myoclonic seizures	TPM, LEV
9(m)	10m	symptomatic ^d	multifocal	CPS, SGTC	STM, TPM, VGB
10(m)	24m	symptomatic ^e	multifocal	CPS, Atypical absences,	VPA, TPM, STM
11(f)	19m	symptomatic ^d	multifocal	Tonic seizures, atonic seizures, myoclonic, CPS,	VGB, OXC
12(f)	6 yrs	cryptogenic	multifocal	Myoclonic, SGTC	VPA, LEV, LTG,
13(m)	10 y	symptomatic ^f	predominantly left temporal	Atonic, atypical absences	VPA; LTG,
14(m)	10 y	cryptogenic	multifocal	CPS, SGTC atypical absences	STM, LTG
15(m)	1 y	symptomatic ^g	multifocal	CPS	OXC; CLN, PB
16(f)	2 y	cryptogenic	multifocal	Tonic, myoclonic seizures	OXC, VPA

Note – patients 1- 8 had West syndrome, patient 9 – 16 are from the control group of drug resistant partial epilepsies

CPS – complex partial seizures, SGTC – secondary generalised tonic clonic seizures, IS – Infantile spasms. STM – sulthiame, TPM – Topiramate, VGB – Vigabatrin, VPA – Valproic Acid, OXC – oxcarbazepine, LTG – Lamotrigine, CLN – , LEV – Levetiracetam. PB – Phenobarbital

a- Gliosis and encephalomalacia of the left gyrus supramarginal

b - Focal cortical displasia in the left gyrus hippocampalis

c - Gliosis and encephalomalacia in the occipital region

d – Tuberoses scleroses complex

e – perinatal asphyxia, HIE

f - Gliosis and encephalomalacia after the intracranial haemorrhage

g - Primary microcephaly

Figure 1: Hypsarrhythmia

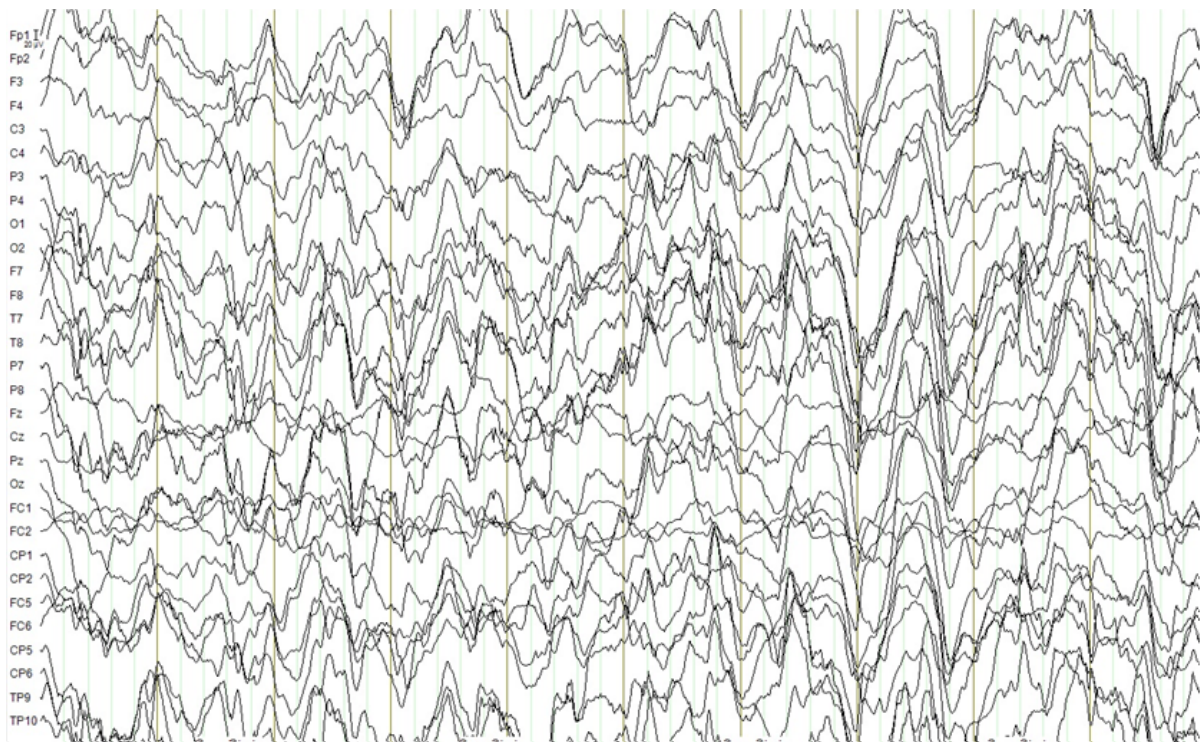


FIG.: 1 Hypsarrhythmia: showing diffuse, bilateral, asynchronous high amplitude slow waves in a 7 month old patient with cryptogenic West syndrome

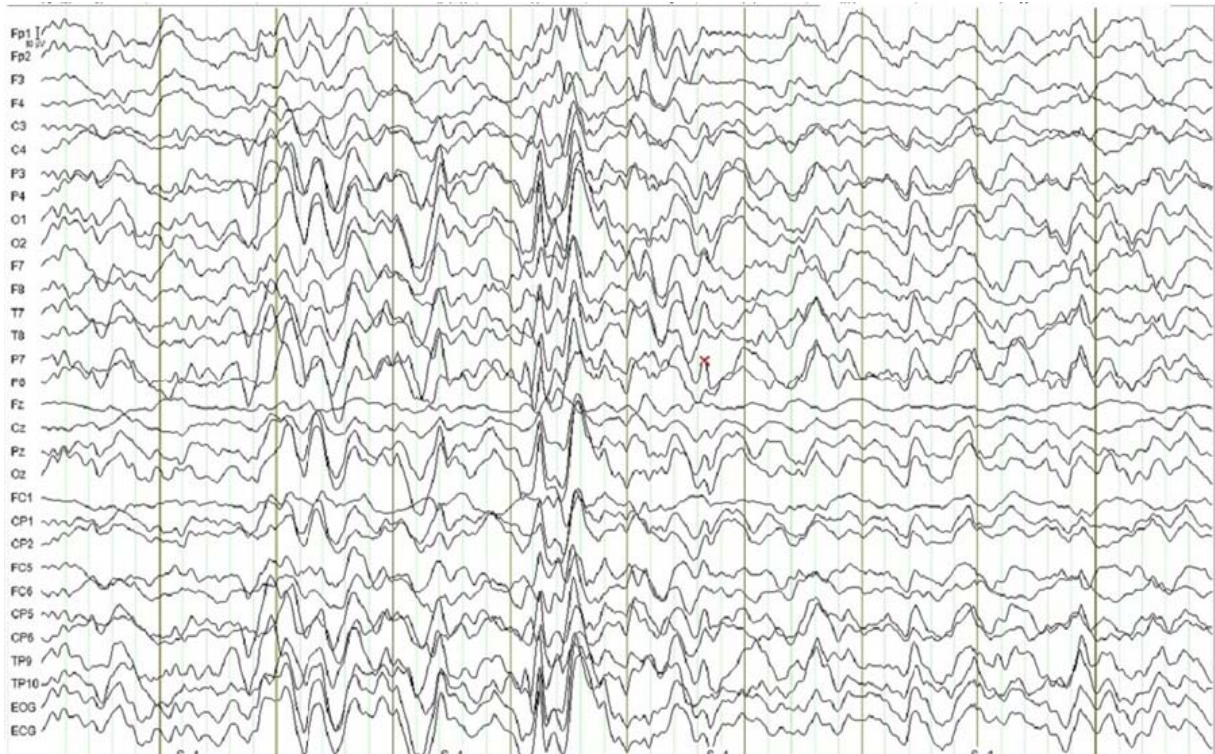
Figure 2: Control group

Fig.: 2 Diffuse slowing of the background in a 10 month old patient with symptomatic resistant partial epilepsy

Only one patient from the Group II had a prominent focus in the left temporal region that was concordant with the location of the lesion. Diagnoses were made according to the ILAE 2001 classification scheme (Commission on Classification and Terminology of the International League Against Epilepsy, 2001). The neurological examination and structural MRI (high-resolution 3T - T1, T2, FLAIR-T2, and diffusion-weighted imaging) were performed before the inclusion in the study. Routine EEGs (21 electrodes in accordance with the International 10–20 system) were recorded 1–2 days before the EEG-fMRI investigation and were evaluated by at least two specialists independently, who confirmed the type of EEG abnormality, i.e., hypersarrhythmia in group I or multifocal, diffuse slow waves and epileptiform abnormalities in group II. All patients had global developmental delay of different severity what was assessed by neurological examination and clinical scale (Denver Developmental Scale, Frankenburg and Bresnik 1998). All children were sedated with chloral hydrate 30 minutes before EEG-fMRI recordings which were performed when the children were asleep. A paediatrician was present throughout the examination.

2.2 EEG recording

The EEG was continuously recorded during fMRI from 30 scalp sites (10 – 20 system plus FC1, FC2, CP1, CP2, FC5, FC6, CP5, CP6, TP9, TP10) with a reference located between Fz and Cz. Sintered Ag/AgCl ring electrodes with built-in 5 kOhm resistors were attached using the “EasyCap” (Falk-Minow Services, Herrsching-Breitbrunn, Germany), which is part of the MR-compatible EEG recording system “BrainAmp-MR” (Brainproducts Co., Munich, Germany). Electrode impedance was kept below 10 kOhms. Two additional electrodes were placed on the infraorbital ridge of the left eye for recordings of the vertical EOG and on the left perivertebral part of the lower back for acquisition of the electrocardiogram (ECG). Data were transmitted from the high-input impedance amplifier (250 Hz low-pass filter, 10 s time constant, 16-bit resolution, dynamic range 16.38 mV)

2.3 Simultaneous EEG-fMRI recordings and data processing

EEG was processed offline using the BrainVision Analyser software (Brain Products). Gradient artifacts as a result of electromagnetic distortion of the EEG through static and dynamic magnetic field during MR data acquisition and ballistocardiogram artifacts were removed using the averaged artifact subtraction (AAS) method described by Allen et al. (2000, 1998). After artifact correction, the data were down-sampled to 250 Hz and were low-pass filtered at 75 Hz (Siniatchkin et al., 2007).

The detailed description of simultaneous EEG and fMRI recordings, the protocol of MR artifact correction of the EEGs and fMRI analysis with the general linear model and canonical haemodynamic response function is presented in our previous publication (Siniatchkin et al., 2007).

2.4 EEG analysis

Considering that slow wave activity and not epileptiform discharges has been proposed to specifically represent the hypsarrhythmia (Hrachovy and Frost, 2003) and high voltage slow waves have been discussed to constitute a part of the neuronal process in the generation of spasms (Fusco and Vigeveno, 1993, Kobayashi et al., 2005) we decided to analyze high amplitude, 1 to 4 Hz – delta waves in each patient from both groups.

2.4.1 Selection of EEG epochs:

For the DICS analyses the EEG segments with the highest concentration of delta waves had to be chosen. For this reason estimation of a pooled time frequency power spectrum was performed. This method was chosen over the visual inspection and selection by experienced neurophysiologist in order to avoid the subjective selectivity bias.

In all cases the whole 20-minute EEG recording was taken. The first step was to estimate a pooled time frequency power spectrum from the original power estimates of the individual EEG electrodes. This can be done by pooling the individual second order spectra using a weighting scheme and evaluating the pooled estimate of power as previously described (Amjad et al., 1997, Rosenberg JR, 1989). The time frequency pooled power spectrum was estimated using the multitaper method (Mitra PP, 1999). By this method, the spectrum is assessed by multiplying the data $x(t)$ with K different windows (i.e tapers). A more detailed description of the method is explained elsewhere et al (Muthuraman et al., 2010a). The length of the windows was 1000 ms that provided a time resolution of 1s and a frequency resolution of 1Hz. The second step was to calculate the 90th percentile power values in the frequency range of 1-4 Hz for each subject, followed by the estimation of the mean and standard deviation (mean \pm 2std; M2SD) of the 90th percentile power values which is the threshold in each subject. All the data epochs, which were above this threshold, were taken for further analysis (Fig. 3 and Supp. Fig. 1).

From each subject 30 seconds of data were selected for further analysis. At the end, the relative signal to noise ratio (SNR) was calculated by taking the (100-200 Hz) frequency as noise and the (1-4 Hz) mean of the 90th percentile values as the signal.

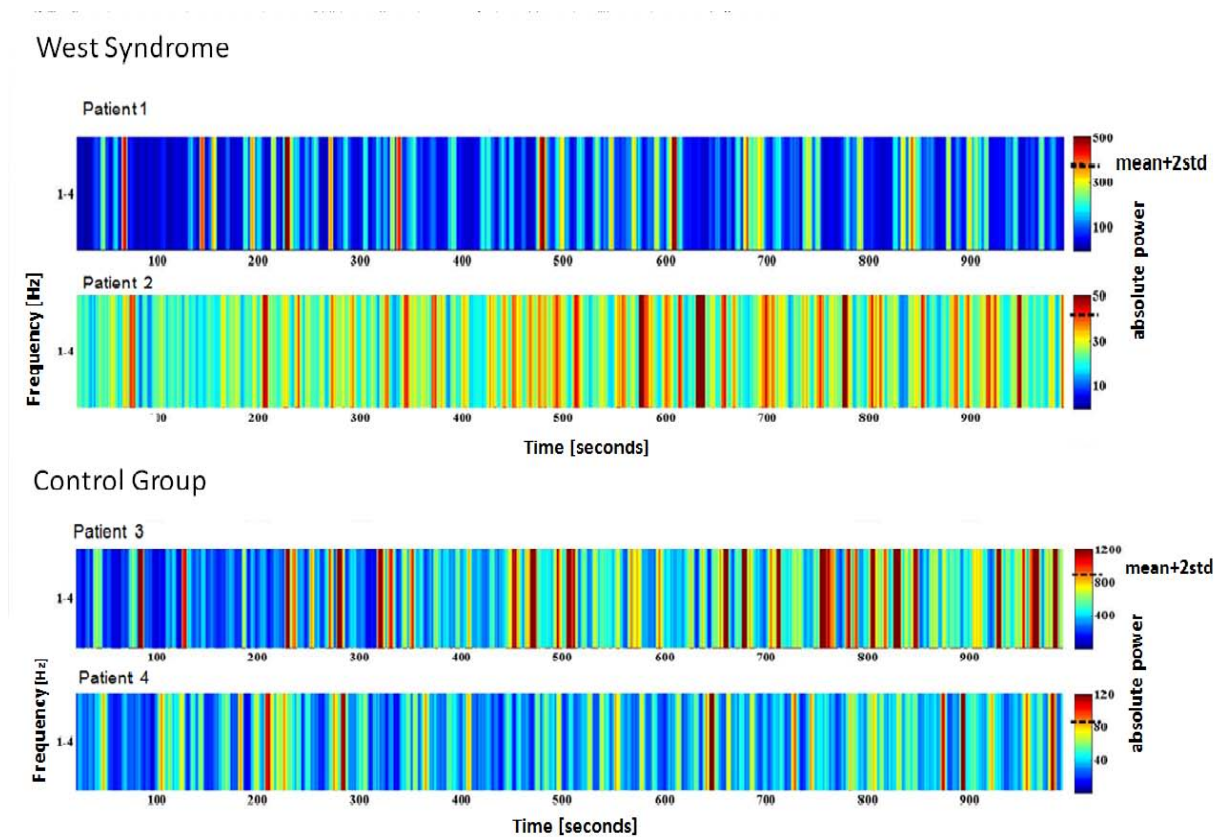
Figure 3: Pooled Power Spectra

FIG 3.: Pooled Power Spectra. (Patient 1 – 2 West syndrome Group; Patient 3-4 Control group patients). Estimation of a pooled time frequency power spectrum from the original power estimates of the individual EEG electrodes. *Note: Color bar showing the absolute power; Dashed line indicating the threshold mean+2std*

2.4.2 Source Analysis

Dynamic imaging of coherent sources (DICS) (Gross et al., 2001) was used to find the sources of the epileptic activity in the brain. The DICS analysis was performed in a blinded fashion, so the analyst did not know the patients' diagnoses. In order to locate the origin of specific EEG activity seen on the scalp, two problems need to be solved which are the forward and inverse problem. The forward problem is the computation of the scalp potentials for a set of neural current sources. It is solved by estimating the lead-field matrix with specified models for the brain. In this study, the brain was modeled by a more complex, five-concentric-spheres model (Zhang, 1995) with a single sphere for each

layer corresponding to the white matter, grey matter, cerebral spinal fluid (CSF), skull and skin. The volume conductor model was created using standard T1 magnetic resonance images (Zhang, 1995). The template model created was then warped on to the standard head model. The open source software fieldtrip was used (Oostenveld R, 2011). The head was modeled by giving in the radius and the position of the sphere with the standard electrode locations. In order to map the current dipoles in the human brain to the voltages on the scalp, the lead-field matrix (LFM) needs to be calculated. The lead-field matrix was estimated using the boundary-element method (BEM) (Fuchs et al., 2002). The LFM contains the information about the geometry and the conductivity of the model. The complete description of the solution for the forward problem has been described previously by (Muthuraman et al., 2010b).

The inverse problem is the quantitative estimation of the properties of the neural current sources underlying the EEG activity. The neural activity is modeled as a current dipole or sum of current dipoles. The power and coherence at any given location in the brain can be computed using a linear transformation which in our case is the spatial filter (Drongelen et al., 1996). In this study, the linear constrained minimum variance (LCMV) spatial filter was used which relates the underlying neural activity to the electromagnetic field on the surface. The main aim of the LCMV method (Drongelen et al., 1996) was to design a bank of spatial filters that attenuates signals from other locations and allows only signals generated from a particular location in the brain. The DICS-method employed a spatial filter algorithm (Drongelen et al., 1996) to identify the spatial power maximum or coherence in the brain for a particular frequency band. It uses a regularization parameter which determines the spatial extent of source representation. For all analyses the same regularization parameter of $\alpha = 0.001$ was used. This value has been shown to yield reliable results in simulation studies and in MEG data (Kujala et al., 2008). The brain region representing the strongest power in a specific frequency band can subsequently be used as a reference region for cortico-cortical coherence analysis (Gross et al., 2001). In order to create topographic maps, the spatial filter is applied to a large number of voxels covering the entire brain using a voxel size of 5 mm. The individual maps of coherence were spatially normalized and interpolated on a standard T1 brain in SPM2. The application of the spatial filter has been described elsewhere (Muthuraman et al., 2008).

For groups of patients, the brain source with the strongest power in the 1-4 Hz band was identified and defined as the reference region for further coherence analysis between brain areas. Since the coherence of a reference region with itself is always 1, the reference region was projected out of the coherence matrix, and further coherent areas were found. The statistical significance of the identified coherent sources was tested by a within subject surrogate analysis. A Monte Carlo test of 100 random permutations was carried out, and the Monte Carlo p-value ($\alpha = 0.05$) was calculated (Maris

and Oostenveld, 2007, Maris et al., 2007). This analysis was performed for each patient separately, followed by a grand average of the significant sources across all patients.

Once coherent brain areas were identified, their activity was extracted from the surface EEG by the spatial filter as described in Van Veen et al. (1997).

In order to test the possibility to localize sources in deep brain structures on the basis of only 32-channel EEG, simulation I was performed with the real data. The most important aspect of this simulation was to change the angle of the dipole orientation from 0° to 180° at 10° steps as shown in (Supp. Fig 2).

The reasons for the importance of the dipole orientation are whether the activated source can be first of all seen and at the same time how many of those electrodes on the scalp actually record part of those signals by the used EEG channel configuration. The forward modeling was done by assuming different channel configurations in steps of from 8-channel to 64-channels. More detailed description of the simulation is presented in supplementary texts and previous publications (Moeller et al., 2011 (in press), Muthuraman et al., 2011) .

2.4.3 Directionality Analysis:

Coherence analysis only reveals components that are common to two signals in the frequency domain. It does not give the direction of information flow between the two signals. In this study we applied renormalized partial directed coherence (RPDC) (Schelter et al., 2009) which is a technique performed in the frequency domain to detect the direction of information flow from one signal to the other and vice versa. The RPDC method applies a multivariate (MVAR) modeling approach which uses an autoregressive process to obtain the coefficients of the signals in the frequency band of 1-4 Hz. In order to obtain these coefficients the correct model order needs to be chosen which is estimated by minimizing the Akaike Information Criterion (AIC) (Akaike, 1974) and gives the optimal order for the corresponding signal (Ding et al., 2000). After estimating the RPDC values the significance level is calculated from the applied data using a bootstrapping method (Kaminski M, 2001). In this manuscript the open source matlab package ARFIT was used (Neumaier and Schneider, 2001, Schneider and Neumaier, 2001) for estimating the autoregressive coefficients from the spatially filtered source signals.

3. RESULTS

3.1 Dynamic Imaging of Coherent Sources

3.1.1 West syndrome group:

The grand average of the sources described by DICS analysis for the patients of both groups are shown in the figure 4 (Results of DICS analyses for individual patients are shown in supplementary figure 3). In patients with West syndrome, the source of the strongest power at the frequency band 1-4 Hz was detected in the occipital regions in all 8 cases. Occipital sources were bilateral in 6 cases and unilateral in 2 cases (1 right and 1 left sided). The local maximum of this source varied slightly across the patients (Supp. Fig. 3). This first source was defined as the reference region for further coherence analysis between brain areas. West syndrome cases commonly showed the common four sources coherent with the first source, and there were only small differences across the patients with respect to the local maxima of the sources (Supp. Fig. 1). Sources with the strongest coherence with the reference source were found in the parietal cortex (second source) bilaterally in 6 patients and unilaterally in two patients. The next strongest coherence was detected in frontal regions in seven cases (5 bilateral and 2 unilateral) and in bilateral temporal regions in only one case. Subsequent sources were detected in putamen in all 8 patients, whereas the last coherent source was found in the brainstem in all 8 patients.

3.1.2 Control group:

In the control group, the source of the strongest power in the 1-4 Hz band was detected in temporal regions in all 8 cases (6 bilateral and 2 unilateral, respectively). The local maximum of these sources varied slightly across the patients (Supp. Fig 3). This first source was defined as the reference region for further coherence analysis between brain areas. The source with the strongest coherence with the reference source was found in the occipital cortex (second source) bilaterally in 6 patients and unilaterally in two patients. The third and the last coherent region in this frequency band were found in central regions in all 8 cases (bilateral in 6 and unilateral in 2 cases, respectively).

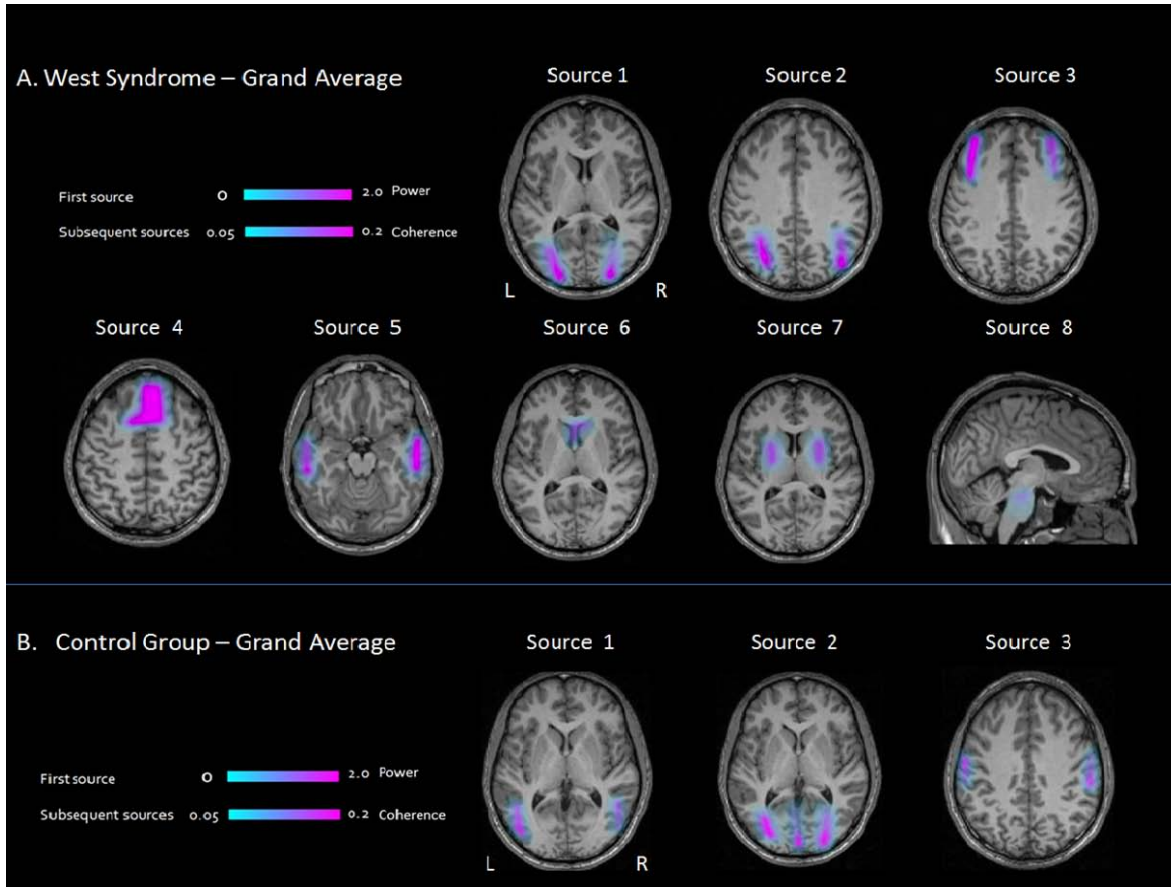
Figure 4: DICS grand average analyses results

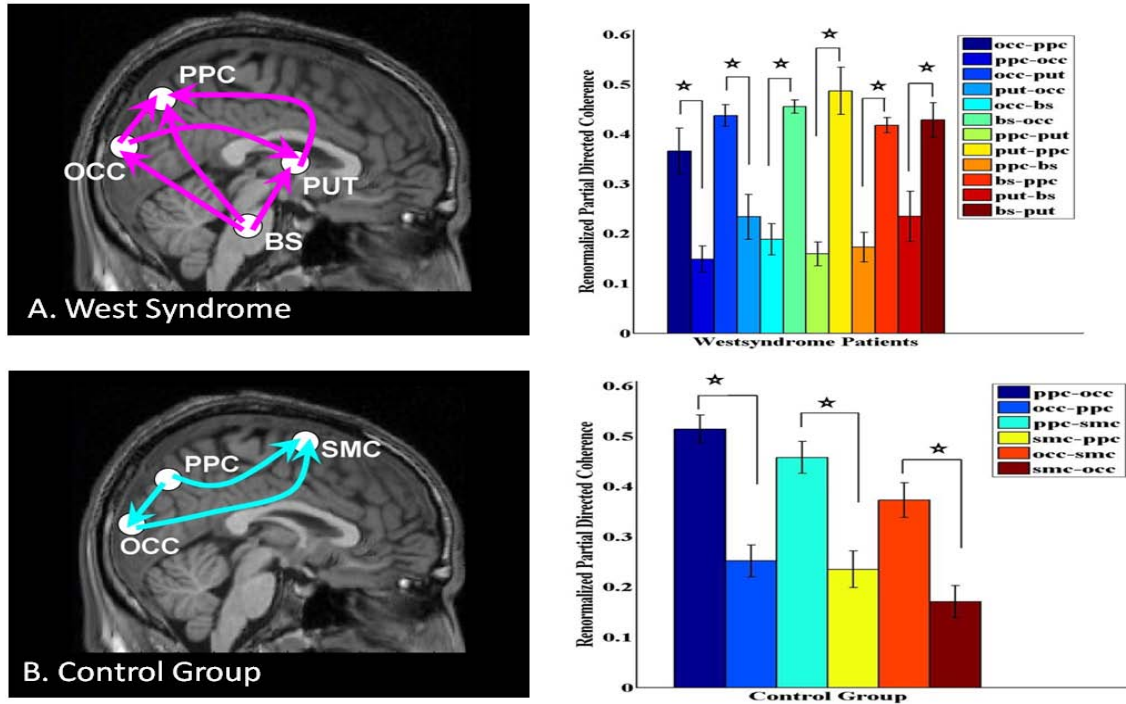
FIG.: DICS grand average analyses results. Showing sources in cortical (occipital, parietal and frontal) and subcortical (lenticular nucleus, brainstem) regions in West syndrome patients (A) and sources only in cortical regions in patients with resistant partial Epilepsies (B)

3.2 Renormalized Partial Directed Coherence

In patients with West syndrome, RPDC showed that the direction of information flow was significantly stronger from brainstem (source 4) towards the occipital, parietal regions and putamen (sources 1, 2 and 3), rather than vice versa. Also, the stronger RPDC was detected from the putamen (source 4) towards the parietal regions (source 2) and from the occipital regions (source 1) toward the parietal region (source 2). See figure 5.

In the control group, RPDC showed that the direction of informational flow was significantly stronger from temporal region (source 1) towards the occipital region and precentral gyrus (source 3). Also the stronger RPDC was detected from the occipital region towards the precentral gyrus (figure 5).

Figure 5: RPDC Group analysis



The RPDC group analysis results showing the direction of the informational flow between the sources estimated by the DICS analyses in patients with the West syndrome (A) and Control group (B) patients. (OCC-occipital cortex, PPC-posterior parietal cortex, PUT-putamen, BS-Brainstem, SMC-Sensorimotor cortex).

4. DISCUSSION

4.1 Functional connectivity in hypsarrhythmia

Using the algorithm of DICS, the study describes the neuronal network underlying hypsarrhythmia by imaging power and coherence of oscillatory brain activity (Gross et al., 2001). Results of DICS analysis demonstrated that the high-amplitude slow activity within the hypsarrhythmia can be attributed to coherent sources in the brainstem, basal ganglia, as well as in occipital, frontal and parietal cortical regions. In patients with partial epilepsies, the slow activity in the same frequency range was attributed to sources only in cortical regions (occipital, parietal, sensory-motor cortex). Therefore, it seems likely that the functionally related sources underlying hypsarrhythmia represent a specific network or rather a fingerprint of this condition.

The results of DICS analysis represented functional connectivity in hypsarrhythmia and were in line with EEG-fMRI results obtained from the same data sets. These fMRI results showed that multifocal epileptiform discharges within the hypsarrhythmia were associated with the complex and diverse pattern of cortical activations, whereas the high-amplitude slow activity in hypsarrhythmia correlated with BOLD signal changes in putamen and brainstem (Siniatchkin et al., 2007). Moreover, the results of this study are also consistent with results of previous PET and SPECT studies demonstrating significant metabolic changes in cortex, putamen and brainstem in patients suffering from infantile spasms (Chugani et al., 1990, Metsahonkala et al., 2002). Because the DICS for slow frequency activity revealed similar networks as other neuroimaging techniques, it can be suggested that the putamen, brainstem and cortico-subcortical interactions contribute substantially to the generation of the high-voltage slow activity and play an essential role in the pathogenesis of both infantile spasms and hypsarrhythmia. High voltage slow waves have been discussed to constitute a part of the neuronal process in the generation of spasms (Fusco and Vigevano, 1993, Kobayashi et al., 2005). Slow wave activity and not epileptiform discharges has been proposed to specifically represent the hypsarrhythmia because in some cases this EEG phenomenon consists of either only high-voltage slow wave activity or a combination of slow waves and very little spike/sharp wave activity (Alva-Moncayo et al., 2002, Hrachovy and Frost, 2003). Moreover, interictal slow wave activity has been associated with poor developmental outcome in West syndrome (Kramer et al., 1997).

It is important to emphasize that all infants with hypsarrhythmia had the strongest source in the occipital cortex. These findings are supported by previous observations that the posterior cortex may be important in the pathogenesis of infantile spasms (Wenzel, 1987, Guzzetta et al., 2002, Metsahonkala et al., 2002, Rando et al., 2005, Siniatchkin et al., 2007, Juhasz et al., 2001). It has been shown that the visual abnormalities such as poor visual responsiveness, abnormal visual evoked potentials, and deficits in fixation shift can already be detected at the early stages of West syndrome and even before (Wenzel, 1987, Guzzetta et al., 2002, Rando et al., 2005). Focal posterior cortical hypometabolism has been found in a great proportion of children with the West syndrome (Chugani et al., 1990, Chiron et al., 1993, Jambaque et al., 1993, Metsahonkala et al., 2002). There is a discrepancy, however, concerning the relation between the occipital cortex and pathological changes in hypsarrhythmia. In this study, the occipital source is related to the high-voltage slow activity. In contrast, our previous fMRI study demonstrated that the epileptic spikes are associated with BOLD signal changes in the posterior brain regions. In the case of occipital cortex both methods DICS and fMRI may appear complementary to each other. We suggest that the occipital cortex represents a common part of neuronal networks responsible for epileptiform discharges and high-amplitude slow activity. Unfortunately, these suggestions have not been proven appropriately in the past. In this study, we did not analyze frequencies of epileptiform discharges. It is difficult to do such analyses from a methodological point of view because the spikes do not occur in a specific frequency range. In the fMRI study of Siniatchkin et al. (2007) the lack of association of high-amplitude slow activity with BOLD signal changes in occipital cortex may be attributed to either an insufficient statistical power (only 8 children were investigated) or a common variance of both regressors (epileptiform discharges and slow activity), which reduced sensitivity of the analysis. Whatever the explanation for discrepancies between studies, both studies demonstrated that the occipital cortex is an important node in the neuronal network of hypsarrhythmia.

4.2 Effective connectivity in hypsarrhythmia

It has been poorly understood how putamen, brainstem and occipital cortex within the described network of hypsarrhythmia are related to each other. Based on DICS, it was possible to describe interrelation and informational flow (effective connectivity) between different sources using the method of the RPDC (Schelter et al., 2009). In West syndrome patients, RPDC showed that the strongest direction of influences was an ascending informational flow from the brainstem towards putamen and cerebral cortex. Our findings are supported by considerable evidence suggesting that the brainstem is the area from which the spasms and the hypsarrhythmic EEG pattern arise (Chugani

et al., 1992, Hrachovy et al., 1981, Morimatsu et al., 1972, Neville, 1972, Satoh et al., 1986). Hrachovy and Frost (1989) had published a model of infantile spasms suggesting that disruption of certain monoaminergic or cholinergic areas within the region of the pontine reticular formation involved in control of sleep cycling could be the primary defect in this disorder. According to this model, the clinical seizures would result from phasic interference of descending brainstem pathways that control spinal reflex activity; whereas the activity in the ascending pathways from these same brainstem areas project widely to the cerebral cortex and could produce the characteristic EEG features and possibly disturbances of cognitive function (Hrachovy and Frost, 2003). This hypothesis is based on the observation that patients with infantile spasms have decreased REM sleep duration, a sleep period during which there is normalization of the EEG with a decrease in the number of spasms. Brainstem serotonergic neurons are involved in sleep cycles and depletion of serotonin may decrease REM sleep. Langlais and colleagues provided data supporting a serotonin dysfunction hypothesis by demonstrating reduced levels of 5-Hydroxyindoleacetic acid (5-HIAA), a metabolite of serotonin, as well as decreased levels of homovanillic acid and 3-methoxy-4-hydroxyphenyl glycol (MHPG) in patients with infantile spasms. It is yet undetermined, whether these changes are the cause for West syndrome or whether these changes are a consequence of West syndrome (Langlais et al., 1991).

Our results are in line with PET studies, which had revealed focal or regional metabolic changes in the cortex of many infantile spasm patients (even in some patients with normal CT/MRI studies), significantly increased metabolic activity in the lenticular nuclei in the majority of subjects, and increased metabolic activity in the brainstem of some patients (Hrachovy and Frost, 2003). Chugani et al (2002, 1992) proposed that the primary dysfunction in infantile spasms is a focal or diffuse cortical abnormality, which, at a critical stage of development, triggers abnormal function of the serotonergic neurons in the brainstem raphe nuclei. Activation of the raphe-striatal pathway could then result in the observed hypermetabolic changes seen in the lenticular nuclei, whereas the raphe-cortical projections could be responsible for the hypsarrhythmic EEG pattern (Hrachovy and Frost, 2003). Lado and Moshe (2002) have proposed another model suggesting that proconvulsant changes are necessary in both cortical and subcortical regions for the development of infantile spasms.

4.3 Methodological considerations

DICS is a powerful technique of electrical source imaging which investigates neuronal interactions by imaging power and coherence estimates of oscillatory brain activity (Gross et al., 2001). DICS has

been used to characterize neuronal networks in a number of neurological disorders (Gross et al., 2001, Gross et al., 2002, Timmermann et al., 2003a, Timmermann et al., 2003b). It is noteworthy that not only cortical sources but also sources in deep structures were detected using DICS (Gross et al., 2001, Gross et al., 2002, Timmermann et al., 2003a, Timmermann et al., 2003b, Sudmeyer et al., 2006, Schnitzler et al., 2006). In the study of Moeller et al (2011 (in press)) DICS was applied to different types of generalized epileptiform discharges and showed cortical and thalamic involvement which was in line with the EEG-fMRI data obtained previously from the same data sets. Although subcortical sources have been demonstrated in the previous studies applying DICS to oscillatory signals, it remains a matter of debate whether subcortical sources can be detected in EEG signals recorded from the skull surface. A first concern might be that DICS is locating artificial midline subcortical sources due to distributed activity in the cortex. However, the simulation described by Moeller et al (2011 (in press)) demonstrated that DICS does not locate any artificial sources. A second concern could be that the application of inverse algorithms to 32-channel EEG is unable to correctly locate sources in the deep structures of the brain like thalamus, cerebellum and brainstem. The simulation I, however, indicated that the deep sources like brainstem can be identified when there is higher signal to noise ratio and certain dipole orientation (see supplementary figure 2 and supplementary text). The reason is the spatial extent of the electrode configurations on the head from 8 to 64 channels which does not contain any electrodes on the posterior region below the inion and the more frontal part above the eyelids in the simulation. In all West syndrome subjects, the dipole orientation of the brainstem source were identified with a 32-channel configuration are pointing towards the cortex with an angle of 90° . This is the first reason to support the fact that the brainstem source was found in all West syndrome subjects with the results of the simulation. The second reason is the spatial filtering approach that has been extensively tested earlier with different electrode configurations from the standard 10-20 system to 32 channels. It has been described that the standard sphere head model will have better accuracy with the source located in the centre of the sphere with certain dipole orientations depending on the spatial extent of the electrodes in Van Veen et al. (1997).

To validate results of the EEG-source analysis we compared results of this study with results obtained by a second technique with an undoubted spatial resolution also in the depth of the brain. We therefore applied DICS to EEGs recorded in EEG-fMRI study in patients with West syndrome and partial epilepsies (Siniatchkin et al., 2007). Thus we were able to directly compare the results of coherent source analysis (DICS) to EEG-fMRI results in the same events and patients. The comparison revealed a high correspondence between the methods applied. However, we would like to point out some limitations in our analysis. Firstly, we focused only on the high-amplitude slow activity and did not

analyze neuronal networks associated with epileptiform discharges in hypsarrhythmia. Therefore, our considerations concerning mechanisms of hypsarrhythmia are limited to this phenomenon. Secondly, the DICS has two major limitations as applied in this paper. Firstly the estimation of the source activity is done by using a single dipole as the underlying model and this is susceptible to the presence of highly correlated sources (Schoffelen et al., 2008). The second limitation is that the standard head model was used with standard electrode locations. To increase the localization accuracy of the sources the individual electrode locations can be used in the estimation of the individual lead field matrix.

5. CONCLUSION

The study shows that EEG-based coherent source analysis is a powerful technique to map oscillatory activity also from subcortical structures. Consistent with the EEG-fMRI results, the sources in the brainstem and basal ganglia were only detected in cases of West syndrome and were absent in all cases of the control group. RPDC in West syndrome patients was able to detect strongest direction of information flow from the brainstem, broadly projecting towards the putamen and cerebral cortex.

6. SUMMARY

Objective: West syndrome is a severe epileptic encephalopathy of infancy with a poor developmental outcome. This syndrome is associated with a pathognomonic EEG feature - hypsarrhythmia. The aim of the study was to describe neuronal networks underlying hypsarrhythmia using the source analysis method (dynamic imaging of coherent sources or DICS) which represents an inverse solution algorithm in the frequency domain. Moreover, to investigate the interaction within the detected network renormalized partial directed coherence (RPDC) method was additionally applied as a measure of directionality of information flow between the source signals.

Methods: Both DICS and RPDC were performed for the EEG delta activity (1 - 4 Hz) in 8 patients with West syndrome and in 8 patients with partial epilepsies (control group). The brain area with the strongest power in the given frequency range was defined as the reference region. The coherence between this reference region and the entire brain was computed using DICS. After that, the RPDC was applied to the source signals estimated by DICS. The results of electrical source imaging were compared to results of a previous EEG-fMRI study which was carried out in the same cohort of patients.

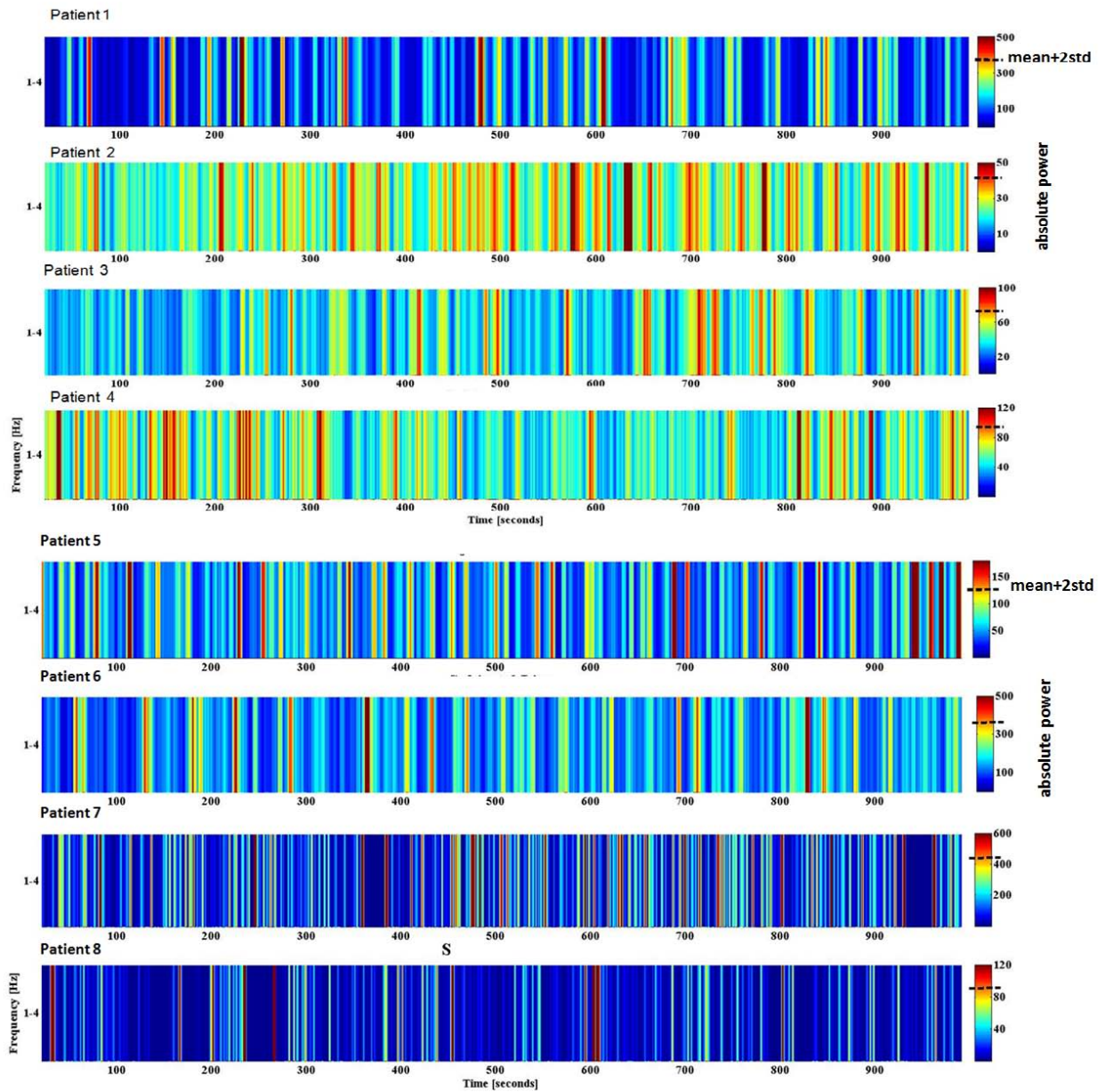
Results: As revealed by DICS, delta activity in hypsarrhythmia was associated with coherent sources in the occipital cortex (main source) as well as parietal cortex, putamen, caudate nucleus and brainstem. In patients with partial epilepsies, delta activity could be attributed to sources in the occipital, parietal and sensory-motor cortex. In West syndrome, RPDC showed the strongest and significant direction of ascending information flow from the brainstem towards putamen and cerebral cortex.

Conclusions: The neuronal network underlying hypsarrhythmia in this study resembles the network that was described in previous EEG-fMRI and PET studies with an involvement of brainstem, putamen and cortical regions in the generation of hypsarrhythmia. The RPDC suggests a key role of brainstem in the pathogenesis of West syndrome. This study supports the theory that hypsarrhythmia results from ascending brainstem pathways that project widely to basal ganglia and cerebral cortex.

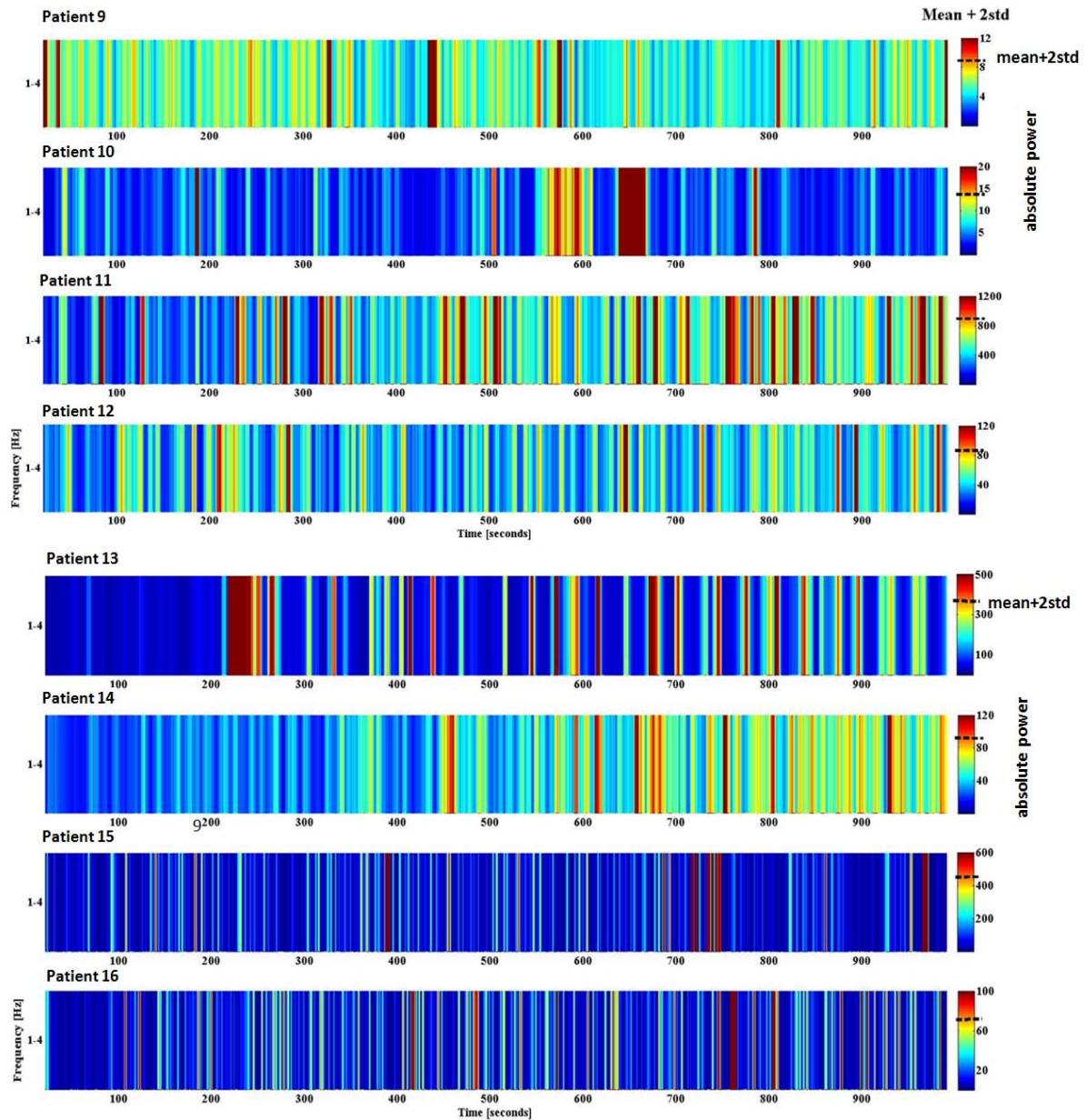
7. APPENDIX

7.1 Supplementary figures

Supplementary figure 1 (A):



Supplementary figure 1 (B):

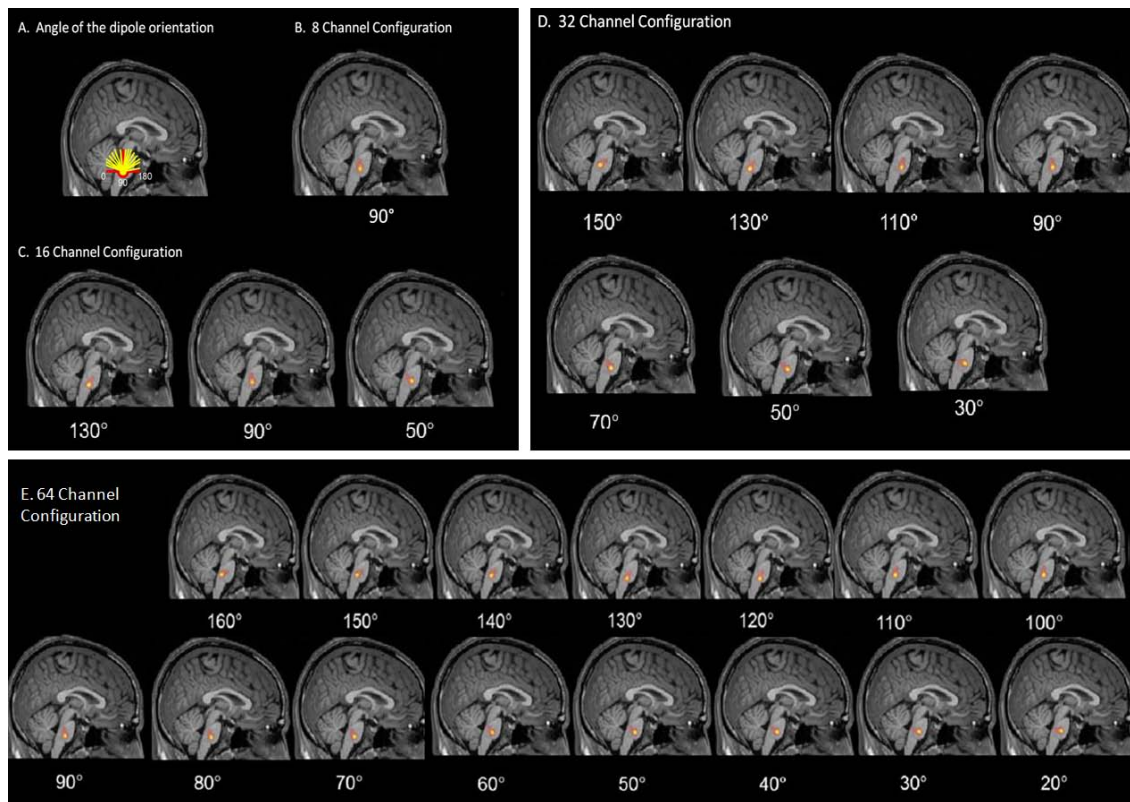


Supp FIG.: 1. (A) Pooled power spectra of the West syndrome patients – estimation of a pooled time frequency power spectrum from the original power estimates of all the individual EEG electrodes.

(B) Pooled power spectra of the Control Group patients – estimation of a pooled time frequency power spectrum from the original power estimates of all the individual EEG electrodes.

Note: Color bar showing the absolute power; Dashed line indicating the threshold $\text{mean} + 2\text{std}$

Supplementary figure 2:



Supp FIG.: 2 Simulation I. A. Changing the angle of the dipole orientation from 0° to 180° in steps of 10° . The forward modeling was done by assuming different, from 8 to 64, channel configurations.

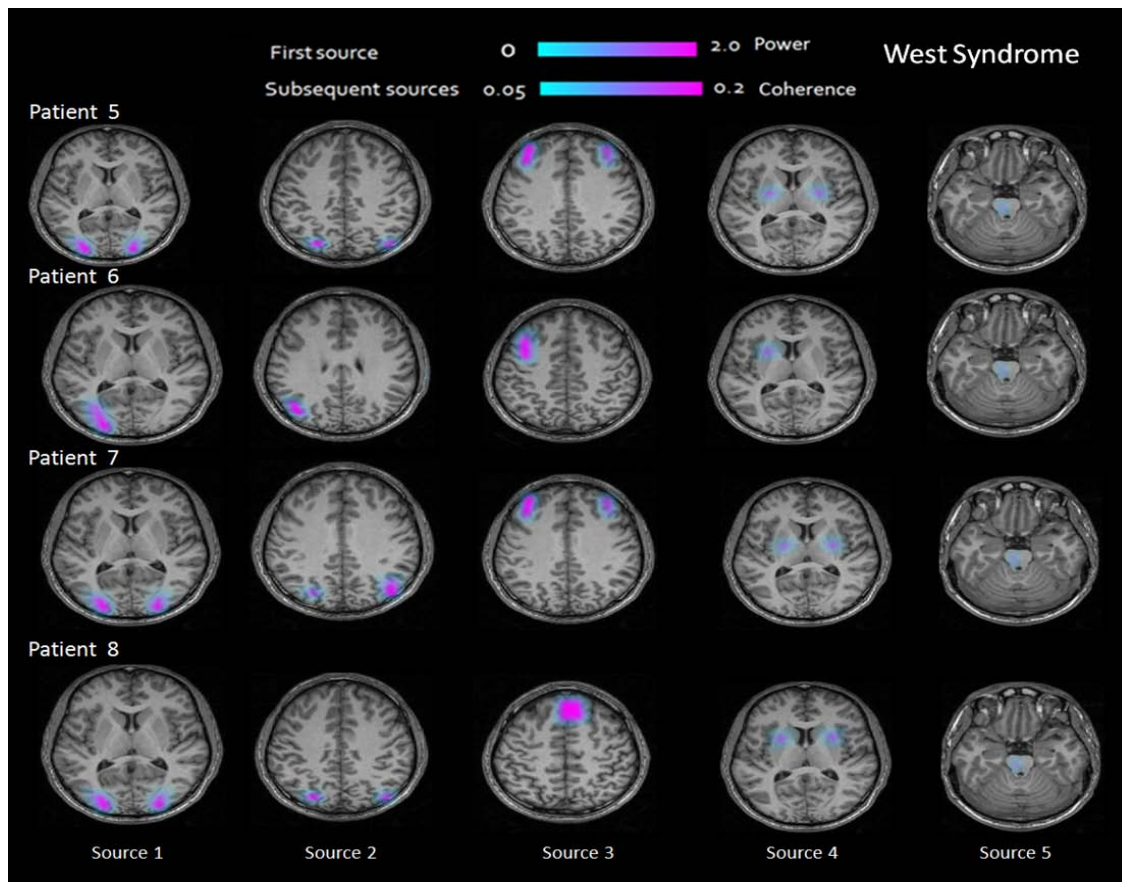
B. 8 channel configurations: simulated brainstem source was found only at dipole orientation angle 90° .

C. 16 channel configurations: simulated brainstem source was found only at dipole orientation angle 50° , 90° and 130°

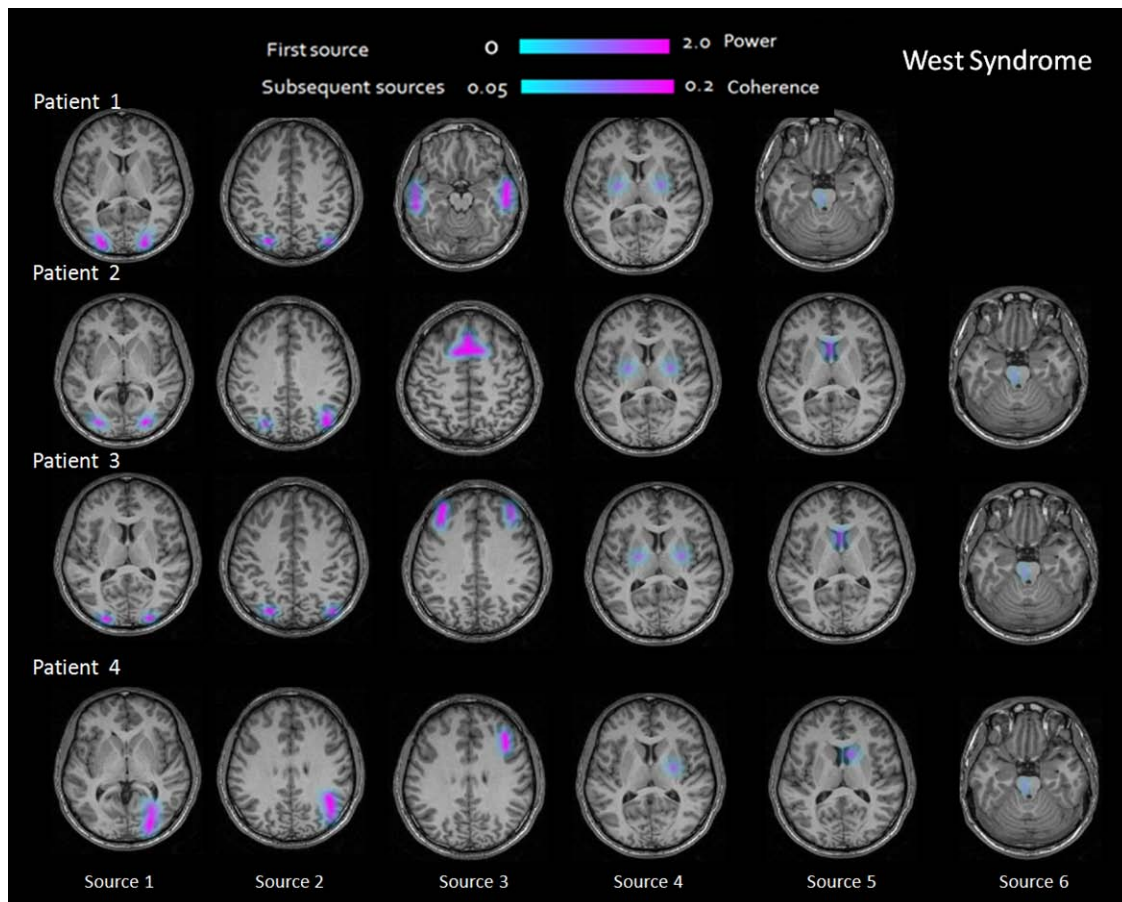
D. 32 channels configuration: only on every 20° starting from 30° to 150° the simulated brain stem source was found

E. 64 channels configuration: all dipole orientation from 20° to 160° showed the simulated brainstem source

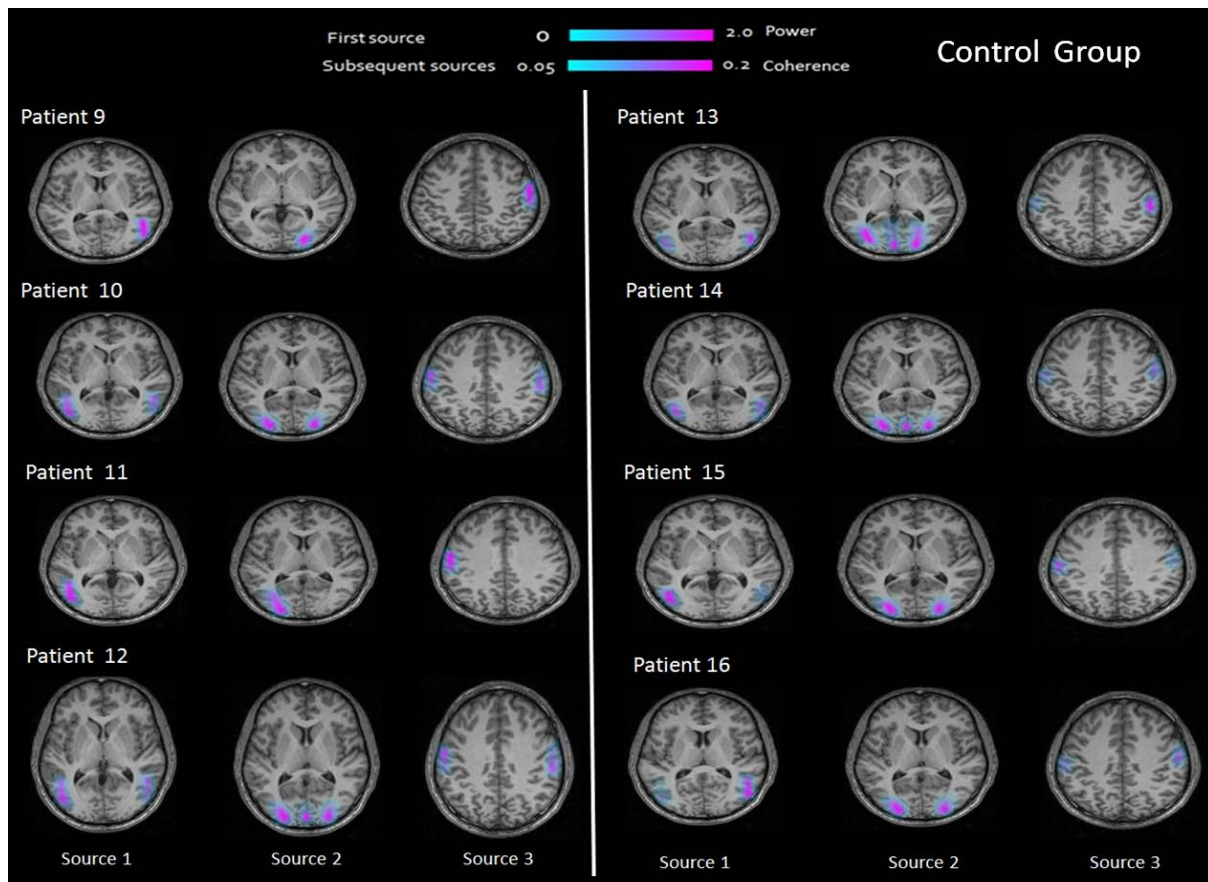
Supplementary Figure 3 (A):



Supplementary Figure 3 (B):



Supplementary Figure 3 (C):



Supp FIG.:3 DICS analyses results from all patients individually in both groups. Showing sources in cortical (occipital, parietal and frontal) and subcortical (lenticular nucleus, brainstem) regions in West syndrome patients (A and B) and sources only in cortical regions in patients with resistant partial Epilepsies (C).

7.2 Supplementary Text

Simulation

In order to test the possibility to localize sources in deep brain structures on the basis of only 32-channel EEG, simulation I was performed with the real data. The spatially filtered source signal for the frequency band 1-4Hz from the brain stem source was extracted and the signal to noise ratio (SNR) was estimated (18 dB). In order to model the signal as close to the real data as possible the source signal was fitted with an AR2 process (ARFIT), which had the same SNR in the 1-4 Hz frequency band. The source signal was implemented in the same active voxel which was found in the real data. The “EEG signal” was produced with a broad-band AR2 plus white noise of 25% (SNR=4.5dB) (compared to the clean 1-4 Hz AR2 signal of 18dB SNR) added to the other voxels. The most important aspect of this simulation was to change the angle of the dipole orientation from 0° to 180° at 10° steps as shown in (Supp. Fig 2). The forward modeling was done by assuming different channel configurations in steps of 8 from 8-channel to 64-channels. The initial test was done when the dipole orientation was at 0°, 10°, 170° and 180° the source analysis should not find any active source because the forward model does not contain any EEG electrodes on these areas projecting on the scalp. As expected, the results for these dipole orientation angles did not find any source in the brain for the frequency band 1-4 Hz in all the channel configurations from 8 to 64-channels. In the case of 64-channel configurations the dipole orientation from 20° to 160° all showed the simulated brain stem source as shown in Supp Fig. 2. Interestingly, in the 32-channel configuration systematically only every 20° starting from 30° to 150° the brain stem source was found. In the 16-channel only the dipole orientation angle 50°, 90° and 130° and in the 8-channel only at 90° the source was found. These simulations gives us two important results: 1) different channel configurations can locate deep sources such as in the brainstem if there is sufficient signal to noise ratio as seen in the real data, and 2) the density of the electrodes on the scalp plays a vital role in locating deep sources in the brain with this source analysis algorithm. It seems likely that the number of electrodes used in this study is enough to result in a valid source analysis.

8. REFERENCES

- ADELSON, P. D., PEACOCK, W. J., CHUGANI, H. T., COMAIR, Y. G., VINTERS, H. V., SHIELDS, W. D. & SHEWMON, D. A. 1992. Temporal and extended temporal resections for the treatment of intractable seizures in early childhood. *Pediatr Neurosurg*, 18, 169-78.
- AKAIKE, H. 1974. A new look to the stastical model identification. *IEEE Transactions on automatic control*, 19, 716:723.
- ALLEN, P. J., JOSEPHS, O. & TURNER, R. 2000. A method for removing imaging artifact from continuous EEG recorded during functional MRI. *Neuroimage*, 12, 230-9.
- ALLEN, P. J., POLIZZI, G., KRAKOW, K., FISH, D. R. & LEMIEUX, L. 1998. Identification of EEG events in the MR scanner: the problem of pulse artifact and a method for its subtraction. *Neuroimage*, 8, 229-39.
- ALVA-MONCAYO, E., DIAZ-LEAL, M. C. & OLMOS-GARCIA DE ALBA, G. 2002. [Electroencephalographic discoveries in children with infantile massive spasms in Mexico]. *Rev Neurol*, 34, 928-32.
- AMJAD, A. M., HALLIDAY, D. M., ROSENBERG, J. R. & CONWAY, B. A. 1997. An extended difference of coherence test for comparing and combining several independent coherence estimates: theory and application to the study of motor units and physiological tremor. *J Neurosci Methods*, 73, 69-79.
- ANANDAM, R. 1983. Clinical and electroencephalographic study of infantile spasms. *Indian J Pediatr*, 50, 515-8.
- AVANZINI, G., PANZICA, F. & FRANCESCHETTI, S. 2002. Brain maturational aspects relevant to pathophysiology of infantile spasms. *Int Rev Neurobiol*, 49, 353-65.
- BACCALA, L. A. & SAMESHIMA, K. 2001. Partial directed coherence: a new concept in neural structure determination. *Biol Cybern*, 84, 463-74.
- BAIRD, H. W., 3RD 1959. Convulsions in infancy and childhood. *Conn Med*, 23, 149-51.
- BEDNAREK, N., MOTTE, J., SOUFFLET, C., PLOUIN, P. & DULAC, O. 1998. Evidence of late-onset infantile spasms. *Epilepsia*, 39, 55-60.
- BERG, A. T. & SCHEFFER, I. E. 2011. New concepts in classification of the epilepsies: entering the 21st century. *Epilepsia*, 52, 1058-62.
- BISULLI, F., VOLPI, L., MELETTI, S., RUBBOLI, G., FRANZONI, E., MOSCANO, M., D'ORSI, G. & TASSINARI, C. A. 2002. Ictal pattern of EEG and muscular activation in symptomatic infantile spasms: a videopolygraphic and computer analysis. *Epilepsia*, 43, 1559-63.
- BRANCH, C. E. & DYKEN, P. R. 1979. Choroid plexus papilloma and infantile spasms. *Ann Neurol*, 5, 302-4.
- BRNA, P. M., GORDON, K. E., DOOLEY, J. M. & WOOD, E. P. 2001. The epidemiology of infantile spasms. *Can J Neurol Sci*, 28, 309-12.
- CHAO, D. H., TAYLOR, F. M. & DRUCKMAN, R. 1957. Massive spasms. *J Pediatr*, 50, 670-8.
- CHIRON, C., DULAC, O., BULTEAU, C., NUTTIN, C., DEPAS, G., RAYNAUD, C. & SYROTA, A. 1993. Study of regional cerebral blood flow in West syndrome. *Epilepsia*, 34, 707-15.
- CHUGANI, H. T. 2002. Pathophysiology of infantile spasms. *Adv Exp Med Biol*, 497, 111-21.
- CHUGANI, H. T., SHEWMON, D. A., SANKAR, R., CHEN, B. C. & PHELPS, M. E. 1992. Infantile spasms: II. Lenticular nuclei and brain stem activation on positron emission tomography. *Ann Neurol*, 31, 212-9.

- CHUGANI, H. T., SHEWMON, D. A., SHIELDS, W. D., SANKAR, R., COMAIR, Y., VINTERS, H. V. & PEACOCK, W. J. 1993. Surgery for intractable infantile spasms: neuroimaging perspectives. *Epilepsia*, 34, 764-71.
- CHUGANI, H. T., SHIELDS, W. D., SHEWMON, D. A., OLSON, D. M., PHELPS, M. E. & PEACOCK, W. J. 1990. Infantile spasms: I. PET identifies focal cortical dysgenesis in cryptogenic cases for surgical treatment. *Ann Neurol*, 27, 406-13.
- DING, M., BRESSLER, S. L., YANG, W. & LIANG, H. 2000. Short-window spectral analysis of cortical event-related potentials by adaptive multivariate autoregressive modeling: data preprocessing, model validation, and variability assessment. *Biological Cybernetics*, 83, 35-45.
- DOLMAN, C. L., CRICHTON, J. U., JONES, E. A. & LAPOINTE, J. 1981. Fibromatosis of Dura Presenting as Infantile Spasms. *Journal of the Neurological Sciences*, 49, 31-39.
- DRONGELEN, W., YUCHTMAN, M., VANVEEN, B. D. & VANHUFFELEN, A. C. 1996. A spatial filtering technique to detect and localize multiple sources in the brain. *Brain Topography*, 9, 39-49.
- DRUCKMAN, R. & CHAO, D. 1955. Massive spasms in infancy and childhood. *Epilepsia*, 4, 61-72.
- DULAC, O. 2001. What is West syndrome? *Brain Dev*, 23, 447-52.
- DULAC, O., CHIRON, C., ROBAIN, O., PLOUIN, P., JAMBAQUE, I. I. & PINARD, J. M. 1994. Infantile spasms: a pathophysiological hypothesis. *Semin Pediatr Neurol*, 1, 83-9.
- DULAC, O., TUXHORN, I. 2005. Infantile spasms and West syndrome In: ROGER J, B. M., DRAVET CH, DRYFUSS FE, PERRET A, WOLF P (ed.) *Epileptic syndromes in infancy, childhood and adolescence*. 4th ed. France John Libbey Eurotex Ltd. .
- EPILEPSY, C. O. C. A. T. O. T. I. L. A. 1989. Proposal for revised classification of epilepsies and epileptic syndromes. *Epilepsia*, 30, 389-99.
- FUCHS, M., KASTNER, J., WAGNER, M., HAWES, S. & EBERSOLE, J. S. 2002. A standardized boundary element method volume conductor model. *Clinical Neurophysiology*, 113, 702-712.
- FUSCO, L. & VIGEVANO, F. 1993. Ictal clinical electroencephalographic findings of spasms in West syndrome. *Epilepsia*, 34, 671-8.
- GIBBS FA, G. E. 1952. *Atlas of electroencephalography*, MA.: Addison-Wesley;
- GROENING, K., BRODBECK, V., MOELLER, F., WOLFF, S., VAN BAALEN, A., MICHEL, C. M., JANSEN, O., BOOR, R., WIEGAND, G., STEPHANI, U. & SINIATCHKIN, M. 2009. Combination of EEG-fMRI and EEG source analysis improves interpretation of spike-associated activation networks in paediatric pharmacoresistant focal epilepsies. *Neuroimage*, 46, 827-33.
- GROSS, J., KUJALA, J., HAMALAINEN, M., TIMMERMANN, L., SCHNITZLER, A. & SALMELIN, R. 2001. Dynamic imaging of coherent sources: Studying neural interactions in the human brain. *Proc Natl Acad Sci U S A*, 98, 694-9.
- GROSS, J., TIMMERMANN, L., KUJALA, J., DIRKS, M., SCHMITZ, F., SALMELIN, R. & SCHNITZLER, A. 2002. The neural basis of intermittent motor control in humans. *Proc Natl Acad Sci U S A*, 99, 2299-302.
- GUZZETTA, F., FRISONE, M. F., RICCI, D., RANDO, T. & GUZZETTA, A. 2002. Development of visual attention in West syndrome. *Epilepsia*, 43, 757-63.
- HAGINOYA, K., KON, K., YOKOYAMA, H., TANAKA, S., KATO, R., MUNAKATA, M., YAGI, T., TAKAYANAGI, M., YOSHIHARA, Y., NAGAI, M., YAMAZAKI, T., MARUOKA, S. & IINUMA, K. 2000. The perfusion defect seen with SPECT in West syndrome is not correlated with seizure prognosis or developmental outcome. *Brain Dev*, 22, 16-23.

- HELLWIG, B., HAUSSLER, S., LAUK, M., GUSCHLBAUER, B., KOSTER, B., KRISTEVA-FEIGE, R., TIMMER, J. & LUCKING, C. H. 2000. Tremor-correlated cortical activity detected by electroencephalography. *Clin Neurophysiol*, 111, 806-9.
- HELLWIG, B., HAUSSLER, S., SCHELTER, B., LAUK, M., GUSCHLBAUER, B., TIMMER, J. & LUCKING, C. H. 2001. Tremor-correlated cortical activity in essential tremor. *Lancet*, 357, 519-23.
- HELLWIG, B., SCHELTER, B., GUSCHLBAUER, B., TIMMER, J. & LUCKING, C. H. 2003. Dynamic synchronisation of central oscillators in essential tremor. *Clin Neurophysiol*, 114, 1462-7.
- HOFFMAN, H. J. 2002. Surgery for West's syndrome. *Adv Exp Med Biol*, 497, 57-9.
- HOLMES, M. D. 2008. Dense array EEG: methodology and new hypothesis on epilepsy syndromes. *Epilepsia*, 49 Suppl 3, 3-14.
- HOLMES, M. D., BROWN, M. & TUCKER, D. M. 2004. Are "generalized" seizures truly generalized? Evidence of localized mesial frontal and frontopolar discharges in absence. *Epilepsia*, 45, 1568-79.
- HOLMES, M. D., QUIRING, J. & TUCKER, D. M. 2010. Evidence that juvenile myoclonic epilepsy is a disorder of frontotemporal corticothalamic networks. *Neuroimage*, 49, 80-93.
- HRACHOVY, R. A. & FROST, J. D., JR. 1989. Infantile spasms. *Pediatr Clin North Am*, 36, 311-29.
- HRACHOVY, R. A. & FROST, J. D., JR. 2003. Infantile epileptic encephalopathy with hypsarrhythmia (infantile spasms/West syndrome). *J Clin Neurophysiol*, 20, 408-25.
- HRACHOVY, R. A., FROST, J. D., JR. & KELLAWAY, P. 1981. Sleep characteristics in infantile spasms. *Neurology*, 31, 688-93.
- JACOBI, G. & NEIRICH, U. 1992. Symptomatology and electroencephalography of the 'genuine' type of the West syndrome and its differential diagnosis from the other benign generalized epilepsies of infancy. *Epilepsy Res Suppl*, 6, 145-51.
- JAMBAQUE, I., CHIRON, C., DULAC, O., RAYNAUD, C. & SYROTA, P. 1993. Visual inattention in West syndrome: a neuropsychological and neurofunctional imaging study. *Epilepsia*, 34, 692-700.
- JEAVONS, P. M., HARPER, J. R. & BOWER, B. D. 1970. Long-term prognosis in infantile spasms: a follow-up report on 112 cases. *Dev Med Child Neurol*, 12, 413-21.
- JUHASZ, C., CHUGANI, H. T., MUZIK, O. & CHUGANI, D. C. 2001. Neuroradiological assessment of brain structure and function and its implication in the pathogenesis of West syndrome. *Brain Dev*, 23, 488-95.
- KAMINSKI M, D. M., TRUCCOLO WA, BRESSLER SL 2001. Evaluating causal relations in neural systems: Granger causality, directed transfer function and statistical assessment of significance. *Biological Cybernetics* 85, 145-157.
- KELLAWAY, P., HRACHOVY, R. A., FROST, J. D., JR. & ZION, T. 1979. Precise characterization and quantification of infantile spasms. *Ann Neurol*, 6, 214-8.
- KHOLIN, A. A., MUKHIN, K., PETRUKHIN, A. S. & IL'INA, E. S. 2002. [Electroencephalographic characteristics of West syndrome]. *Zh Nevrol Psikhiatr Im S S Korsakova*, 102, 40-4.
- KOBAYASHI, K., OKA, M., INOUE, T., OGINO, T., YOSHINAGA, H. & OHTSUKA, Y. 2005. Characteristics of slow waves on EEG associated with epileptic spasms. *Epilepsia*, 46, 1098-105.
- KRAMER, U., SUE, W. C. & MIKATI, M. A. 1997. Hypsarrhythmia: frequency of variant patterns and correlation with etiology and outcome. *Neurology*, 48, 197-203.
- KUJALA, J., GROSS, J. & SALMELIN, R. 2008. Localization of correlated network activity at the cortical level with MEG. *Neuroimage*, 39, 1706-1720.

- KWAN, P., ARZIMANOGLU, A., BERG, A. T., BRODIE, M. J., ALLEN HAUSER, W., MATHERN, G., MOSHE, S. L., PERUCCA, E., WIEBE, S. & FRENCH, J. 2010. Definition of drug resistant epilepsy: consensus proposal by the ad hoc Task Force of the ILAE Commission on Therapeutic Strategies. *Epilepsia*, 51, 1069-77.
- LADO, F. A. & MOSHE, S. L. 2002. Role of subcortical structures in the pathogenesis of infantile spasms: what are possible subcortical mediators? *Int Rev Neurobiol*, 49, 115-40.
- LANGLAIS, P. J., WARDLOW, M. L. & YAMAMOTO, H. 1991. Changes in CSF neurotransmitters in infantile spasms. *Pediatr Neurol*, 7, 440-5.
- MARIS, E. & OOSTENVELD, R. 2007. Nonparametric statistical testing of EEG- and MEG-data. *J Neurosci Methods*, 164, 177-90.
- MARIS, E., SCHOFFELEN, J. M. & FRIES, P. 2007. Nonparametric statistical testing of coherence differences. *J Neurosci Methods*, 163, 161-75.
- METSAHONKALA, L., GAILY, E., RANTALA, H., SALMI, E., VALANNE, L., AARIMAA, T., LIUKKONEN, E., HOLOPAINEN, I., GRANSTROM, M. L., ERKINJUNTTI, M., GRONROOS, T. & SILLANPAA, M. 2002. Focal and global cortical hypometabolism in patients with newly diagnosed infantile spasms. *Neurology*, 58, 1646-51.
- MICHEL, C. M., MURRAY, M. M., LANTZ, G., GONZALEZ, S., SPINELLI, L. & GRAVE DE PERALTA, R. 2004. EEG source imaging. *Clin Neurophysiol*, 115, 2195-222.
- MIMAKI, T., ONO, J. & YABUUCHI, H. 1983. Temporal lobe astrocytoma with infantile spasms. *Ann Neurol*, 14, 695-6.
- MITRA PP, P. B. 1999. Analysis of dynamic brain imaging data. *Biophysical Journal*, 76.
- MOELLER, F., MUTHURAMAN, M., STEPHANI, U., DEUSCHL, G., RAETHJEN, J. & SINIATCHKIN, M. 2011 (in press). Representation and propagation of epileptic activity in absences and generalized photoparoxysmal responses *Human Brain Mapping*
- MORIMATSU, Y., MUROFUSHI, K., HANDA, T., SHINOARA, T. & SHIRAKI, H. 1972. [Pathology in severe physical and mental disabilities in children--with special reference to 4 cases of nodding spasm]. *Shinkei Kenkyu No Shimpo*, 16, 465-70.
- MUTHURAMAN, M., DEUSCHL, G. & RAETHJEN, J. 2011. Essential constraints for detecting deep sources in EEG-application to orthostatic tremor. *Conf Proc 4th IEEE Congress on Image and signal processing 2011*, 2760-2763.
- MUTHURAMAN, M., GALKA, A., DEUSCHL, G., HEUTE, U. & RAETHJEN, J. 2010a. Dynamical correlation of non-stationary signals in time domain--A comparative study *Biomedical Signal Processing and Control*, 5 205-213
- MUTHURAMAN, M., HEUTE, U., DEUSCHL, G. & RAETHJEN, J. 2010b. The central oscillatory network of essential tremor. *Conf Proc IEEE Eng Med Biol Soc*, 2010, 154-7.
- MUTHURAMAN, M., RAETHJEN, J., HELLRIEGEL, H., DEUSCHL, G. & HEUTE, U. 2008. Imaging coherent sources of tremor related EEG activity in patients with Parkinson's disease. *Conf Proc IEEE Eng Med Biol Soc*, 2008, 4716-9.
- NEUMAIER, A. & SCHNEIDER, T. 2001. Estimation of parameters and eigenmodes of multivariate autoregressive models. *ACM transactions on Mathematical software*, 27, 27-57.
- NEVILLE, B. G. 1972. The origin of infantile spasms: evidence from a case of hydranencephaly. *Dev Med Child Neurol*, 14, 644-7.
- OOSTENVELD R, F. P., MARIS E, SCHOFFELEN JM. 2011. FieldTrip: open source software for advanced analysis of MEG, EEG, and invasive electrophysiological data. *Computational Intelligence and Neuroscience*

- PANAYIOTOPOULOS, C. P. 2005. Epileptic Encephalopathies in Infancy and Early Childhood in Which the Epileptiform Abnormalities May Contribute to Progressive Dysfunction. In: PANAYIOTOPOULOS, C. P. (ed.) *The Epilepsies, Seizures, Syndromes and Management*. 2010/09/08 ed. Oxfordshire (UK): Bladon Medical Publishing.
- RANDO, T., BARANELLO, G., RICCI, D., GUZZETTA, A., TINELLI, F., BIAGIONI, E., LA TORRE, G., EPIFANIO, R., SIGNORINI, S., FAZZI, E., MERCURI, E., CIONI, G. & GUZZETTA, F. 2005. Cognitive competence at the onset of West syndrome: correlation with EEG patterns and visual function. *Dev Med Child Neurol*, 47, 760-5.
- ROSENBERG JR, A. A., BREEZE P, BRILLINGER DR, HALLIDAY DM 1989. The Fourier approach to the identification of functional coupling between neuronal spike trains. *Progress in biophysics and molecular biology*, 53, 1-31
- RUGGIERI, V., CARABALLO, R. & FEJERMAN, N. 1989. Intracranial tumors and West syndrome. *Pediatr Neurol*, 5, 327-9.
- SAMESHIMA, K. & BACCALA, L. A. 1999. Using partial directed coherence to describe neuronal ensemble interactions. *Journal of Neuroscience Methods*, 94, 93-103.
- SATOH, J., MIZUTANI, T. & MORIMATSU, Y. 1986. Neuropathology of the brainstem in age-dependent epileptic encephalopathy--especially of cases with infantile spasms. *Brain Dev*, 8, 443-9.
- SCHACK, B., HESSE, W., MOLLER, E. & ARNOLD, M. 2003. The use of time-variant EEG Granger causality for inspecting directed interdependencies of neural assemblies. *Journal of Neuroscience Methods*, 124, 27-44.
- SCHELTER, B., TIMMER, J. & EICHLER, M. 2009. Assessing the strength of directed influences among neural signals using renormalized partial directed coherence. *J Neurosci Methods*, 179, 121-30.
- SCHNEIDER, T. & NEUMAIER, A. 2001. Algorithm 808: ARfit—A Matlab package for the estimation of parameters and eigenmodes of multivariate autoregressive models. *ACM transactions on Mathematical software*, 27, 58-65.
- SCHNITZLER, A., TIMMERMANN, L. & GROSS, J. 2006. Physiological and pathological oscillatory networks in the human motor system. *J Physiol Paris*, 99, 3-7.
- SCHOFFELEN, J. M., OOSTENVELD, R. & FRIES, P. 2008. Imaging the human motor system's beta-band synchronization during isometric contraction. *Neuroimage*, 41, 437-47.
- SINIATCHKIN, M., GROENING, K., MOEHRING, J., MOELLER, F., BOOR, R., BRODBECK, V., MICHEL, C. M., RODIONOV, R., LEMIEUX, L. & STEPHANI, U. 2010. Neuronal networks in children with continuous spikes and waves during slow sleep. *Brain*, 133, 2798-813.
- SINIATCHKIN, M., VAN BAALEN, A., JACOBS, J., MOELLER, F., MOEHRING, J., BOOR, R., WOLFF, S., JANSEN, O. & STEPHANI, U. 2007. Different neuronal networks are associated with spikes and slow activity in hypsarrhythmia. *Epilepsia*, 48, 2312-21.
- SUDMEYER, M., SALEH, A., WOJTECKI, L., COHNEN, M., GROSS, J., PLONER, M., HEFTER, H., TIMMERMANN, L. & SCHNITZLER, A. 2006. Wilson's disease tremor is associated with magnetic resonance imaging lesions in basal ganglia structures. *Mov Disord*, 21, 2134-9.
- TASS, P., ROSENBLUM, M. G., WEULE, J., KURTHS, J., PIKOVSKY, A., VOLKMANN, J., SCHNITZLER, A. & FREUND, H. J. 1998. Detection of n : m phase locking from noisy data: Application to magnetoencephalography. *Physical Review Letters*, 81, 3291-3294.
- TAYLOR, F. M. 1952. Myoclonic seizure in infancy and childhood. *Tex State J Med*, 48, 647-9.

- TIMMERMANN, L., GROSS, J., BUTZ, M., KIRCHEIS, G., HAUSSINGER, D. & SCHNITZLER, A. 2003a. Mini-asterixis in hepatic encephalopathy induced by pathologic thalamo-motor-cortical coupling. *Neurology*, 61, 689-92.
- TIMMERMANN, L., GROSS, J., DIRKS, M., VOLKMANN, J., FREUND, H. J. & SCHNITZLER, A. 2003b. The cerebral oscillatory network of parkinsonian resting tremor. *Brain*, 126, 199-212.
- UTHMAN, B. M., REID, S. A., WILDER, B. J., ANDRIOLA, M. R. & BEYDOUN, A. A. 1991. Outcome for West syndrome following surgical treatment. *Epilepsia*, 32, 668-71.
- VACCA, G., DE FALCO, F. A., NATALE, S., DEL GIUDICE, E., ROMANO, A., LATTE, F. & BIANCHI, L. 1992. EEG findings in West syndrome a follow-up of 20 patients. *Acta Neurol (Napoli)*, 14, 297-303.
- VAN VEEN, B. D., VAN DRONGELEN, W., YUCHTMAN, M. & SUZUKI, A. 1997. Localization of brain electrical activity via linearly constrained minimum variance spatial filtering. *IEEE Trans Biomed Eng*, 44, 867-80.
- VIGEVANO, F., FUSCO, L. & PACHATZ, C. 2001. Neurophysiology of spasms. *Brain Dev*, 23, 467-72.
- VOLKMANN, J., JOLIOT, M., MOGILNER, A., IOANNIDES, A. A., LADO, F., FAZZINI, E., RIBARY, U. & LLINAS, R. 1996. Central motor loop oscillations in parkinsonian resting tremor revealed by magnetoencephalography. *Neurology*, 46, 1359-1370.
- VULLIEMOZ, S., THORNTON, R., RODIONOV, R., CARMICHAEL, D. W., GUYE, M., LHATOO, S., MCEVOY, A. W., SPINELLI, L., MICHEL, C. M., DUNCAN, J. S. & LEMIEUX, L. 2009. The spatio-temporal mapping of epileptic networks: combination of EEG-fMRI and EEG source imaging. *Neuroimage*, 46, 834-43.
- WENZEL, D. 1987. Evoked potentials in infantile spasms. *Brain Dev*, 9, 365-8.
- WEST, W. 1841 On a peculiar form of infantile convulsions *Lancet* 1, 724-5.
- WYLLIE, E., COMAIR, Y., RUGGIERI, P., RAJA, S. & PRAYSON, R. 1996b. Epilepsy surgery in the setting of periventricular leukomalacia and focal cortical dysplasia. *Neurology*, 46, 839-41.
- WYLLIE, E., COMAIR, Y. G., KOTAGAL, P., RAJA, S. & RUGGIERI, P. 1996a. Epilepsy surgery in infants. *Epilepsia*, 37, 625-37.
- ZHANG, Z. 1995. A Fast Method to Compute Surface-Potentials Generated by Dipoles within Multilayer Anisotropic Spheres. *Physics in Medicine and Biology*, 40, 335-349.

9. ACKNOWLEDGMENT

I would like to express a special gratitude to my supervisor Prof. Stephani. I am particularly obliged to Prof. Stephani for being confident in me and giving me an opportunity to work in the research group - Pediatric Brain Imaging, Department of Neuropediatrics, Christian-Albrechts-Universität Kiel and for providing me with extremely interesting and innovative topics of research, which gave me an insight into the fascinating field of functional brain imaging. I deeply appreciate his patient guidance, and willingness to give me valuable and constructive suggestions during the planning and development of this research work.

I would like to thank the head of our research group Prof. Siniatchkin for his support, enthusiastic encouragement, constructive suggestions and assistance for the progress of the research.

My special gratitude goes to Prof. Nana Tatishvili, who has been my mentor for the past years.

I wish to express my thanks to Dr. Moeller, whose useful critiques, advices and assistance were of great help for the proper conduction of the study.

I would like to express my special appreciation to Dr. Muthuraman Muthuraman for conducting the DICS and RPDS analysis and for his valuable contribution for the progression of this research work.

Special thanks to my fellow employees for their support and assistance.

The funding was provided by Deutsche Forschungsgemeinschaft (DFG). The study was conducted in the frames of D3 subproject of Sonderforschungsbereich (SFB) 855: The time series analysis for the improvement of the exact localization of generators of epileptic activity using magnetoencephalography (MEG) - and electroencephalography (EEG) data.

10. CURRICULUM VITAE

Curriculum of Research	
Personal Data	
Name	Natia Japaridze
Affiliation	UK-SH, Campus Kiel
Institute/Department	Department of Neuropediatrics, Christian-Albrechts-Universität Kiel
Address	Düsternbrooker Weg 150, 24105 Kiel
Phone	+49-0152 51936790
Fax	+49-431-597 1769
E-mail	n.japaridze@pedneuro.uni-kiel.de
Education/Training	
1998-2004	Medical Studies, State Medical University, Tbilisi, Georgia
2004-2008	Pediatric Residency Training Program at 'M. Iashvili Children's Central Hospital', Tbilisi, Georgia
2007	Visiting scholar at Department of Neuropediatrics, Ospedale Pediatrico Bambin Gesù, Rome, Italy
2009	ILAE – VIREPA Distance Education. EEG in the diagnosis & management of epilepsy
2010	Visiting scholar at Department of Neuropediatrics, Ospedale Bambin Gesù, Rome, Italy
Since 2009	Pediatric Neurologist at Department of Pediatric Neurology and Psychiatry, M. Iashvili Children's Central Hospital, Tbilisi, Georgia
Since November 2010	PhD student, Research Group - Pediatric Brain Imaging. Department of Neuropediatrics, Christian-Albrechts-Universität Kiel.