

der Klinik für Herz-und Gefäßchirurgie
Direktor: Prof. Dr. med. Georg Lutter
im Universitätsklinikum Schleswig-Holstein, Campus Kiel
an der Christian-Albrechts-Universität zu Kiel

**PERCUTANEOUS MITRAL VALVED STENT IMPLANTATION:
AN IN VITRO STUDY**

Inauguraldissertation
zur
Erlangung der Doktorwürde
der Medizinischen Fakultät
der Christian-Albrechts-Universität zu Kiel

vorgelegt von
Huangdong Dai
aus Shanghai, Volksrepublik China

Kiel 2013

Parts of this work have been accepted as a presentation on the 42nd Annual Meeting of the German Society for Thoracic and Cardiovascular Surgery (DGTHG) in February 2013:

1. **Dai H**, Marczynski-Bühlow M, Sarrahs B, Metzner A, Cremer J, Lutter G. (2013) Percutaneous mitral valved stent implantation: First in vitro prototype testing.
2. Pokorny S, Hettich H, Bähr T., **Dai H**, Marczynski-Bühlow M, Sattler B, Cremer J, Lutter G. (2013) Transapical mitral valved stent implantation: Computed tomographic comparison.
3. Huenges K, Pokorny S, Bähr T, Bönke F, **Dai H**, Cremer J, Lutter G. (2013) Off-pump mitral valved stent implantation guided by Real-Time 3D-Transesophageal Echocardiography.

1. Berichterstatter: Prof. Dr. Georg Lutter

2. Berichterstatter: Priv.-Doz. Dr. med. Christoph Langer

Tag der mündlichen Prüfung: 10.07.2013

Zum Druck genehmigt, Kiel, der Medizinischen Fakultät der Christian-Albrechts-Universität zu

Kiel am 12.07.2013

gez: Huangdong Dai

Abbreviations

PVL	Paravalvular Leakage
LVOT	Left Ventricular Outflow Tract
ASD	Atrial Septal Defects
VSD	Ventricular Septal Defects

Contents

1 Background	1
1.1 Percutaneous valved stent implantation.....	1
1.2 Transcatheter mitral valved stent implantation.....	1
1.3 The Amplatzer™ occluder.....	3
1.4 The aim of this study.....	5
2 Materials and Methods	7
2.1 Materials.....	7
2.2 Reagents.....	7
2.3 Instruments.....	7
2.4 General procedural steps of percutaneous mitral valved stent implantation.....	7
2.5 Device development.....	8
2.5.1 Self-expandable nitinol stent.....	8
2.5.2 Femoral vein-apex guide wire track establishment system.....	9
2.5.3 Storage and delivery system for the stent and the fixation tethers.....	12
2.5.4 Fixation tether capture system.....	18
2.5.5 The Amplatzer septal occluder and deployment of the occluder.....	22
2.5.6 Stent deployment and tensile test on the occluder.....	23
2.5.7 Apical access sheath unite.....	24
2.6 In vitro water circulation system and prototype test system.....	25
2.7 Prototype evaluation and optimization.....	27
2.8 In vitro test on the latest prototype.....	27
3 Results	29
3.1 Femoral vein-apex guide wire track establishment system.....	29
3.2 Storage and delivery system for the stent and the fixation tethers.....	30
3.3 Fixation tether capture system.....	32
3.4 Tensile test on the deployed occluder.....	34
3.5 In vitro overall evaluation of the latest prototype.....	34
4 Discussions	37
4.1 Self-expandable nitinol stent.....	37
4.2 Device development.....	38
4.2.1 Femoral vein-apex guide wire track establishment system.....	38
4.2.2 Storage and delivery system for the stent and the fixation tethers.....	38
4.2.3 Fixation tether capture system.....	42
4.3 The Amplatzer™ septal occluder.....	45
4.3.1 Occluder deployment.....	45
4.3.2 Tensile test on the deployed occluder.....	46
4.4 Stent deployment: push or pull?.....	47
4.5 In vitro tests on the prototype of the third generation.....	48
5 Summary	49
6 References	50
7 Appendix	52
8 Acknowledgements	52
9 Curriculum Vitae	53

1. Background

1.1 Percutaneous valved stent implantation

With the ageing of the population, more and more multimorbid old patients with heart valve disease will appear in the next decades. Minimally invasive interventions such as percutaneous valved stent implantation could become an alternative for them. Percutaneous valved stent implantation is the technique of a foldable heart valve that can be mounted on an expandable stent delivered percutaneously through standard catheter-based techniques and implanted within a diseased valve annulus (Lutter et al., 2004). In 1992, Andersen et al. reported on the first expandable valved stent implantation in a pig (Andersen et al., 1992). In the same year, Pavcnik et al. implanted a self-expanding caged-ball aortic valve into a dog's heart (Pavcnik et al., 1992). Since then, percutaneous valve implantation had been rapidly developed in the following decade. In 2000, Bonhoeffer et al. reported on their long term study of percutaneous pulmonary valve implantation in lambs. An expandable stent with bovine jugular vein valves was delivered antegradely through the jugular vein into the native pulmonary valve position (Bonhoeffer et al., 2000). The same research group was the first to perform percutaneous pulmonary valve implantation in human (Bonhoeffer et al., 2002). Different studies of percutaneous aortic valve implantation were reported by Lutter et al. (Lutter et al., 2002) and Boudjemline et al. (Boudjemline and Bonhoeffer 2002) in 2002. First percutaneous aortic valved stent implantation in human was performed on a 57 year old man with calcific aortic stenosis and no other treatment option by Cribier et al. in 2002 (Cribier et al., 2002). Subsequently, Cribier et al. reported 6 cases of percutaneous aortic valved stent implantation in patients with calcific aortic stenosis in 2004 (Cribier et al., 2004). To date, percutaneous pulmonary and aortic valved stent replacement has already developed into an alternative to conventional surgery in selected patients (Hernandez et al., 2012).

1.2 Transcatheter mitral valved stent implantation

In 2005, the feasibility of percutaneous tricuspid valved stent implantation was demonstrated by Boudjemline et al. (see Fig 1.1) (Boudjemline et al., 2005). In the same year, Ma et al. implanted the first self-expandable valved stent in mitral position via atrial access (see Fig 1.2) (Ma et al., 2005). But mild paravalvular leakage (PVL) and significant increase of mean transvalvular gradient and mean gradient across the left ventricular outflow tract (LVOT) were observed. In 2010, Bai et al. reported stent migration in their percutaneous tricuspid

valve implantation. In their study, the stent was anchored on the native annulus by its atrial and ventricular element (Bai et al., 2010) (see Fig 1.3). But challenges remain in this field. How to anchor the stent stably in the native mitral annulus? How to seal the gap between the stent and the native annulus? How to produce a stent with high foldability in order to minimize the size of the stent delivery catheter? Due to these problems, up to now, transcatheter mitral valved stent implantation has not been used clinically.

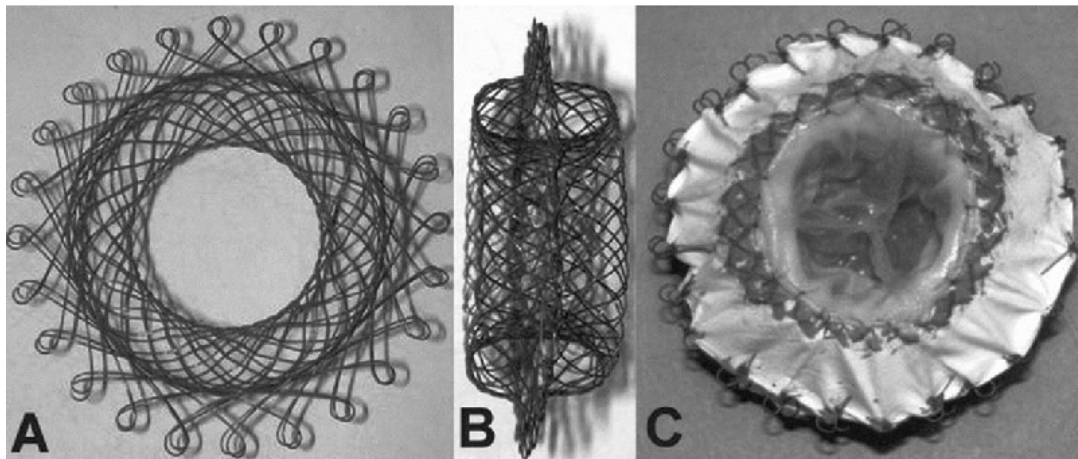


Fig 1.1 The tricuspid valved stent of Boudjemline's group; En face (A) and lateral (B) views of the newly designed stent before its covering, and after covering with a polytetrafluoroethylene membrane and mounting of a valve in the central tubular part (C). The stent is shown from the ventricular side with the valve closed (a picture excerpted from the article: *Steps toward the percutaneous replacement of atrioventricular valves.*) (Boudjemline et al., 2005).



Fig 1.2 The stent of Ma's group: The double-crowned valved stent. A porcine pulmonary valve has been sutured into a Dacron conduit. Then, two self-expandable nitinol Z-stents were sutured on the external surface of the prosthesis so that two self-expanding crowns were created for fixation (a picture excerpted from article: *Double-crowned valved stents for off-pump mitral valve replacement.*) (Ma et al., 2005).

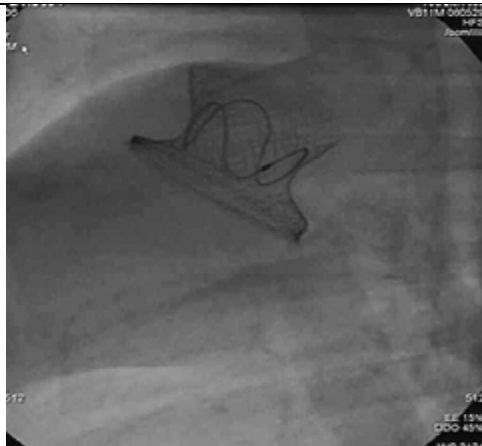


Fig 1.3 Left lateral view of the stent after implantation: The stent was embedded in the native annulus by the double disk structure (a picture excerpted from article: *An integrated pericardial valved stent special for percutaneous tricuspid implantation: an animal feasibility study.*) (Bai et al., 2010).

Recently, we reported our transapical tricuspid valved stent implantation with less PVL and a stable gradient (Iino et al., 2011). Our stent was anchored to the ventricular wall via four tethers attached to the ventricular column of the stent. A conventional button served as an anchorage for these tethers. The same stent fixation system was used in the study on transapical mitral valved stent implantation of our group (not yet published). In this study, our mitral valved stent and the stent fixation system were demonstrated to reduce PVL in an observation period of up to three months (see Fig 1.4) (not yet published).

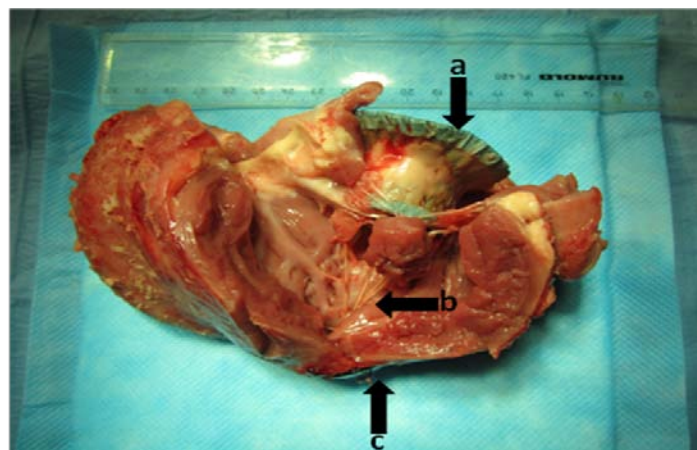


Fig 1.4 The stent (a) was anchored onto the apex by four tethers (b) and a conventional button(c).

1.3 The Amplatzer™ occluder

However, our transapical delivery system and ventricular fixation system required a small chest midline incision and ministernotomy (see Fig 1.5).

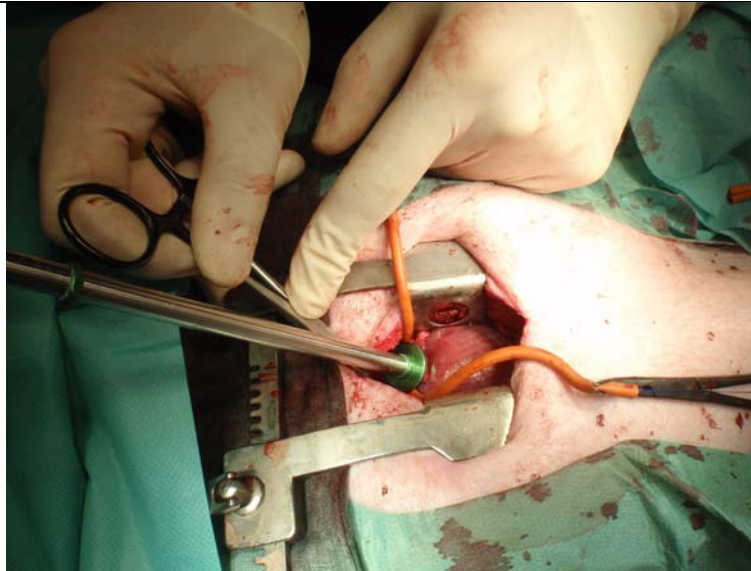


Fig 1.5 A midline incision should be done on the chest for stent delivery and fixation.

Fortunately, Tozzi et al. showed a sutureless closure of the left ventricular access in their publication in 2007 (Tozzi et al., 2007). They successfully used nitinol Amplatzer™ septal occluder to seal the defect on the left ventricle of porcine hearts (see Fig 1.6). In 2011, an American group closed puncture defects on the left ventricle of human hearts by Amplatzer™ occluder (Jelnin et al., 2011) (see Fig 1.7). This small deformable occluder can be deployed via a 10 Fr catheter. In this study, it could pose as an anchor point for the stent fixation. It made it possible to fix and anchor the stent transcatheterly.



Fig 1.6 The Amplatzer™ occluder used by Tozzi's group: Front view of a 12 mm Amplatzer™ occluder with the pericardial cuff on the ventricular side. The device is mounted into a sheath to simulate the deployment of a 25 mm stented valve. Its deployment is driven by a semi rigid wire (a picture excerpted from article: *Endoscopic off-pump aortic valve replacement: does the pericardial cuff improve the sutureless closure of left ventricular access?*) (Tozzi et al., 2007).

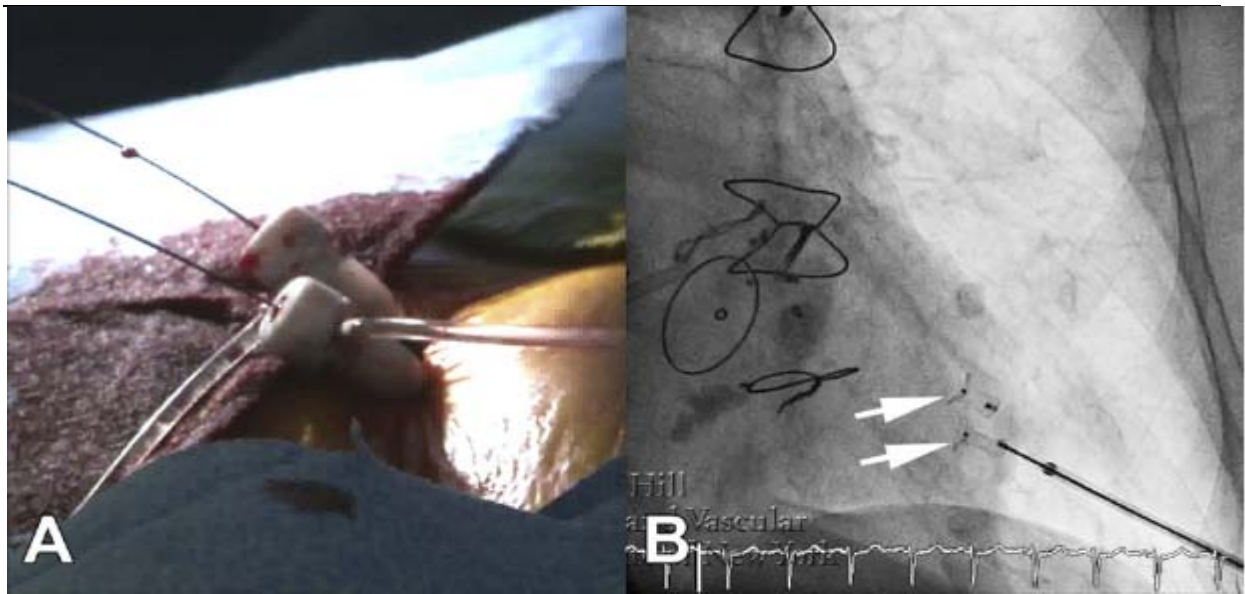


Fig 1.7 A: Double percutaneous transapical puncture. B: Deployment of 2 Amplatzer™ Duct Occluder devices closing a double puncture (white arrows) (a picture excerpted from article: *Clinical experience with percutaneous left ventricular transapical access for interventions in structural heart defects a safe access and secure exit.*) (Jelnin et al., 2011).

1.4 The aim of this study

At present, mitral valve disease is the second most popular heart valve disease in Europe. With the ageing of the population, more and more multimorbid old patients with mitral valve disease will appear in the next decades. For most of these patients, conventional surgical operation would not be the best option. Minimally invasive interventions could become an alternative for them. Up to now, no successful studies on non-invasive mitral valve replacement have been reported. In this study, we demonstrate the feasibility of percutaneous mitral valved stent implantation in vitro.

The transvenous-transseptal approach has been successfully used clinically for transcatheter valve-in-valve implantation in mitral position (Gurvitch et al., 2011) (Azadani and Tseng 2011). This study showed the feasibility of mitral valved stent implantation into the native mitral annulus via percutaneous transvenous-transseptal access.

The transapical mitral valved stent implantation of our research group demonstrated the feasibility of the button fixation unit. It effectively reduced PVL and the possibility of stent migration. But the conventional button is made of nondeformable material. A small chest midline incision and ministernotomy have to be performed for the deployment of the button unit and the closure of the apical defect. However, the studies on sutureless closure of left ventricular access indicated it is possible to use Amplatzer™ occluder for the occlusion of minimal defects on the left ventricle. Moreover, the disk-shaped occluder can serve as an anchor point for the stent fixation unit. Thus, only a percutaneous transapical puncture is

required for the deployment of the occluder.

If the stent and the occluder could be connected via these two percutaneous accesses, it would be possible to create a novel percutaneous mitral valved stent implantation system. In this thesis, a non-invasive transcatheter mitral valved stent implantation system will be presented and analyzed.

2. Materials and methods

2.1 Materials

Material	Manufacturer
One-Piece Angiographic Needle with Snap-on Wing, 50 mm	Cordis Europa N.V., LJ Roden, Holland
Pigtail Catheter, 5 Fr	Cordis Europa N.V., LJ Roden, Holland
Ballon Angiographic Catheter, 5 Fr	Teleflex Medical B.V., Hilversum, Holland
Teflon Wire, 0.035 Inch	Cordis Europa N.V., LJ Roden, Holland
Backup Wire, 0.035 Inch	Boston Scientific Corporation, Saint Paul, MN, USA
AndraSnare, AS-20, 4 Fr	Andramed GmbH, Reutlingen, Germany
Reusable Rat Tooth Grasping Forceps	Olympus Corporation, Tokyo, Japan
Ascendra Introducer Sheath Set, 14 Fr	Edwards Lifesciences LLC, Irvine, CA, USA
Ascendra Introducer Sheath Set, 24 Fr	Edwards Lifesciences LLC, Irvine, CA, USA
ETHICON [®] PROLENE [®] Polypropylen Surgical Suture, 5-0	Ethicon INC, Somerville, NJ, USA
Topline Polyester Surgical Suture, 2-0	HP-medica GmbH, Augsburg, Germany
Amplatzer [®] Septal Occluder	AGA Medical Corporation, Minneapolis, MN, Germany

2.2 Reagents

Reagent	Manufacturer
IMERON [®] 350 Contrast Agent	Brocco Imaging Deutschland GmbH, Konstanz, Germany

2.3 Instruments

Instrument	Manufacturer
Rotary Pump	Stöckert Instrumente GmbH, Munich, Germany
Olympus ViseRA CLV-S40 Endoscope System	Olympus Corporation, Tokyo, Japan
Philips Biplane DCI Digital Angiography System	Philips Medical Systems Nederland B.V., Eindhoven, Holland

2.4 General procedural steps of percutaneous mitral valved stent implantation

The first and most important step of this system development was the establishment of the “femoral vein-septum-apex guide wire track”. All the following procedural steps were performed along this track. The stent and the fixation tethers were loaded and crimped into a tubular stent delivery system. This system was advanced into the left ventricle percutaneously

and transseptally. Then the tethers were captured and pulled out of the chest transapically. Thus, with these tethers, the operator was able to deploy the stent and anchor it onto the apex. The guide wire and the tethers were threaded through the occluder which was subsequently pushed along the guide wire track and deployed in the ventricle apex later. After the stent has been deployed by pulling the tethers, the guide wire track can be removed. And so the main procedure of non-invasive percutaneous mitral valved stent implantation was finished.

2.5 Device development

In this study, we designed and developed three generations of percutaneous mitral valved stent implantation systems. These three generations had essentially the same procedural steps. But the specific details of each step were quite different. For better understanding, we divided this implantation system into six parts:

1. Self-expandable nitinol stent
2. Femoral vein-apex guide wire track establishment system
3. Stent storage and delivery system
4. Tethers capture system
5. Occluder and fixation system
6. Deployment of the stent

2.5.1 Self-expandable nitinol stent

The stent was designed by our group for the mitral position (see Fig 2.1). It consisted of two parts: a flat orbicular atrial fixation element, a tubular ventricular element. These two elements inclined at an angle of 110° . Three tethers (75 mm) were connected to the bottom of the ventricular element. The atrial and ventricular elements had diameters of 35 mm and 28 mm, respectively. For the first in vitro experiment, the stent was non-valved.

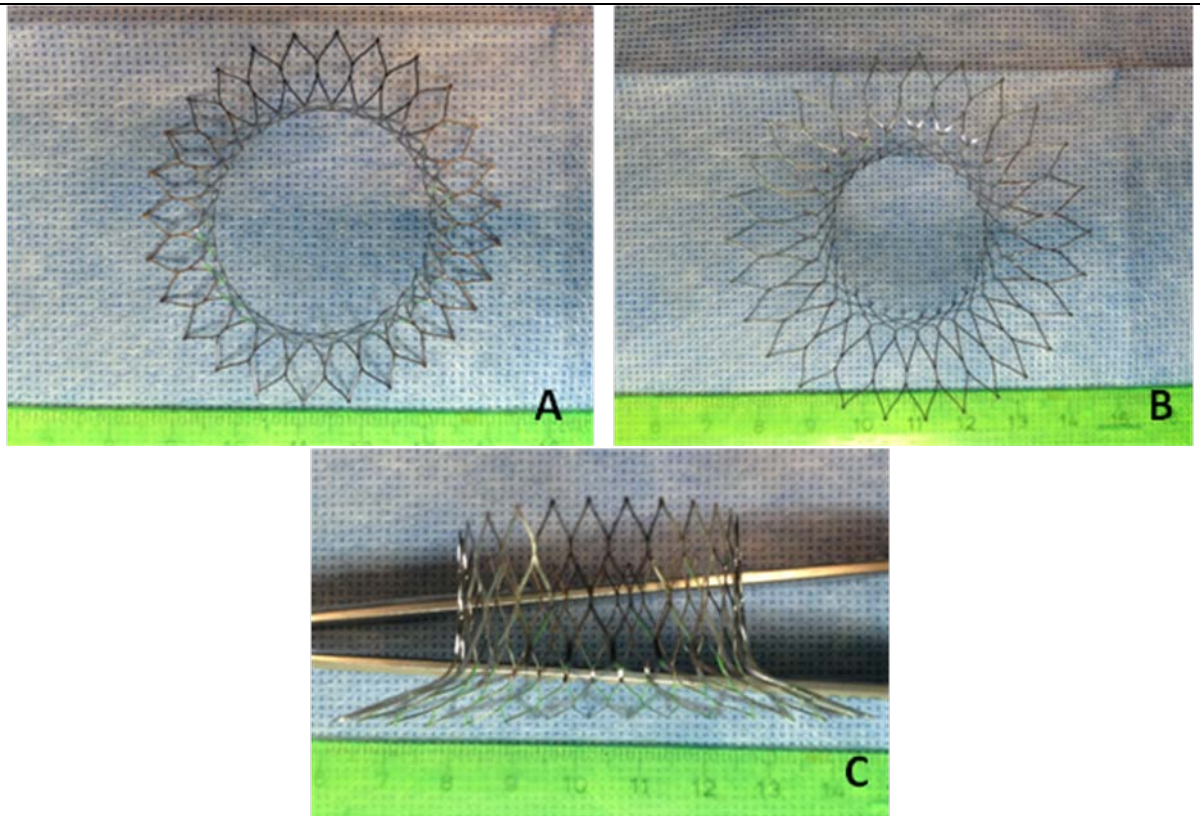


Fig 2.1 A: Top view of the stent; B: Bottom view of the stent; C: Side view of the stent.

2.5.2 Femoral vein-apex guide wire track establishment system

The first step in this in vitro experiment was to undergo transapical puncture and subsequently insert a 10 Fr apical access sheath into the left ventricle (see Fig 2.2). Afterwards, a venous balloon catheter was delivered into the left ventricle via the left atrium. Two different systems were used and developed to catch the balloon catheter within the left ventricle and to pull it out of the heart via the apical access sheath. Thus, the track for delivering the stent can be established via replacing the balloon catheter by a stiff guide wire.

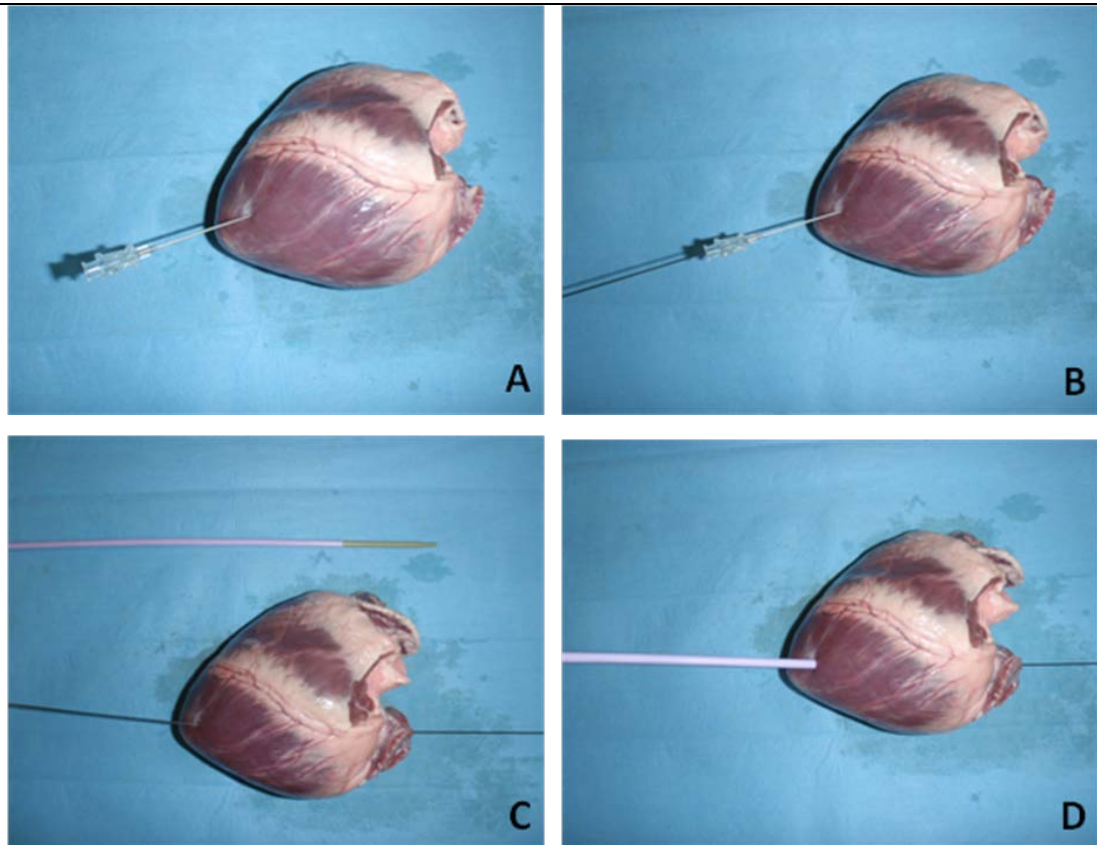


Fig 2.2 A: Transapical puncture was conducted by a puncture needle. B: A guide wire was inserted into the heart via the puncture needle. C, D: 10 Fr dilator and apical access sheath are guided along the guide wire and inserted into the left ventricle. Afterwards, the dilator and the guide wire were taken off.

First generation track establishment system: “magnets capture system”

This system included a venous balloon catheter and a transapical capture stick (see Fig 2.3). Both parts had a small magnet (2 mm in diameter and 1 mm in thickness) on the tip. Thus, the balloon catheter can be caught in the left heart by the magnet on the tip of the stick which was inserted into the heart transapically. After being towed into the apical puncture sheath, the balloon catheter can be easily pushed out of the chest along the transapical access sheath. Then, a vein-apex guide wire track system can be established by a stiff guide wire taking the place of the balloon catheter.

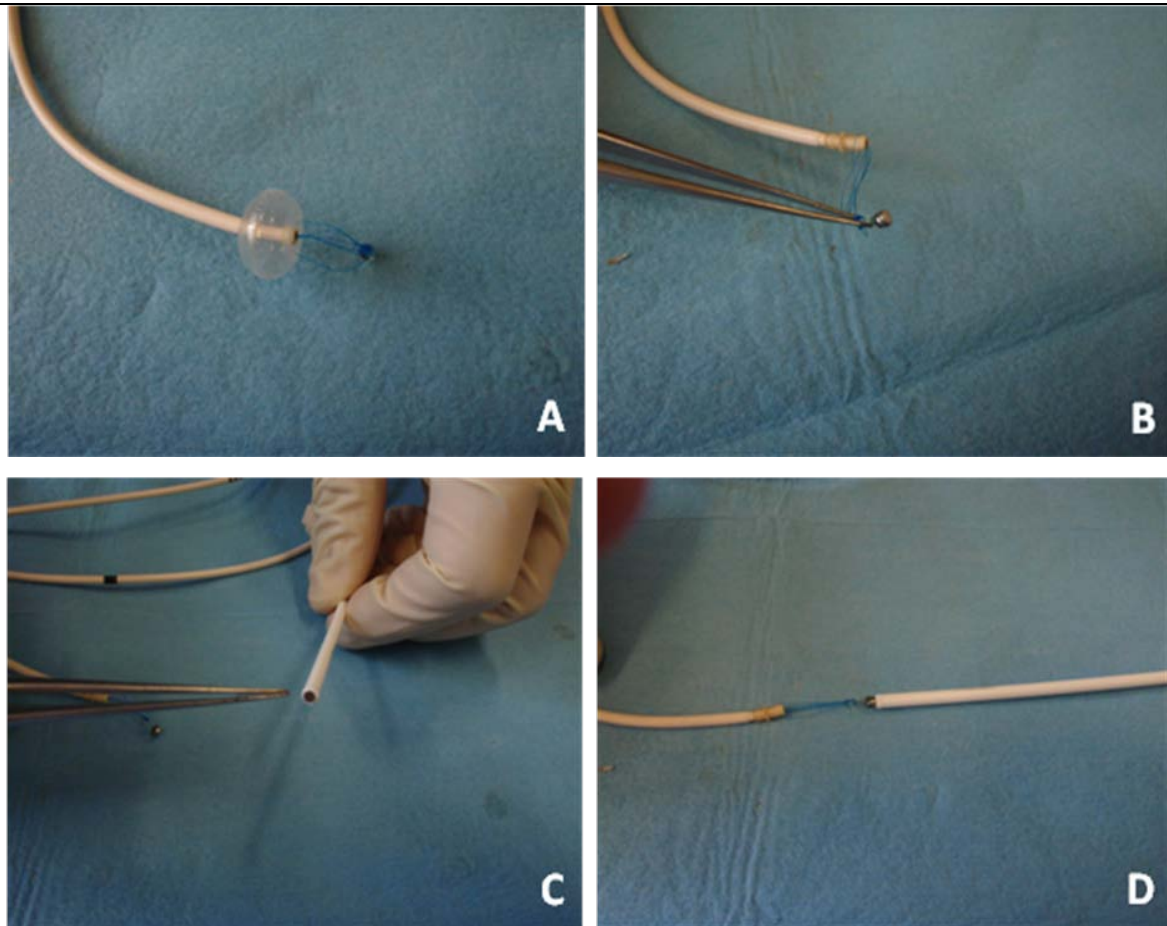


Fig 2.3 A, B: A tiny magnet (2 mm in diameter and 1 mm in thickness) was fixed onto the venous balloon catheter by 3-0 polypropylene sutures. C: A magnet of the same size was embedded into the tip of a 5 Fr plastic stick. D: The balloon catheter can be caught by magnetic force.

Second generation track establishment system: “snare capture system”

This device has already been commonly used in the field of cardiac interventions. In this study, we used this snare device to catch the soft guide wire which was introduced together with the balloon catheter into the left ventricle (see Fig 2.4). Afterwards the soft guide wire was pulled out of the chest transapically. Then the balloon catheter was pushed out of the heart along the soft guide wire. The soft guide wire was exchanged by a stiff one and, therefore, the same vein-apex guide wire track system was established as in the first prototype.

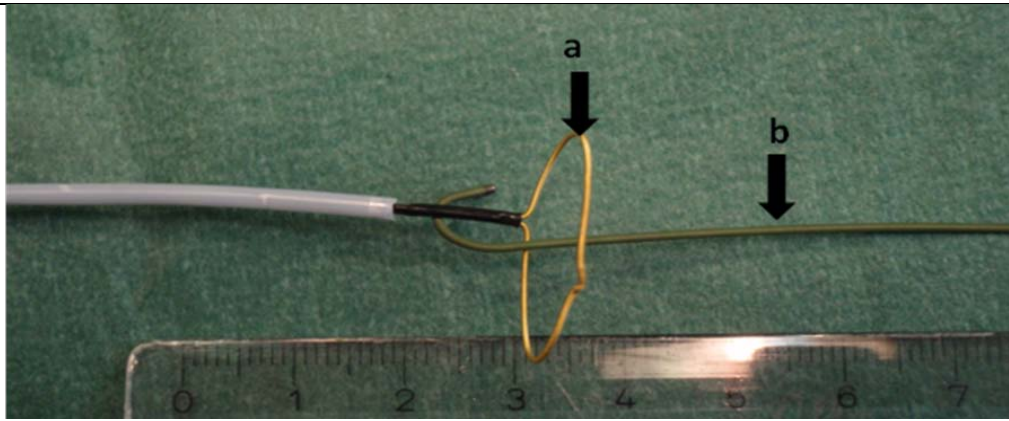


Fig. 2.4 The snare capture system (a: the snare ring; b: the wire with a soft tip).

2.5.3 Storage and delivery system for the stent and the fixation tethers

The function of this system was to store and deliver the stent as well as the fixation tethers. Main part of the system was a 14 Fr catheter. Though, during the development of this system, the tip of the catheter was changed into different structures. Three different prototypes were developed in this study.

The first generation stent delivery system

This system consisted of a 14 Fr sheath, a distal plug, a 14 Fr proximal cover (in this paper, the proximal end of the applicator is the end which is nearer to the heart during using), a 6 Fr conical tip and a center lumen catheter (0.035-inch inner diameter) (see Fig 2.5). The 14 Fr sheath was the main part of this system. The collapsed stent together with the tethers were stored herein. Three 75 cm length tethers were repeatedly folded into a 4 cm bundle and inserted into the sheath. The silicon cover served as a lid to keep the tethers inside the sheath and to allow a smooth guidance of the delivery system, especially very important for the transeptal penetration. A ‘Y’ shaped incision was done on the top of the cover in order to generate a flap-like opening which cannot be opened till the tension on the tethers was strong enough to pull the stent out. The conical tip was the key part of this system. There was one suture loop at each end of the tip. The proximal one was for the tethers capture system which will be introduced later. And the second one was connected to the fixation tethers (see Fig 2.6). A plug was fixed onto the distal end of the sheath and a center lumen catheter went throughout the whole system. This center lumen allowed the passage of the guide wire and sustained the conical tip (Fig 2.5 C). The tip can be easily detached from the center lumen catheter after being caught by the tethers capture system.

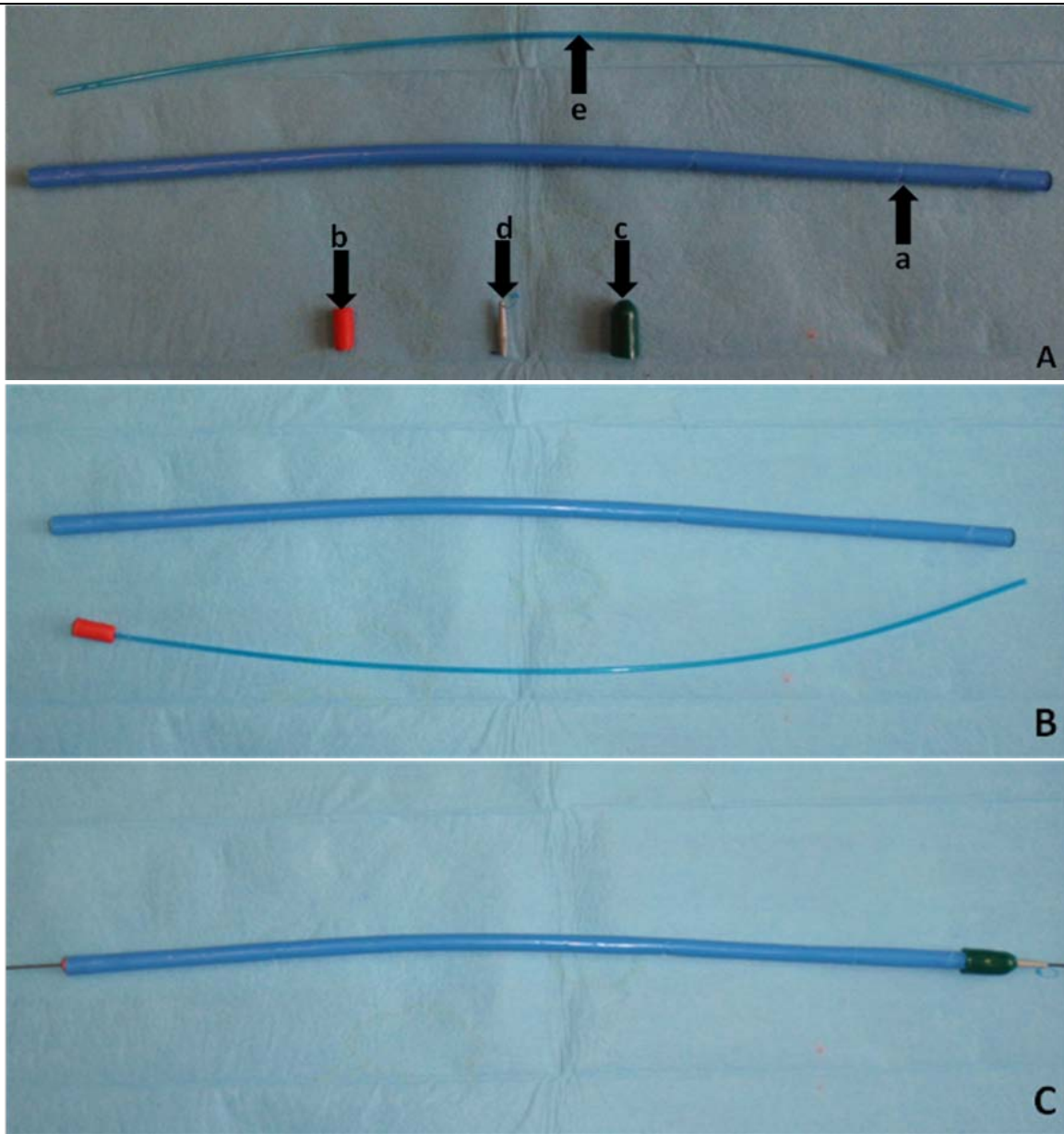


Fig 2.5 A: This system consisted of a 14 Fr sheath (a), a distal plug (b), a 14 Fr proximal cover (c), a 6 Fr conical tip (d) and a center lumen catheter (e). B, C: The distal plug and the center lumen catheter supported the conical tip and allowed the passage of the guide wire.

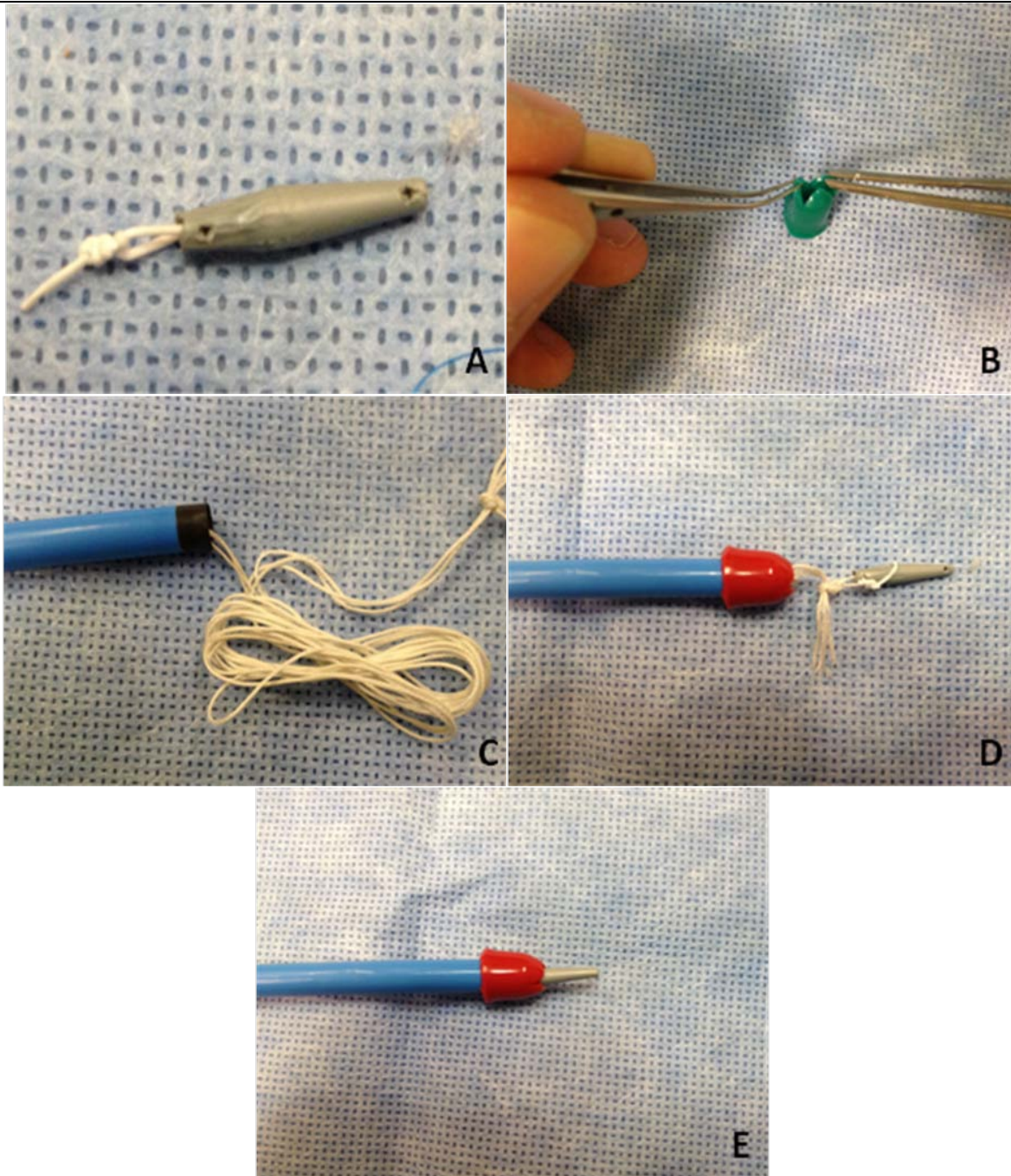


Fig 2.6 A: the conical tip with one loop at both ends. B: the silicon cover with a ‘Y’ shaped opening. C: The stent was collapsed and mounted into the storage catheter and the fixation tethers were folded into a bundle and stored herein. D: The ends of the tethers were connected with the distal loop of the conical tip. E: The stent storage and delivery catheter was sealed by the silicon cover and the conical tip.

The second generation stent delivery system

This generation was modified from a 14 Fr venous access sheath and dilator (see Fig 2.7). The dilator was cut into two parts, one small tip and one longer part serving as a pusher. These two parts were connected by a center lumen catheter (10 cm in length, 0.035-inch inner diameter) which was cut from a pigtail catheter. The stent was collapsed and loaded in the space

between the pusher and the tip (see Fig 2.8). The three tethers were wound upwards around the center lumen catheter like a triple helix upwards to the tip. Theoretically, due to this structure, the tethers occupy less space and can be smoothly and orderly pulled out from the sheath. In addition, in this prototype, an 8 mm tube which was also cut from the pigtail catheter (0.035-inch inner diameter) played the same role as the tip of the first generation system. Though, the small proximal loop was replaced by two longer loops connected to a magnet (2 mm in diameter and 1 mm in thickness) at the end. The distal loop was also prolonged (see Fig 2.8 B). This short tube was inserted into the channel on the proximal end of the tip and could be easily pulled out (see Fig 2.8 D). In a sense, this tube is also one part of the center lumen catheter. The loop on the distal end of the tube went down along the outside of the tip to the interior of the sheath and was connected with the three fixation tethers. The details of the utility of the top loops with the magnet will be presented in the “tethers capture” section.

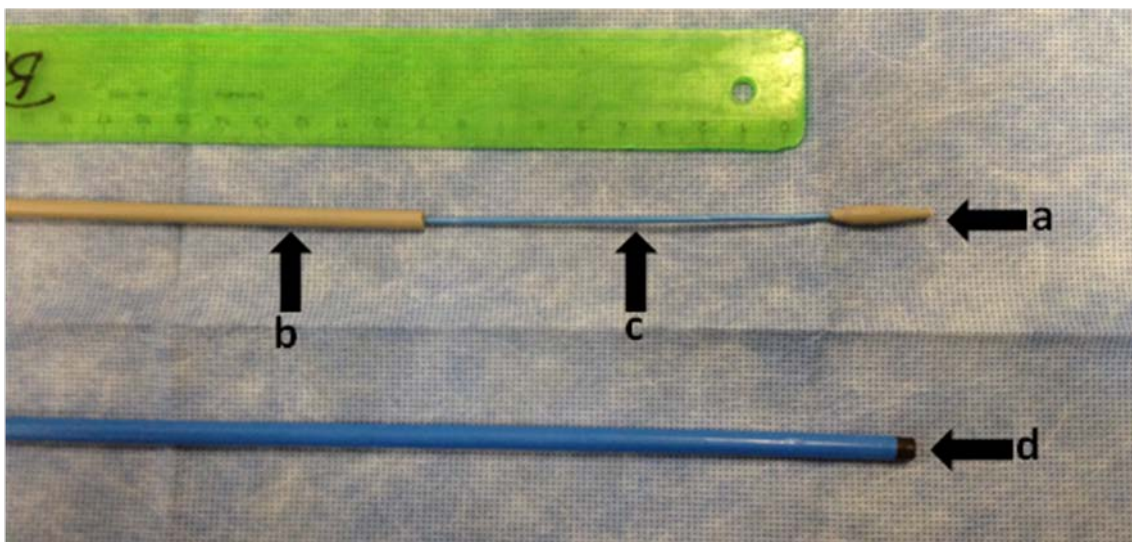


Fig 2.7 The dilator was cut into two parts, one small tip (a) and the other worked as the pusher (b). These two parts were connected by a center lumen catheter (c). d: the 14 Fr venous access sheath

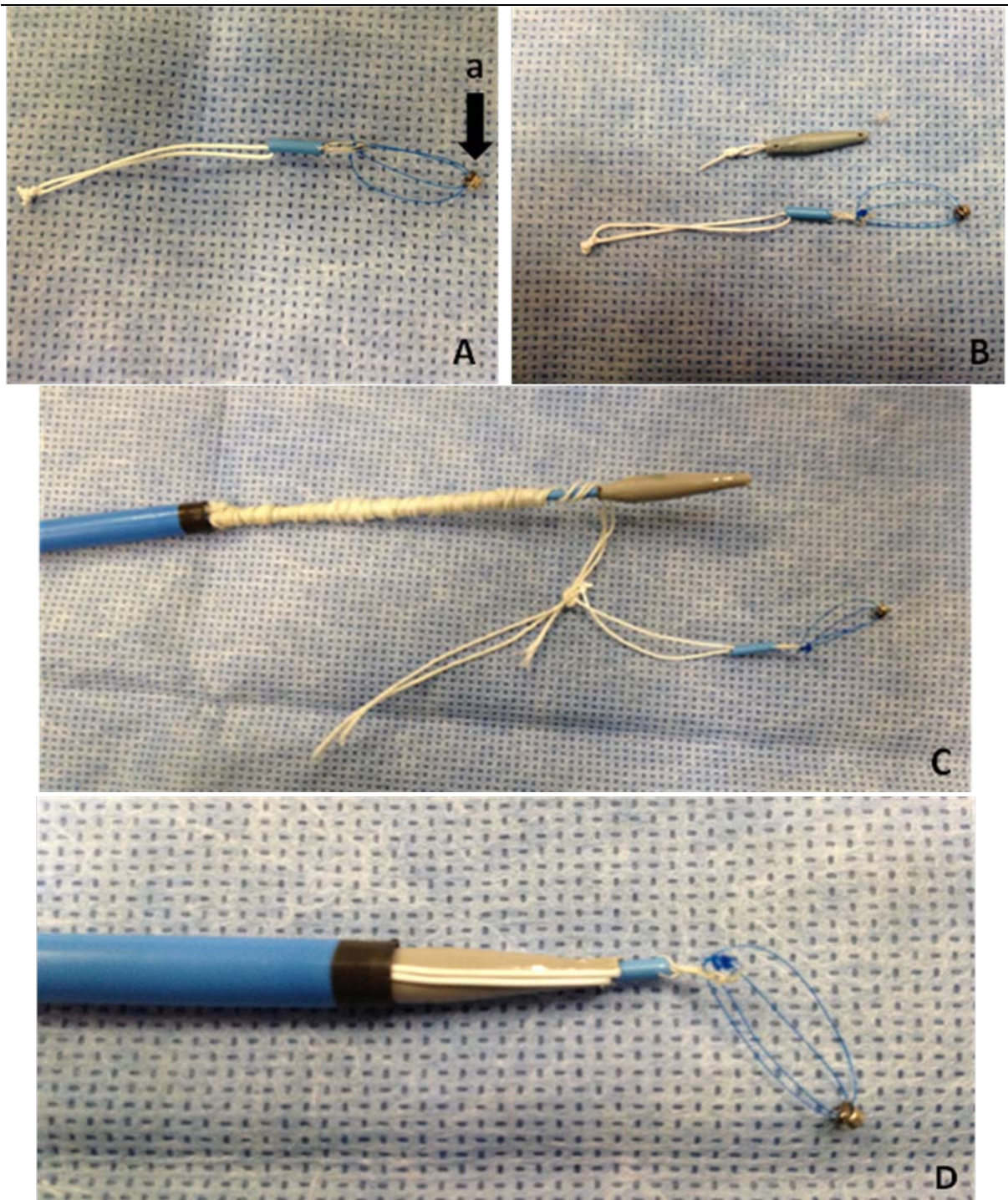


Fig 2.8 A: There was one suture loop at each end of the tip. A small magnet was fixed on the proximal loop (a). B: The distal loop was prolonged compare to that of the first generation. C: The three tethers wound upwards around the center lumen catheter like a triple helix up to the tip. D: The distal loop of the tube went down along the lateral surface of the tip till the interior of the storage sheath and, there, was connected with the three fixation tethers.

The third generation stent delivery system

The principal part of this prototype is the same as that of the second generation. But the 8 mm tube on the tip was replaced by a 35 cm center lumen catheter which was also cut from a pig tail catheter (0.035-inch inner diameter) (see Fig 2.9). This catheter did not contain any loop

or magnet. Though, there were three holes in the wall of its proximal side. Similarly, this center lumen catheter is separable as well. In this system, the collapsed stent was stored in the sheath. But the tethers were straightened and went upward along the conical tip till the tip of the center lumen catheter. There, they respectively passed through the three holes and then turned back (see Fig 2.10 A). Hence, the tethers were folded one time outside the sheath chamber along the separable lumen catheter. Afterwards, the lumen catheter and the tethers were totally ensheathed by a 37 cm soft dilator (10-Fr outer diameter, 6-Fr inner diameter). The lateral surface of the center lumen catheter and the medial surface of the soft dilator formed a tethers storage lumen (see Fig 2.10 B+C).

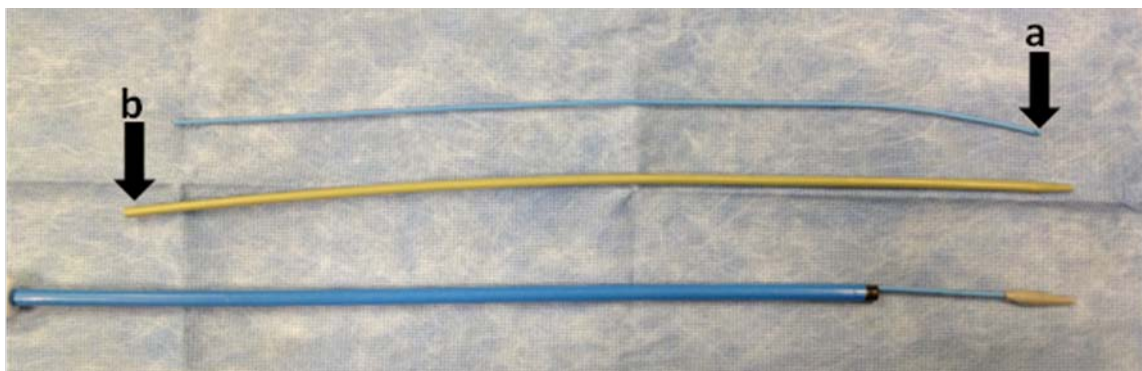


Fig 2.9 The principal part of the prototype of the third generation was the same as that of the second generation but the 8 mm tube was changed against a 35 cm one (a). A 37cm dilator was used (b).

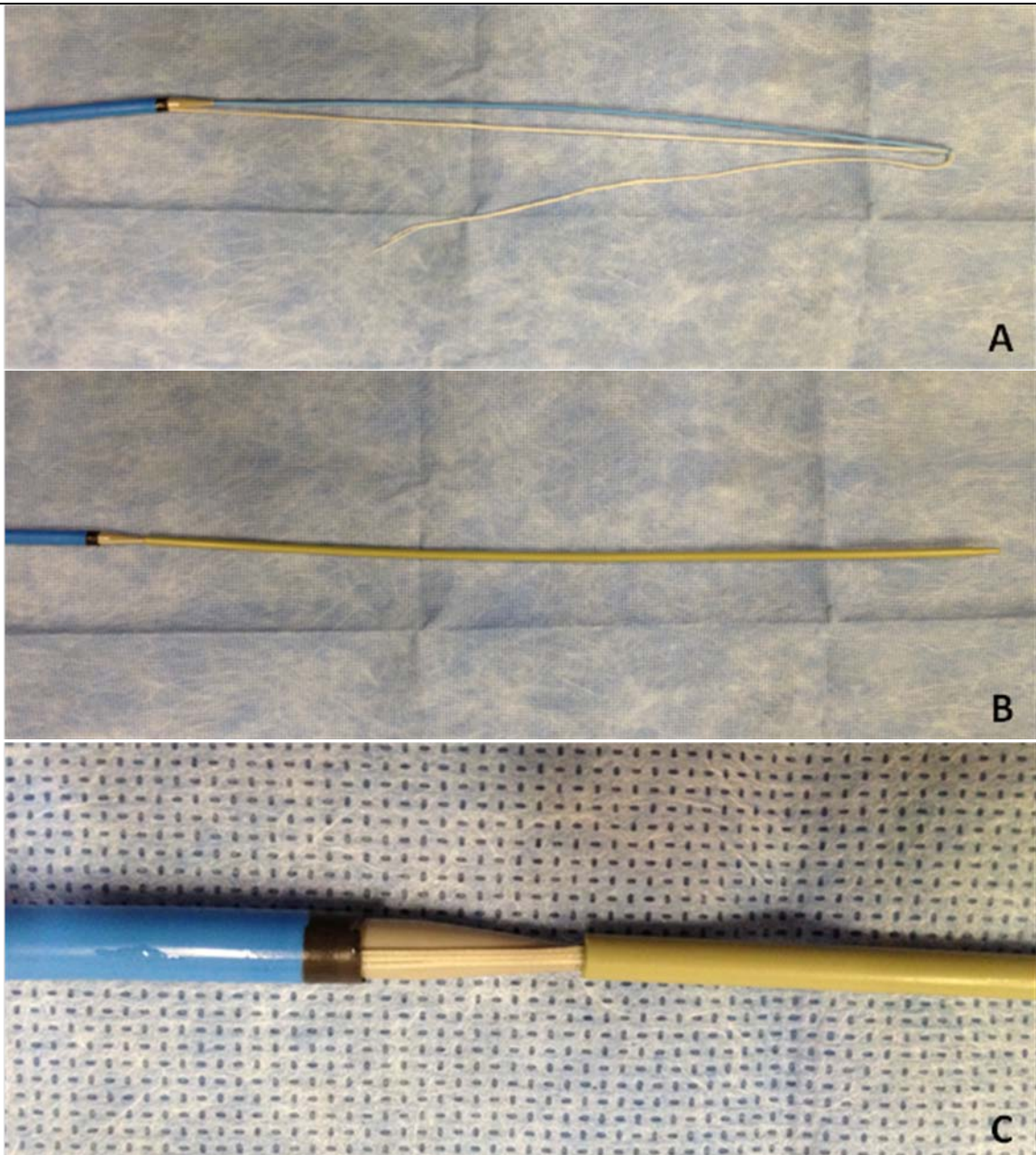


Fig 2.10 A: The tethers were folded along the center lumen. B, C: The tethers were mounted in the storage lumen.

2.5.4 Fixation tether capture system

After the stent and the fixation tethers were delivered into the left ventricle, the tethers should be captured and taken out of the chest transapically. The tethers played a very important role in the implantation procedure. They were not only the anchor of the stent, but also the only bridge connecting the stent and the operator. The following steps - including deployments of the occluder and the stent - were both conducted by using the tethers.

The first generation capture system: “hook-loop” system

As previously mentioned, our percutaneous mitral valved stent implantation system was based on a femoral vein-septum-apex guide wire track. For the establishment of this track, transvenous, transseptal and transapical punctures have to be performed. A vascular puncture sheath and a 10 French radial sheath were separately inserted into the femoral vein and into the apex for the following operations.

The first generation of stent delivery system was advanced along the track into the left ventricle cavity till the tip of it got into the 10 French apical access sheath (see Fig. 2.11 A). A stiff metal wire, one end of which had been bent into a hook, was used to grapple the loop on the tip and to pull it out transapically together with the fixation tethers which had been attached on the other side of the tip (see Fig. 2.11 B). Consequently, we were able to perform the next steps outside the body with these tethers.

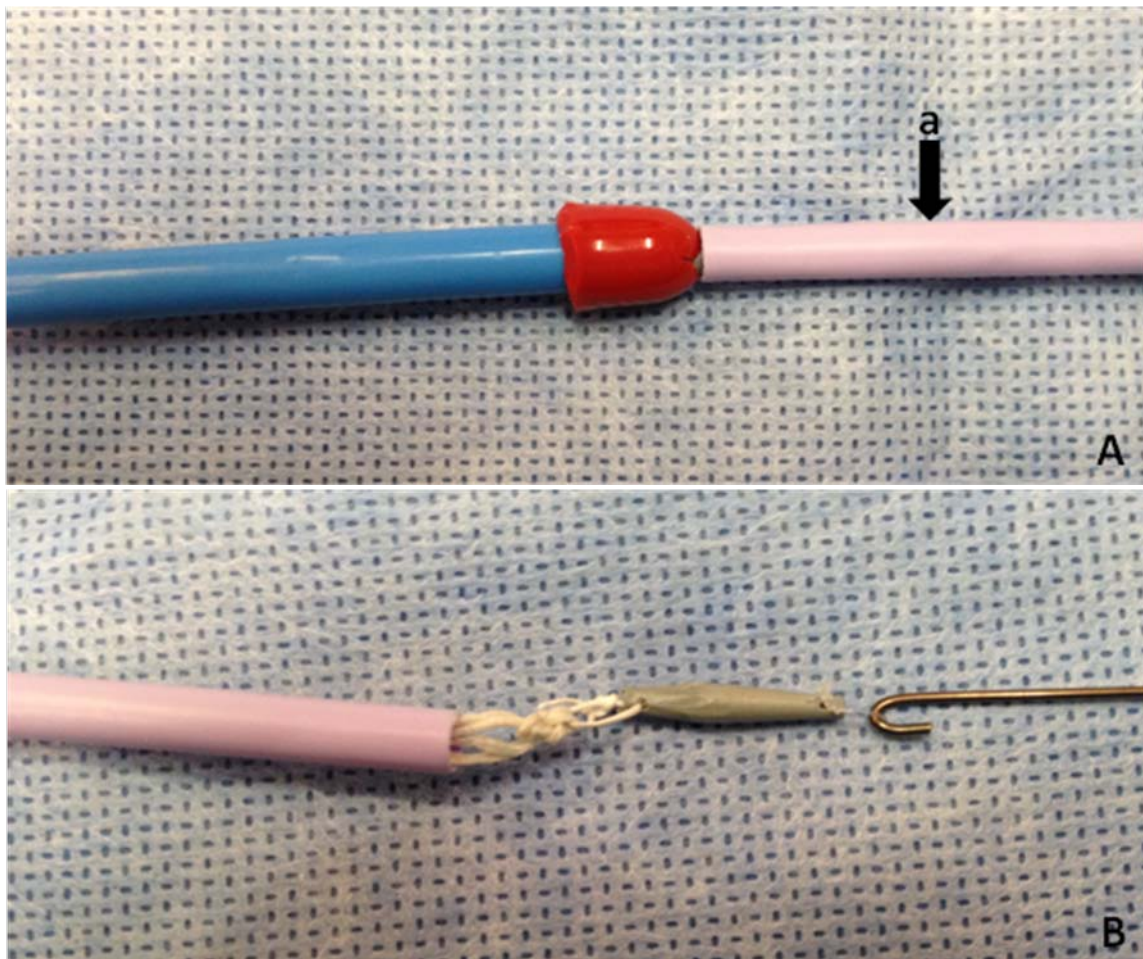


Fig 2.11 A: The tip was pushed into the apical access sheath. (a: the apical access sheath). B: The tip and the tethers were caught and pulled out of the sheath by the hook.

The second generation capture system: “forceps-magnet-loop” system

A reusable rat tooth grasping forceps, which was 2.8 mm in diameter, was used in this system (see Fig 2.12 A). The forceps was inserted into the left ventricle via the apical access sheath. When it met the stent delivery system in the ventricle cavity, a magnet on the tip of the delivery system guided the loops to the forceps (see Fig 2.12 B). It made the loops easily to be grasped by the forceps (see Fig 2.12 C). After being captured, the small tube with the tethers fixed on its end could be dragged out of the access sheath.

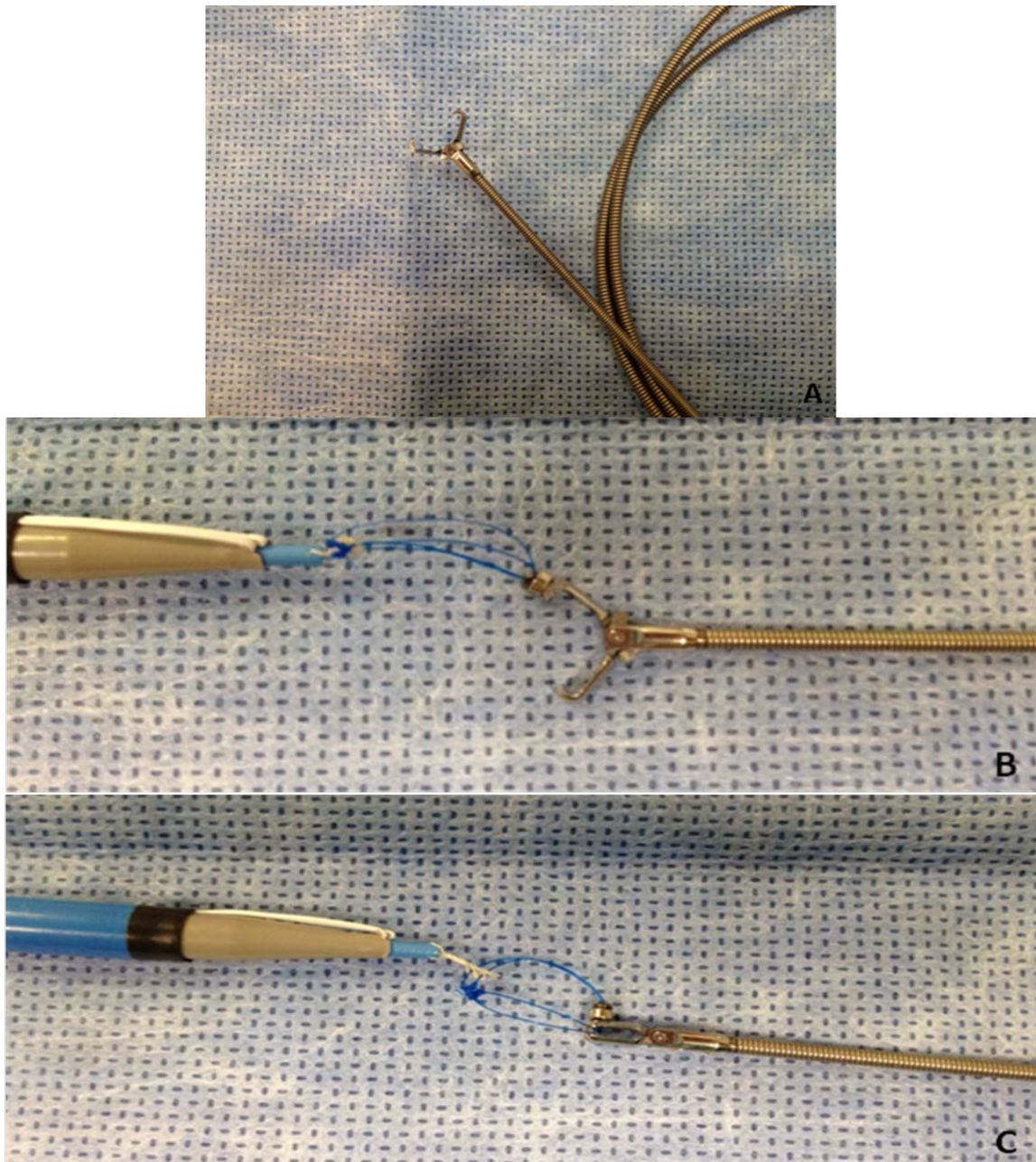


Fig 2.12 A: The rat tooth grasping forceps are commonly used in interventional operations. B: The small magnet was held down by the forceps. C: The forceps can easily catch the loop after being pushed a few millimeters forward.

The third generation capture system: “hand capture” system

The improvement of the tethers storage system made it possible to capture the tethers outside the heart. The 35 cm tethers storage lumen which has been described in the stent delivery section was long enough to pass through the apical access sheath (see Fig 2.13 A). After the tethers storage lumen being delivered transapically and exposed under direct vision, the dilator can be taken out by hands to expose the tethers (see Fig 2.13 B). Subsequently, the tethers were separated from the center lumen catheter. This catheter can also be removed from the stent delivery system (see Fig 2.13 C). All the above described steps can be performed by hands and under direct vision.

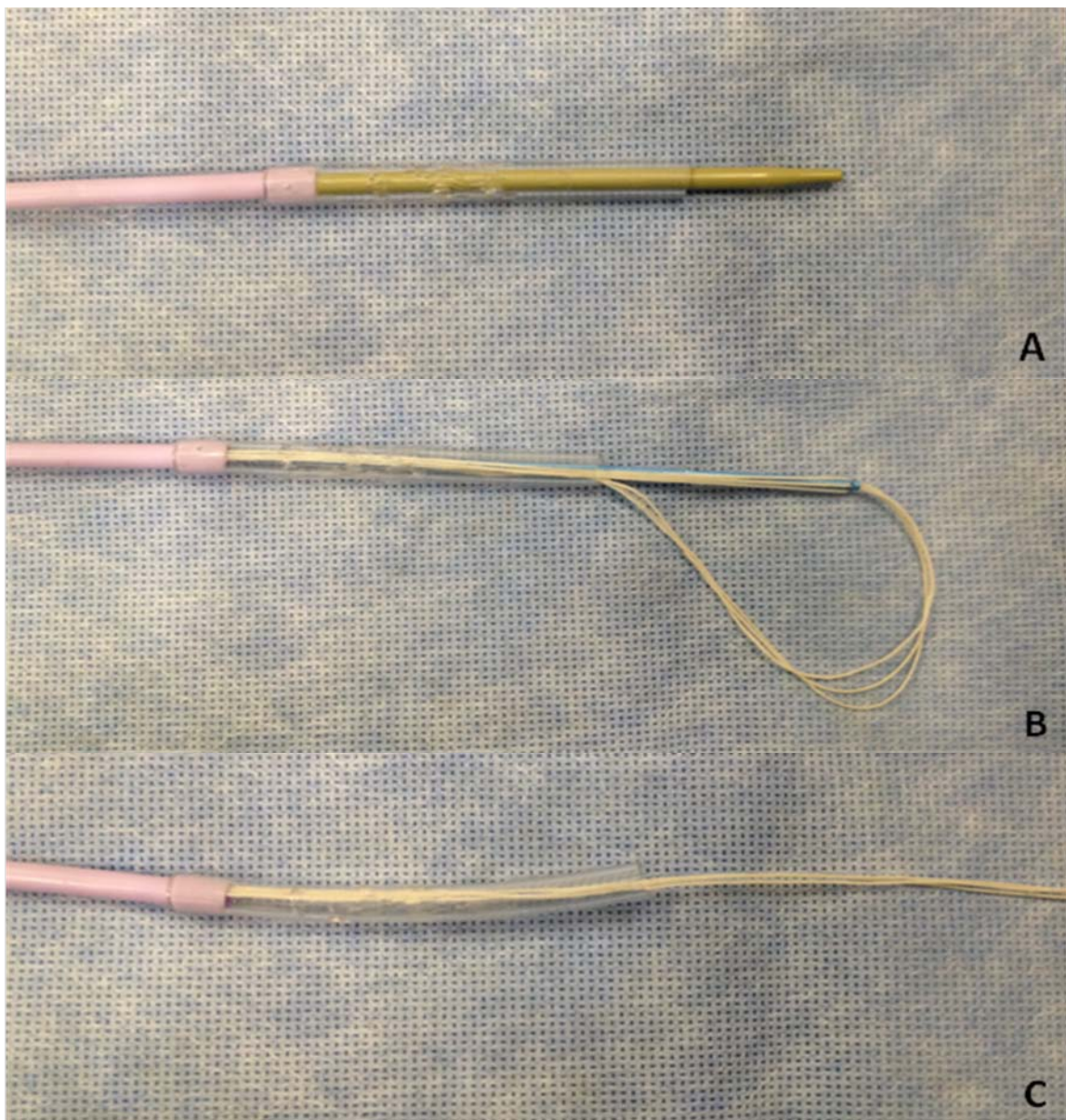


Fig 2.13 A: The fixation tethers storage lumen is longer than the apical access sheath and it can pass through the sheath. B: The tethers can be exposed under direct vision after taking the dilator off. C: The center lumen catheter was dismantled from the delivery system and the tethers were exposed completely.

2.5.5 The Amplatzer™ septal occluder and deployment of the occluder

The Amplatzer™ septal occluder is composed of two small disks of different sizes with a slim cylindrical middle waist (see Fig 2.14). The disks consist of a double-layer wire mesh made from Nitinol alloy. It is widely used to treat atrial septal defects (ASD) and ventricular septal defects (VSD). The occluder can be stretched in to a thin rod and delivered into the heart by transcatheter technique.

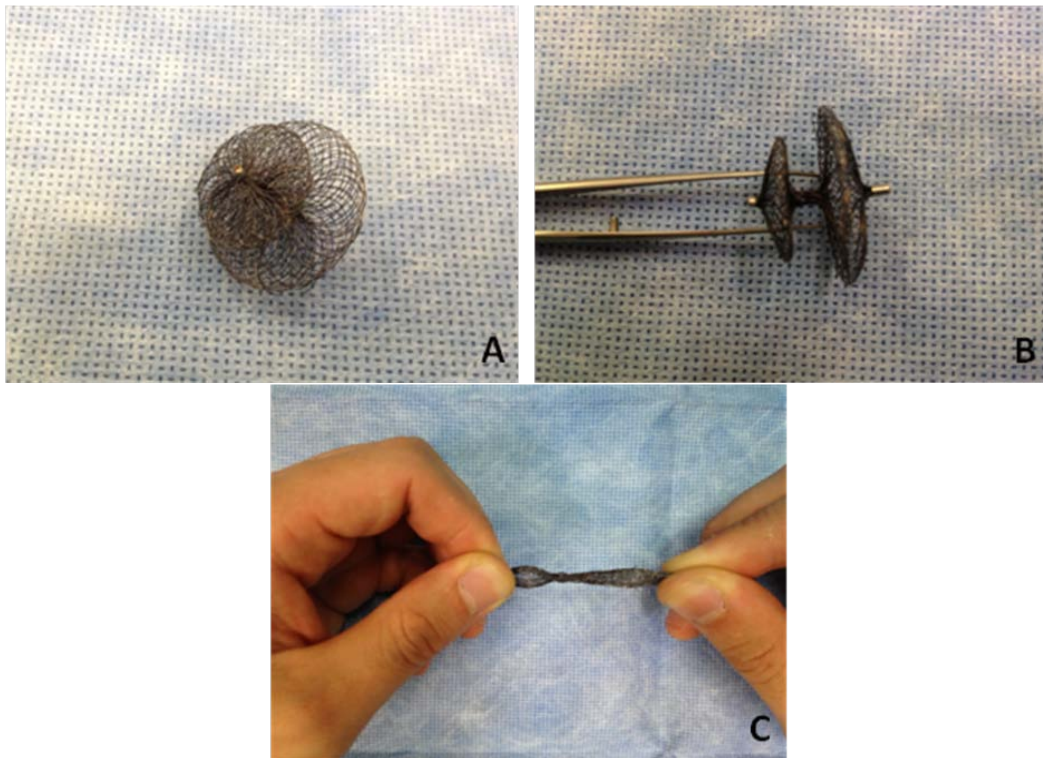


Fig 2.14 A, B: Amplatzer™ septal occluder. C: The occluder can be stretched into very thin diameter.

In our system, after the tethers capture, the Amplatzer™ occluder was threaded by the three fixation tethers and the guide wire (see Fig 2.15 A). The small disk faced towards the apex. Then the threaded occluder was pushed towards the apex through the apical access sheath (see Fig 2.15 B). The pushing was stopped when the distal part of the occluder got out of the sheath and expanded into a disk in the left ventricle (see Fig 2.15 C). Subsequently, the apical sheath was pulled back until being totally removed from the heart. Thus, the big disk expanded on the outer side of the apex and the deployment of the occluder was finished (see Fig 2.15 D). Throughout this process, the fixation tethers were pulled slightly to keep them straight. The smaller disk covered the inner side of the apical defect and the larger one covered the outer side, while the waist between the two discs plugged the hole.

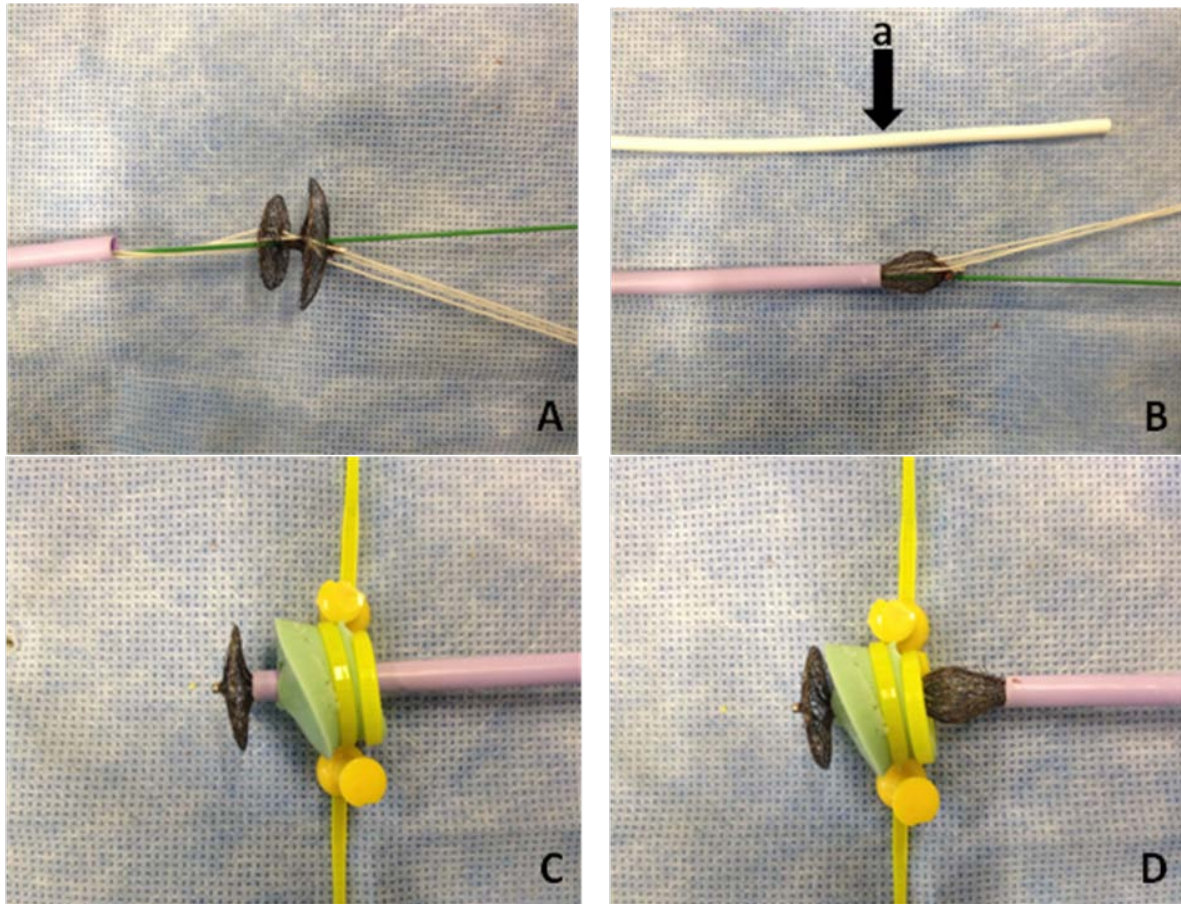


Fig 2.15 A: The three fixation tethers and the guide wire were thread through the occluder. B: The occluder was collapsed and loaded into the apical access sheath and pushed into the heart by a pusher (a). C, D: The pushing stopped when the distal part got out of the sheath, and then the apical sheath was pulled back till it was totally removed from the heart. (In these pictures, the apex was simulated by a small silicon pad.)

2.5.6 Stent deployment and tensile test on the occluder system

The performance of stent deployment followed the step of occluder deployment. This arrangement is going to be discussed in chapter 4 in more detail. In the first generation of stent storage and delivery system, we deploy the stent simply by pulling the tethers after moving the tip of the delivery system to the center of the mitral annulus. However, in the second and third generations, the tip which covered the opening of the system should be pushed around 1 cm forward to open the delivery catheter before stent deployment. In all of the three systems, the only motive force for the stent deployment was the tension on the three tethers. The propulsive force on the pusher simply acted on the tip for catheter opening. The guide wire track could be removed after the stent deployment. Then the main procedure of the stent implantation was finished.

In eight porcine hearts, tensile tests on the occluder were done after the stent deployment (see Fig 2.16). The minimum tension for pulling the occluder out of the apex was recorded.

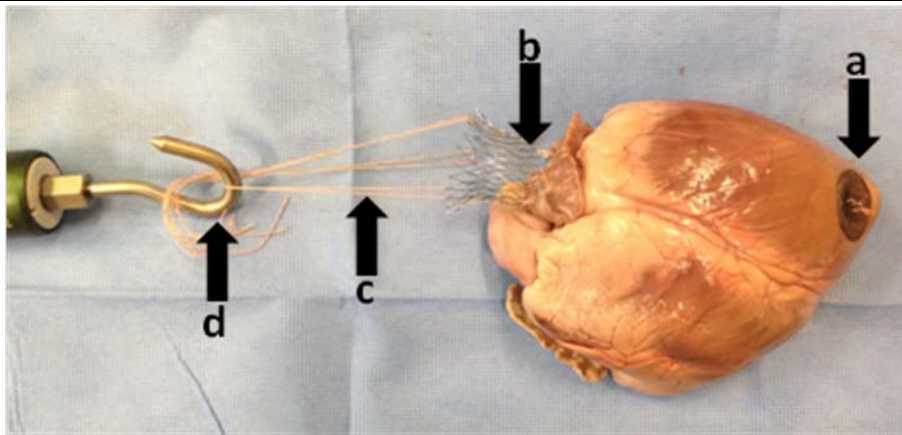


Fig 2.16 The stent (b) was connected with the Newton meter (d) by the three fixation tethers (c). The Newton meter was pulled until the occluder (a) was dragged out of the apex.

2.5.7 Apical access sheath unit

In this mitral valved stent implantation system, the apical access sheath played a very important role. Most of the steps were performed via this sheath. Devices of different sizes and shapes were pushed into or pulled out of the heart through this sheath. Furthermore, in future in vivo experiments, this sheath should also work as a blood stream blocker. Clinically, these kinds of sheath always have a valvular end to block the blood stream. Catheters with smooth and simple shape can go in and out the valvular end very easily. But in our systems, we used devices such as hooks, magnets and tethers. It was difficult for these devices to go through this valve from inside of the sheath. Besides, in our system, the occluder should be inserted into the radial sheath, the valve on the end of the sheath also became an obstacle for the occluder. So, we designed and made a special apical access sheath for our implantation system and developed it according to different generations of the systems (see Fig 2.17).

A 10 Fr access sheath is the main part of this apical access unit. The second part is a 3 cm soft silicon tube (10-Fr inner diameter) which was attached onto the end of the sheath. These two parts were always fixed on the apex throughout the implantation. The third part was detachable. It consisted of a valvular end (see Fig 2.17 A) or an end with a lid (see Fig 2.17 B). The former was used in the first and the second generations of the systems. It should be taken off after the tethers capture step. The latter one was used in the last generation. It should be taken off when the operator saw the dilator on the tip of the delivery system get out from the apical radial sheath. Afterwards, the silicon tube could be clamped to stop the blood stream.

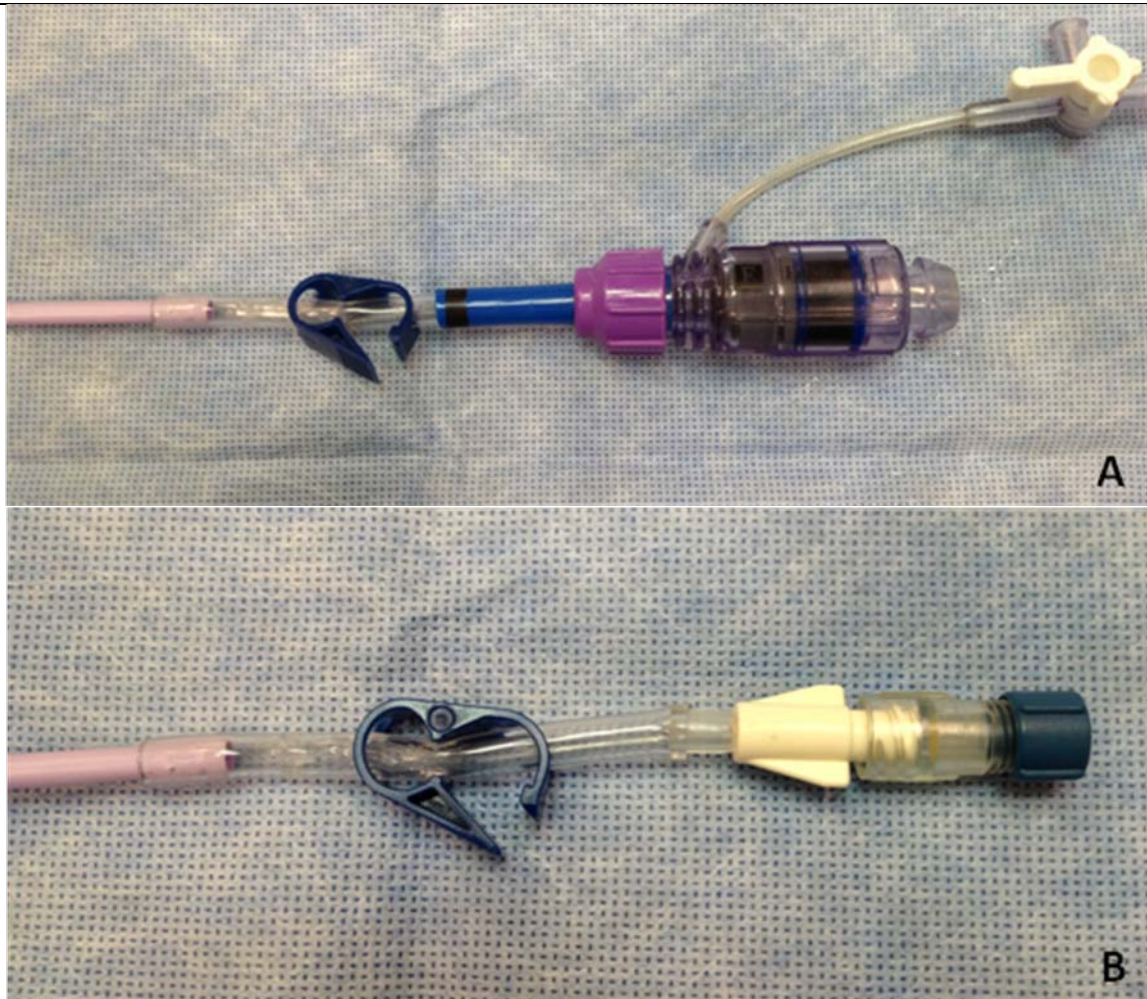


Fig 2.17 A: The apical access unit with a detachable valvular end. B: The apical access unit with a detachable lid.

2.6 In vitro water circulation system and prototype test system

Due to simplification of the transvenous-transseptal access in the in vitro study, we performed the test on our system via a left-transatrial access. For the evaluation, we established an in vitro water circulation system (see Fig 2.18). 37°C water was continuously pumped into the left atrium via a sheath at velocity of 1l/min by a rotary pump. The outflow from the aorta was gathered by a 51 cm×36 cm×15 cm uncovered acryl glass box and emptied into the water recycle pool for circulation.



Fig 2.18 The in vitro circulation system. a: Acryl glass box; b: Water recycle pool; c: Rotary pump; d: Porcine heart and its fixation system.

All tests were conducted on porcine hearts which were received from a local slaughterhouse. Each heart was fixed in the center of the acryl glass box. A 20 cm entrance sheath for the stent delivery system was inserted into the left atrium via one of the pulmonary vein and fixed. The other pulmonary veins were closed. This sheath was modified from a 19 Fr vascular access

sheath. In the tests which were performed under endoscopic view, this sheath was an entrance for the endoscope. In those cases, another sheath of the same type was stuck and fixed in the middle of the left atrium wall. Water was pumped into the left atrium via one of these sheaths (see Fig 2.19).

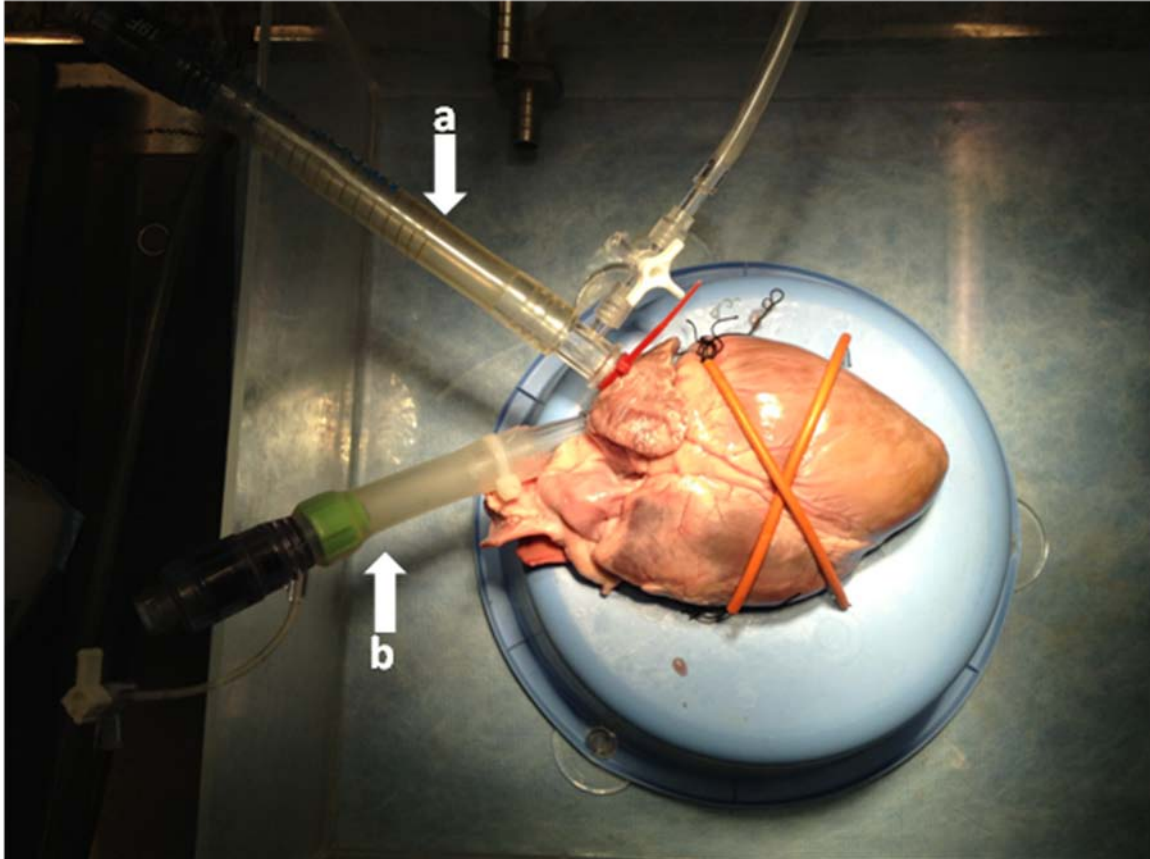


Fig 2.19 a: Water and endoscope access sheath; b: Access sheath for the balloon catheter for track establishment as well as the stent delivery catheter.

2.7 Prototype evaluation and optimization

The first generation prototype was designed and produced for percutaneous mitral valved stent implantation. The prototype was tested in the in vitro system which we have mentioned above. General operability of each part of the system was evaluated. Different parts of the prototype were improved as soon as problems appeared in the in vitro evaluation. So, the prototype was developed and optimized into next generations until the final third generation. This final prototype was further evaluated quantitatively in the following.

2.8 In vitro tests on the latest prototype

The third generation prototype was the optimal generation in this in vitro study. It was tested

respectively eleven times under endoscopic view and x-ray visualization in the in vitro circulation system. Durations and rate of success of each procedural step were recorded. According to these tests, the feasibility of this in vivo test was evaluated.

3. Results

3.1 Femoral vein-apex guide wire track establishment system

The magnet capture system was tested in ten porcine hearts. All the balloon catheters were caught by the magnet in all cases (10 of 10) (see Fig 3.1). The average duration of balloon catheter capturing was 120 seconds (n = 8; see Table 3.1). But problems occurred in 2 of 10 hearts. As we know, for keeping the pressurization of the heart, valvular end had to be added on all sheaths indwelt on the heart. These ends prevent water running out from the sheaths in order to keep the pressurization in the heart. But the difficulty of pulling the magnets out of the sheaths was also increased because of the valve. In 2 cases, the magnets were blocked by the valve and dropped off from the tip of the balloon catheter into the hearts.

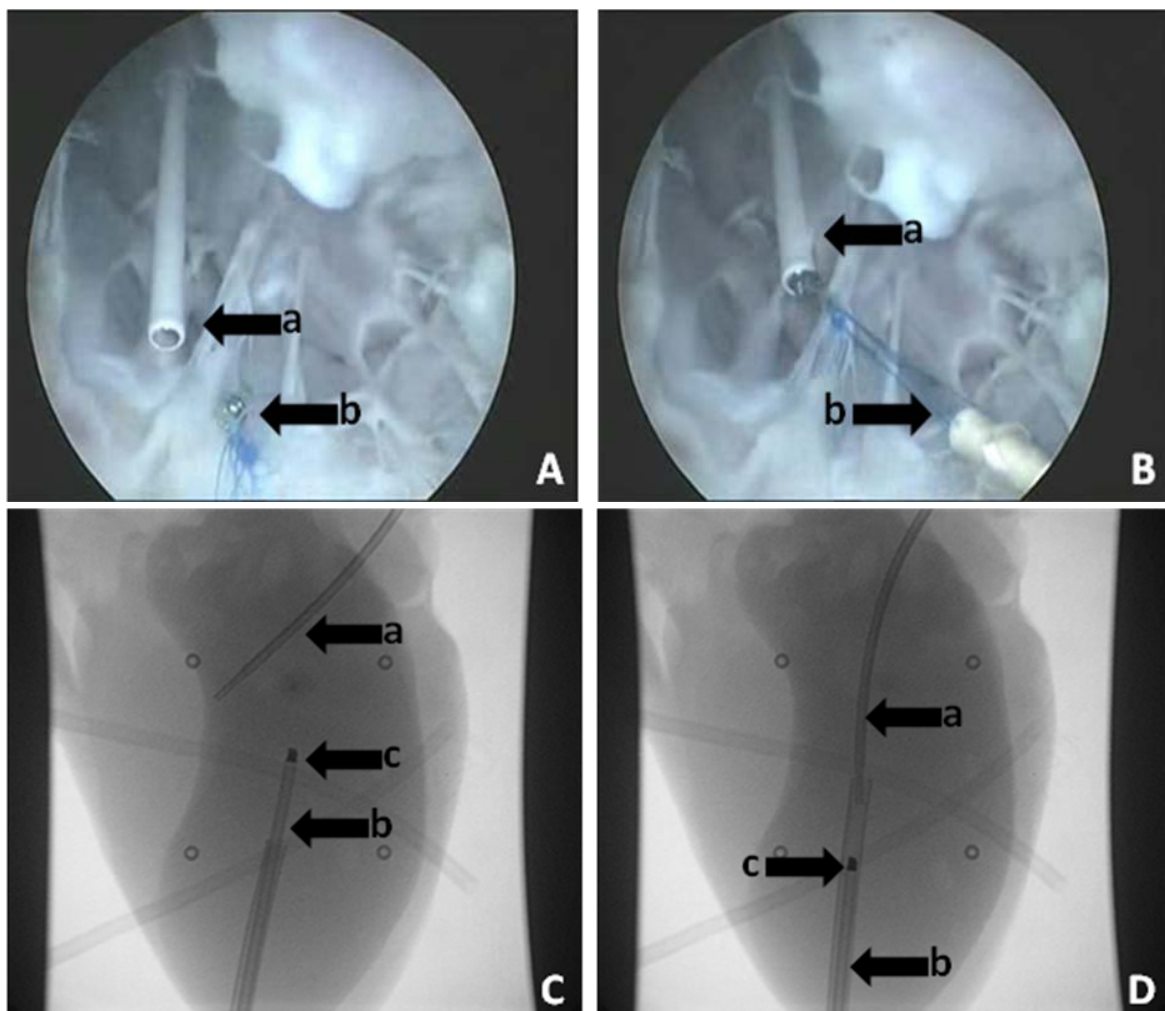


Fig 3.1 A, B: The magnets caught each other under endoscopic view. (a: the stick with the magnet on the tip; b: the magnet on the tip of the balloon catheter). C, D: The magnet capture was successfully performed under X-ray visualization. (a: the balloon catheter; b: the capture stick; c: the magnets).

On the other side, the commonly clinically used snare capture system worked perfectly in this

in vitro study under endoscopic and X-ray visualization (see Fig 3.2). All the capture attempts were successfully performed in 22 of 22 hearts. The average duration of snare capture was 271 sec. No device failure happened (see Table 3.1) during the trials.

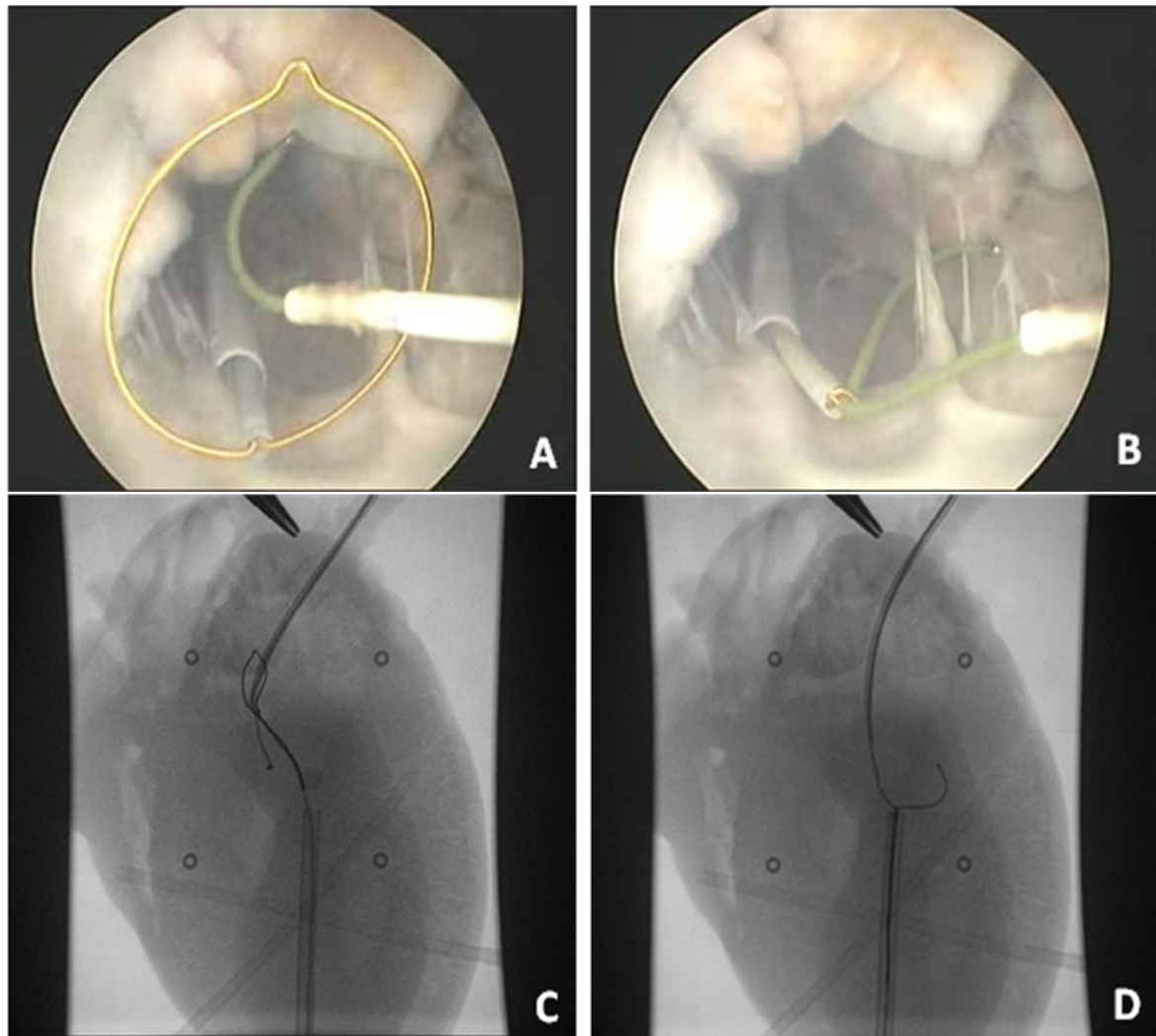


Fig 3.2 A, B: snare capture under endoscopic view. C, D: snare capture under X-ray visualization.

Table 3.1 Comparison of two track establishment systems

Method	Success Rate	Duration(sec)	Problems
Magnet capture system	10/10	120	Magnet abscission
Snare capture system	22/22	271	None

3.2 Storage and delivery system for the stent and the fixation tethers

The prototype of the first generation was tested four times in our study. Stent and tethers were successfully loaded into the catheter. In two of the four cases, the entire bundle of tethers was pulled out of the storage catheter at the same time and blocked the transapical access (see Fig 3.3 A). The tethers could not get into the apical radial sheath orderly. In the other two cases,

the tethers bundle even cannot get through the lip (see Fig 3.3 B).

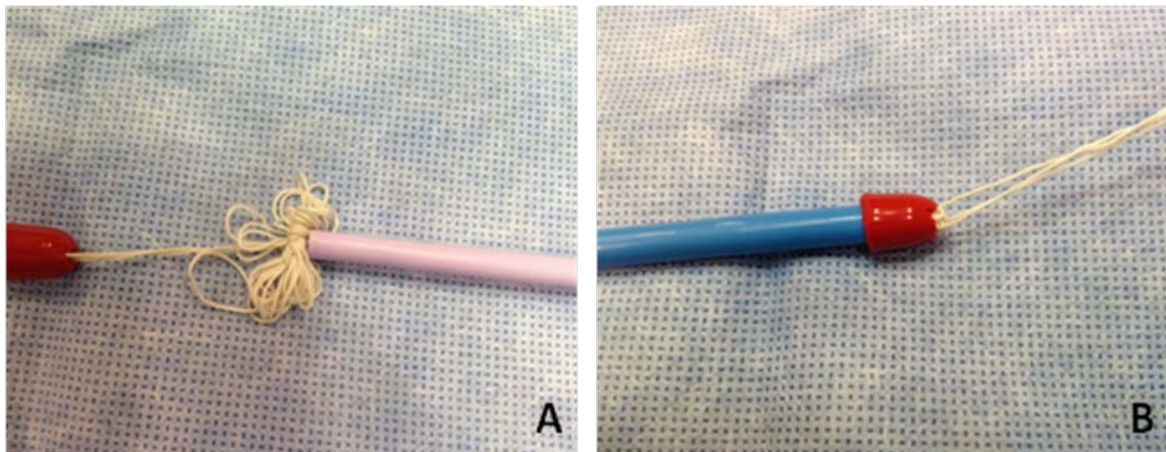


Fig3.3 A: The tethers could not get into the apical access sheath. B: The tethers were blocked in the storage catheter by the silicon lip.

The second generation worked better but not well enough. It was tested for six times, the last two hearts were done under endoscopic view in the in vitro circulation system. In 4 of 6 hearts, the tethers were smoothly pulled out. But in the other two hearts, the tethers were hampered. In one of these two hearts, too much tether released off at the same time and blocked the apical access sheath (see Fig 3.4 A). In the other heart, the last rounds of the tethers twined around the center lumen and cannot be moved anymore because of the friction and the resistance of the tip (see Fig 3.4 B). This situation was observed under endoscopic view.

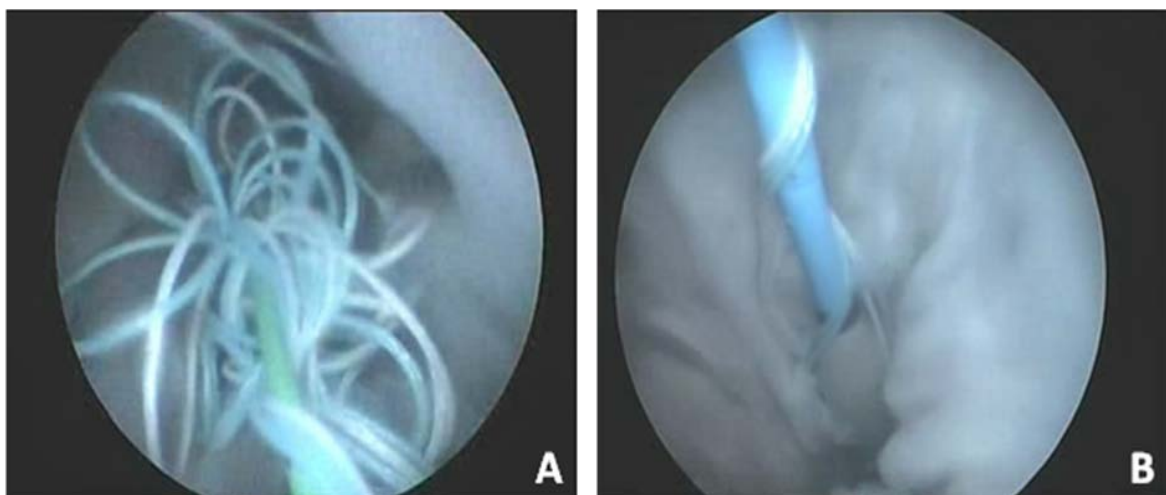


Fig 3.4 A: The fixation tethers blocked the apical access sheath. B: The last rounds of the tethers twined round the center lumen and cannot be moved anymore.

The third generation was tested in 22 hearts. In all hearts, the tethers were successfully delivered within the heart, smoothly and orderly. Table 3.2 lists a comparison between the three generations.

Table 3.2 Comparison between the fixation tethers storage and delivery systems

Prototype Generation	Success rate of tethers loading	Success rate of tethers straightening	Problems
1 st generation	4/4	0/4	unordered tethers clew
2 nd generation	6/6	4/6	unordered tethers clew; insufficient straighten of the tethers
3 rd generation	22/22	22/22	None

3.3 Fixation tether capture system

The tests on the hook-loop system were performed in four hearts. In 3 of 4 hearts, the loop was successfully caught by the hook. But unfortunately, due to the problems with the first generation of the tethers storage system, the loop-hook structure was not strong enough to pull the clew of tethers out. Finally, all of these three loops were broken owing to too much force. In one heart, the loop was collapsed and closed because of the surface tension of the liquid. It was impossible to pass the hook through the loop.

The forceps-magnet-loop system was tested six times. In all the six hearts, the loops were caught by the forceps (see Fig 3.5 A). In 4 of 6 hearts, the loops were successfully pulled out of the apical sheath. In the other two hearts, the loops were broken because they were not strong enough to overcome the obstruction of the tethers. It took in average 157 sec from the beginning of tethers capture to all the tethers being straightened. No endocardium, chordae tendineae or mitral valve damage was observed.

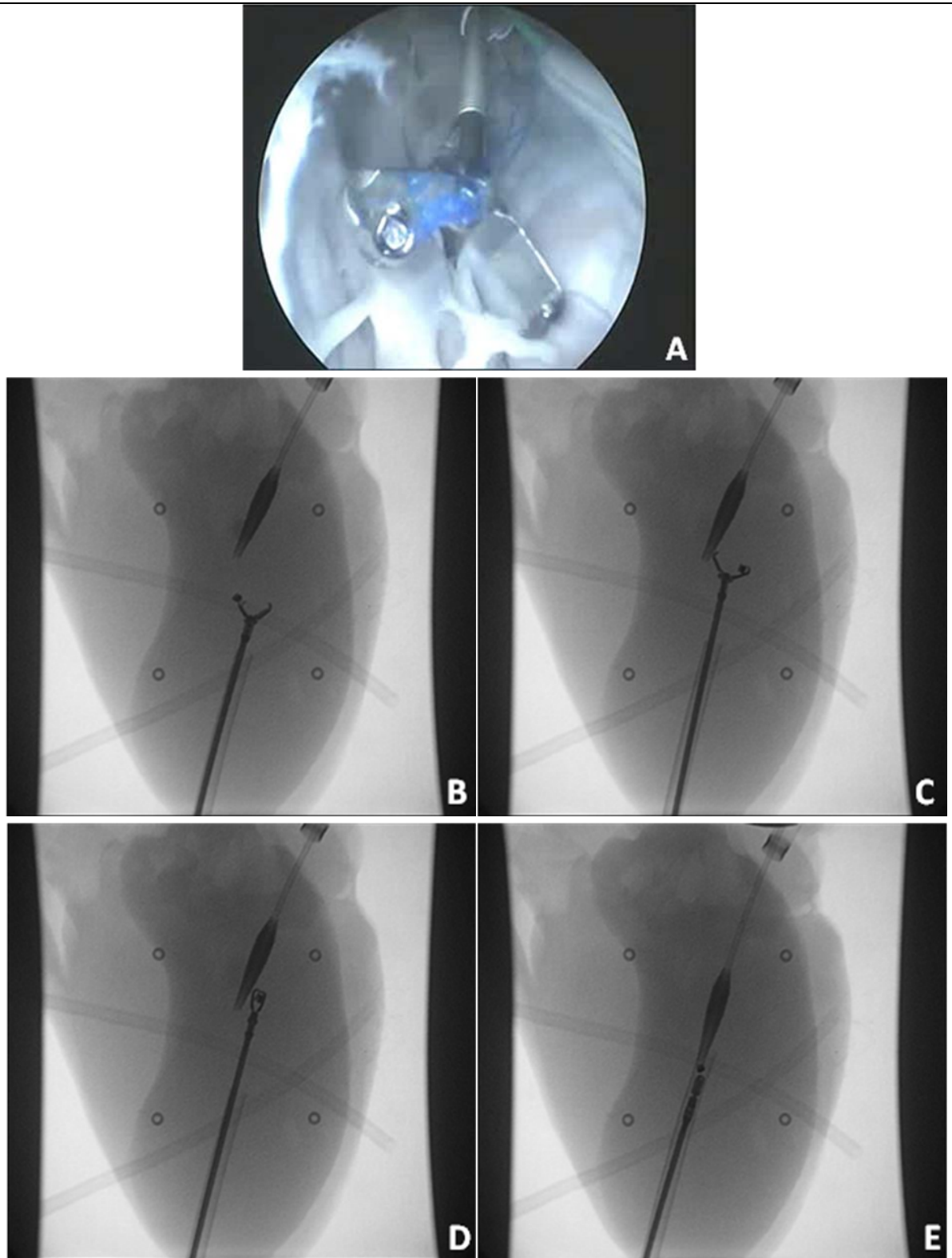


Fig 3.5 A: The forceps caught the magnet under endoscopic view. B: The forceps held the magnet on its tip. C, D: The forceps was pushed a few centimeters forward to catch the loop behind the magnet. E: The forceps caught the loop and it was pulled into the apical access sheath.

As mentioned above, the hand capture system worked well in all the 22 hearts. Average duration of the capture procedure was 36 sec. Comparison of three generations of tethers

capture system are listed in Table 3.3.

Table 3.3 Comparison of three tethers capture system

Method	Success Rate	Duration (sec)	Problems
Hook-loop system	0/4	N/A	loop break; invisible procedure under direct vision or X-ray
Forceps-magnet-loop system	4/6	157	loop break
Hand capture system	22/22	36	None

N/A=Not available

3.4 Tensile test on the deployed occluder

In eight hearts, we did the tensile test on the deployed occluder. The mean minimal tension for dragging the occluder out of the apex was 29 N (from 17.5 N to 39 N) (see Table 7.1 in appendix section).

3.5 In vitro overall evaluation of the latest prototype

The optimized prototype was tested under endoscopic view and X-ray visualization for 11 times, respectively. The average durations of the whole in vitro implantation procedure were 11 min 30 sec under endoscopic and 10 min 47 sec under X-ray visualization. Average durations of the main steps of the implantation under endoscopy and X-ray are listed in Table 3.4.

Table 3.4 Durations of the main steps of in vitro implantation

	Duration	
	under endoscopy	under x-ray
Track establishment	5 min 06 sec	3 min 55 sec
Stent delivery and tethers capture	2 min 56 sec	1 min 45 sec
Occluder deployment	1 min 46 sec	1 min 21 sec
Stent deployment	0 min 20 sec	0 min 41 sec
Overall procedure	11 min 30 sec	10 min 47 sec

The positioning of the stent was classified into 6 grades (I=excellent; II=good; III=not bad; IV=not well positioned, but most part of the stent was in the mitral annular; V=not well positioned and most part of the stent was out of the mitral annular; VI=the whole stent was in the left atrium or the left ventricle; see Table 3.5). In the tests under endoscopy, 10 of 11 stents

were excellently positioned (see Fig 3.6). One stent got a good position. The stent position after 8 of 11 implantations under X-ray were classified as grade I, in two cases as grade II and in one case as grade I.

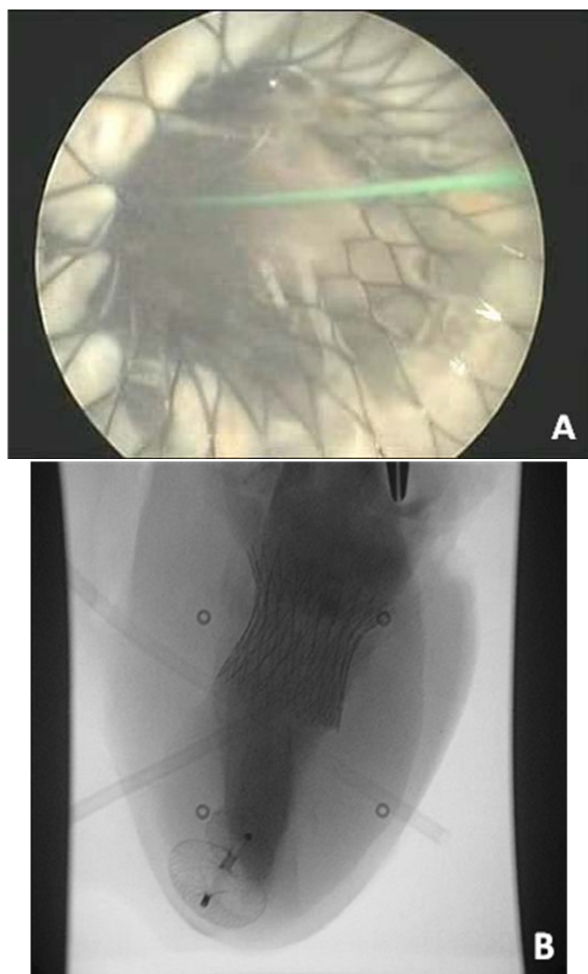


Fig 3.6 A: Stent position under endoscopy. B: Stent position under X-ray.

Table 3.5 Stent position classification under endoscopy and X-ray

	Number	
	Under endoscopy	Under X-ray
Class I	10	8
Class II	1	2
Class III	0	1
Class IV	0	0
Class V	0	0
Class VI	0	0
Total	11	11

Class I=excellent; Class II=good; Class III=not bad; Class IV=not well positioned, but most part of the stent was in the mitral annular; Class V=not well positioned and most part of the stent was out of the mitral annular; VI=the whole stent was in the left atrium or the left ventricle.

In all of the 22 hearts, the occluder was well deployed and the position was excellent. But in 7 of 22 cases, the occluders could not be delivered along the fixation tethers and the guide wire smoothly. In four cases of them, the occluders even could not be pushed any more unless the tethers were released. The tethers could be straightened again after the occluder deployment.

4. Discussion

4.1 Self-expandable nitinol stent

In 2005, Boudjemline, Ma and their groups have demonstrated the feasibility of transcatheter atrioventricular valved stent implantation. They respectively fixed the stent by jamming the atrioventricular annulus between two crowns and disks (Boudjemline et al., 2005) (Ma et al., 2005). In Boudjemline's study, neither echographic nor angiographic leakage was detected after percutaneous tricuspid valved stent implantation in 7 of 8 animals (Boudjemline et al., 2005). Theoretically, these stents do not need any other anchorage systems for stent fixation; these kinds of stent structure were more suitable for percutaneous implantation. But Ma's study showed that this stent fixation was not enough to prevent PVL's in mitral position. In their study, no stent migration was observed but severe PVL's were reported (Ma et al., 2005). We may summarize the reasons then as follows:

1. The native mitral annulus is not exactly circular. The gap between the stent and the native annulus has to be covered by the stent.
2. The maximal pressure in the left ventricle is much higher than that in the right ventricle. The stent fixation is not strong enough for PVL prevention.
3. Contraction of the left ventricle is more powerful than that of the right heart and the consequent deformation of the annulus is more violent. The double disk or double crown structure decreases the compliance of the stent, especially the compliance of its annulus element.
4. Expanding of ventricular disk of the stent is restricted by the native mitral valve and its chordae tendinae. Consequently, the ventricular disk of the stent cannot provide optimal force for anchoring the stent in mitral annulus during ventricular systole. The risks of stent migration and PVL are increased.

Having these reasons in mind, in this in vitro study and the planned consequent in vivo study, we decided to use the stent with tethers for better stent fixation and PVL prevention. It had been demonstrated excellent in both, mitral and tricuspid, positions in our previous studies. However, as a result, the tethers storage and fixation presented an obstacle with regard to percutaneous valved stent implantation. It will be discussed in the part of stent storage and delivery system.

4.2 Device development

4.2.1 Femoral vein-apex guide wire track establishment system

Anyhow, the magnet system worked well in the heart, even better than the snare capture system in most of the cases. In our study, the magnet was fixed onto the tip of the balloon catheter by 5-0 polypropylene sutures, a small metallic ring (1 mm in diameter, 0.5 mm in thickness) and super glue. It was proven that this fixation was not strong enough to pass the valve at the end of the interventional devices. It is possible to make the fixation of the magnet much stronger by technical and material improvements, for example by an additional covering of the balloon catheter. Then we can pull the magnet into this sheath before we pull the whole balloon catheter out. So, the magnet could be protected. But the methods above increase material cost and more than that-compared to the snare capture system-they are more complicated. An easier structure always means higher efficiency and less risk. For these reasons, we chose the snare capture system in our study as the optimal one.

But capture with magnets was a good idea anyway and it worked really well in the heart. It may even have more advantages in smaller chambers than the snare capture system such as in vessels and hearts of infants. This technique is well worth developing. First of all, the catheter structure and craftsmanship should be improved.

4.2.2 Storage and delivery system for the stent and the fixation tethers

The first generation prototype

The in vitro tests on this system showed that the clew of tethers was blocked in the left ventricle or even in the storage catheter. So, the problem occurred how to store three 75 cm long tethers in a 4 cm long 14 Fr catheter and make sure that they can be pulled out orderly.

Another problem of this prototype was its unstreamlined configuration. As described above, we used a 14 Fr flap-like lip and a 6 Fr conical tip to cover the top of the catheter. The different sizes of these two parts lead to unstreamlined configuration. As mentioned, the tip should be detachable and small enough to pass the 10 Fr apical access sheath while the lip should be large enough to cover the top end of a 14 Fr catheter. It was not achieved to produce these two structurally and functionally separated parts into a continuous whole. But obviously, the non-continuous configuration increased the resistance especially in the case of passing the atrial septum (see Fig 4.1).

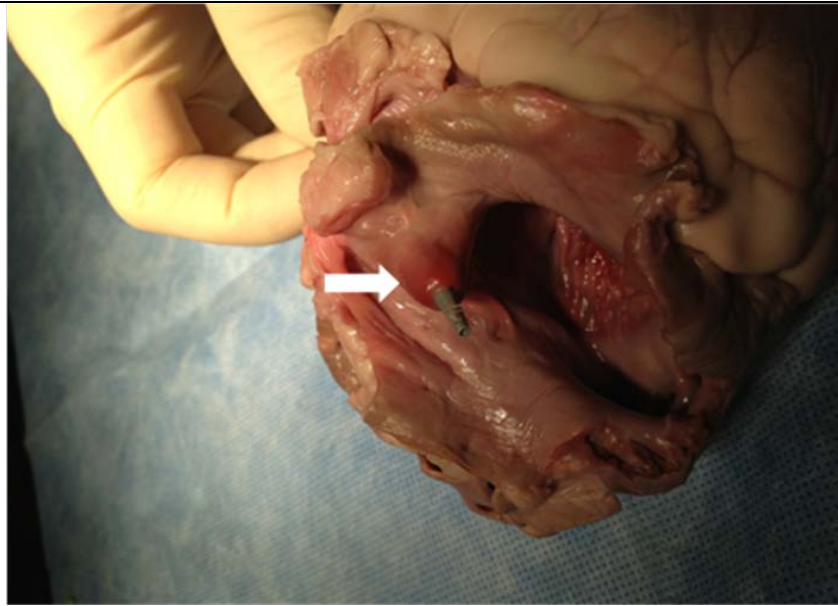


Fig 4.1 The silicon lid could not smoothly pass the septum (the white arrow).

Furthermore, another reason why we chose the lip structure is that it didn't occupy any space inside the catheter and then there would be enough capacity for containing the tethers. For the passage of the stent, we made a 'Y' shaped incision on the lip. So the stent and tethers storage catheter was not totally sealed. In addition, when the tip meets the resistance of the septum, the incision could easily be opened by the pressure on the tip (see Fig 4.2). This increased the risk of tethers releasing from the catheter too early. The non-continuous configuration and unstable connections would probably become obstacle for the transseptal approach.




Fig 4.2 The conical lid could be easily pressed into the catheter.

In summary, the main reason which led to these problems is the storage of the three 75 cm long tethers. The tethers should occupy as less space as possible and have to be pulled out of the storage catheter orderly. Accordingly, in the prototypes of following generations, storage of the tethers should be primarily taken into account.

The second generation prototype

In this prototype generation, the tethers were wound around the center lumen instead of being folded into a bundle. The tethers were orderly wound from the bottom to the top so they can be pulled out the other way round. More than that, the needed space for the tethers was effectively minimized because of the helical structure.

As a result, the change made it possible to use a larger conical tip (14 Fr in maximum diameter) instead of the lip to seal the catheter. The role of the small conical tip was replaced by a small detachable tube as described above. Though this tip occupied some space in the catheter, the remaining space was enough for the tethers. More important, the configuration of this prototype was much more streamlined than that of the first generation. And, obviously, this generation was much more robust. The tethers were prevented from releasing because the catheter was totally sealed.

Beyond all questions, there was a great improvement on the prototype, especially on the tip. A stable tip structure was formed. But problems still remained on the tethers storage system.

In our tests on this prototype, in 4 of 6 hearts the tethers were successfully pulled out, and the stents were deployed afterwards. But records of the endoscope showed the problems as follows:

1. After catching the tethers via transapical approach, the stent storage and delivery catheter should be opened by pushing the pusher to open the passage for the tethers and the stent as well. If the catheter was opened too much, the compressed wound tethers easily released into the left ventricle. The clew of tethers could probably block the 10 Fr transapical approach.
2. Fig 4.3 A shows that in order to straighten the last three rounds of the wound tethers, the tethers have to be wound three times around the center lumen catheter reversely. Otherwise, the tethers can never be straightened. Just as a spring, the number of its rings does not change with its length. Fig 4.3 B shows what happened in our test on the second generation prototype. The tethers were merely pulled but not straightened. The green part of the tethers was pulled out of the heart, but three rounds of the red tethers still hanged tight over the center lumen catheter. It is not difficult to imagine, friction increased with

the increasing tension. In 4 of 6 hearts, the friction was overcome and the stent was successfully pulled out and deployed. But in 1 of 6 hearts the stent deployment failed due to high friction on the center lumen catheter.

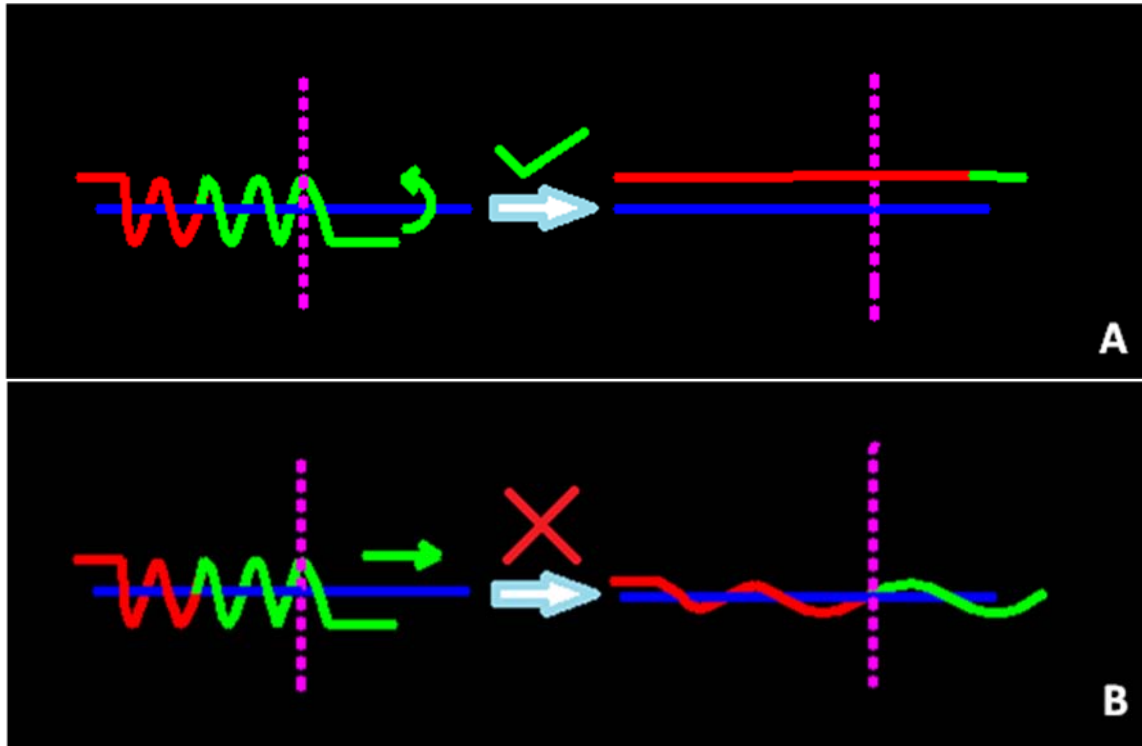


Fig 4.3 Imagination of tethers reloading in the second generation prototype: The blue line is the center lumen of the stent storage and delivery system. The red line and the green line, respectively, represent two parts of one tether. The red part is closer to the stent. The purple line represents the apex. The pictures show that we have to wind it while pulling in order to straighten the tether (A). Otherwise the red part of the tethers would never be straightened but be tied around the center lumen (B).

To conclude, tests on this prototype indicated that although the helical tethers storage system minimized the needed space and the tethers could be pulled out orderly. But problems occurred during the stent deployment. Besides, tethers releasing automatically when the storage catheter was opened too much was another problem. The tethers storage system was improved and lead to the next generation.

The third generation prototype

In this prototype generation, the tethers were stored within a 37 cm long tethers storage lumen which was composed of an inner 35 cm center lumen catheter and an outer 37 cm dilator. The tethers were straightened and folded into half. Consequently, they were stored in the lumen between the two catheters. Both of the catheters were long and thin enough to pass through the 10 Fr apical access sheath and could easily be removed.

This unit delivered the tethers out of the chest in all hearts (22 of 22 hearts). Because the tethers were kept straight in the storage lumen, they were not able to move or be out of shape till the dilator has been removed. Accordingly, the tethers releasing during delivery and capture was successfully avoided.

After taking the dilator off transapically, three tethers and the center lumen catheter were clearly exposed under direct vision. What we only have to do was to straighten the folded tethers and take the center lumen catheter off. Thus the three 75 cm tethers which had troubled us in the past two generations were under control, straightly and orderly.

In addition, as mentioned above, the center lumen catheter was cut off from the arterial pig tail catheter, and the dilator was made from soft silicon. Therefore, these units would be soft and strong enough to be delivered along the femoral vein-septum-apex track and pass the septum in the planned in vivo study.

Summary

A clear improvement in the operative process in mitral valved stent implantation could be observed throughout the development of this functional unit resulting in the third prototype generation. For this, the key improvement was the change of the tethers storage technique. Accordingly, the tip was transformed into different shapes or lengths. The tethers storage lumen outside the stent delivery catheter nicely resolved the problems of tethers storage and capture which we are going to discuss in the next part.

4.2.3 Fixation tether capture system

The first generation capture system: “hook-loop” system

As described in the materials and methods part, in this generation, the loop on the tip of the delivery system was captured by a hook. Because the loop made from 3-0 polypropylene suture was non-visualized under X-ray, it was very difficult to catch the loop in the left ventricle by a hook. So, the tip was delivered into the apical 10 Fr access sheath before capturing. That means the loop capturing was conducted in limited space. It was supposed to increase the success rate of tethers capture.

The tests on the loop-hook system showed a good capture rate, but also indicated two main problems of this system. Firstly, the polypropylene suture was not strong enough to sustain high tension. Secondly, stronger sutures such as silk ones were unsuitable for this system either, because their softness makes them impossible to keep the loop open in the blood. In

some cases, they were not stiff enough to resist the surface tension of the liquid.

Furthermore, for the hook-shaped applicators, valves on the end of the sheath were always obstacles. The hook can easily get into the sheath but it is difficult to pull it out. The paradox was that a valve-like end was necessary in the loop-hook system for blocking the blood stream. Other blood blocking methods such as clamp locking device can perfectly stop bleeding but the hook movability was also restricted.

The second generation capture system: “forceps-magnet-loop” system

The magnet on the loop made it easier for the forceps to catch the loop. As soon as the forceps were delivered into the left ventricle, the magnet automatically attached to the tip of the forceps automatically because of magnetic force. The forceps can easily catch the loop after moving a little forward.

Both, the magnet and the forceps were visible under X-ray. It was possible to monitor the whole capture procedure under X-ray and the procedure could be conducted in the left ventricle. Compared with the first generation of capture systems, this system is visible and controllable. And with the development of the tethers storage system, the whole capture processes were successfully performed in 4 of 6 hearts. Moreover, the forceps - especially designed for interventional operation - were smooth enough to pass the valve-like end of the sheath in both directions.

The forceps-magnet-loop system is more efficient than the hook-loop system. However, due to the inherent defect of the suture loop, it is risky to conduct the capture with this system in vivo. If the loop is broken in the heart or the apical sheath and the tethers are only be partly released, there would be immense problems, because neither picking the tip out via apical access nor pulling all the devices back via venous approach would be feasible at that time. Nothing could be done to retrieve the situation transcatheter-based and the procedure has to be converted into an open surgical one by enlarging the apical access.

In conclusion, the suture loops method had to be exchanged and the next generation of tethers capture system should be safer and more efficient.

The third generation capture system: “hand capture” system

As mentioned above, this generation of tethers capturing system was tested in 22 hearts. In all hearts, the tethers storage lumens could smoothly guide the tethers out of the heart via the apical access. Afterwards, the procedure of tethers capture was performed without any help of

devices under direct vision and completed in a short period of time. All the tethers were slightly and successfully captured by hands, no device damage happened. The procedure from the tethers storage lumen getting into the apical radial sheath to the center lumen being taken off took averagely 36 sec.

With this system, neither stent delivery nor tethers capture had to be monitored under X-ray or endoscopy. Appearance of the tethers storage lumen in the apical sheath was a very clear visible signal. Due to absence of operations in the heart, no endocardium, chordae tendinae nor mitral valve damage was detected after implantation. It showed the high safety and controllability of this system.

In addition, the valvular end of the apical sheath could be replaced by a clamp lock device in this system. The dilator of the tethers storage lumen matched with the apical access sheath size, thus the blood stream was blocked by the dilator during the tethers capture. After taking off the storage lumen, the apical sheath could be clamped, and the following occluder loading could be conducted outside the body. The apical sheath should be kept close until occluder deployment started.

Summary

All of these three generations have good success rate in the capture of tethers. But owing to the problems of the tether storage system, all the tests on the first generation and 2 of 6 tests on the second generation were not completed. However, these two generations had one fatal disadvantage: the fragile suture loops. Breaking of the loop would probably lead to open chest operation or another non-correctable situation.

No endocardium, chordae tendineae nor mitral valve damage was detected in any heart after implantation. In the loop-hook system, the loops were caught in the apical radial sheath. The hook did not touch any parts of the heart, and, therefore did not injure the heart. Similarly, the third generation is absolute harmless to the heart, it does not even have any invasive components. Although no heart damage was detected in the tests on the forceps-magnet-loop system, the possibility of heart damage cannot be ruled out. Because, in this system, the tethers capture was conducted in the left ventricle and the metallic forceps with serrated bite match is invasive anyway.

Another factor has to be taken into consideration is the compatibility of the tethers capture system and the apical access sheath. It is one of the most overlooked points in the in vitro experiments, because there was no real blood stream in the tests. But in the in vivo experiments, low compatibility of these two parts would result in massive blood loss. For the

loop-hook system and the forceps-magnet-loop system, we had to fix a valvular end onto the apical sheath. And it should be detachable, because it would also block the occluder deployment. This valvular end blocked the bloodstream, and was not restrictive for the movability of the hook and the forceps. After tethers capture, the valved blocker had to be removed and replaced by a clamp lock.

In contrast, the third generation was simpler and more convenient. What one had to do was to open the clamp lock, take the tethers storage lumen out and clamp the sheath again. Simple but efficient structure minimized blood loss as well as uncertainty arising from complicated devices and operations.

Besides, the second generation took more than 4 times longer than the third one. In summary, the hand capture system is safer and more efficient than the former generations. In other words, it would be more practicable in the planned in vivo experiments.

4.3 The Amplatzer™ septal occluder

4.3.1 Occluder deployment

All occluders were nicely deployed within a short time in our tests (see Fig 4.4). That showed us the feasibility to perform the same procedure on a beating heart. But to push the occluder along the tethers and track was sometimes difficult in our in vitro tests. This problem was observed in 7 of 22 hearts. In 4 of these hearts, this problem was particularly serious. However, as noted in the results part, after releasing the ends of the tethers, the occluder could be pushed together with the tethers. Afterwards, the tethers could be easily straightened again by pulling their ends. So, in case of the situation above, the stent had to be kept in the storage catheter until the occluder deployment being finished. Otherwise the stent would probably be driven out of its position by the blood stream after the tethers were released.

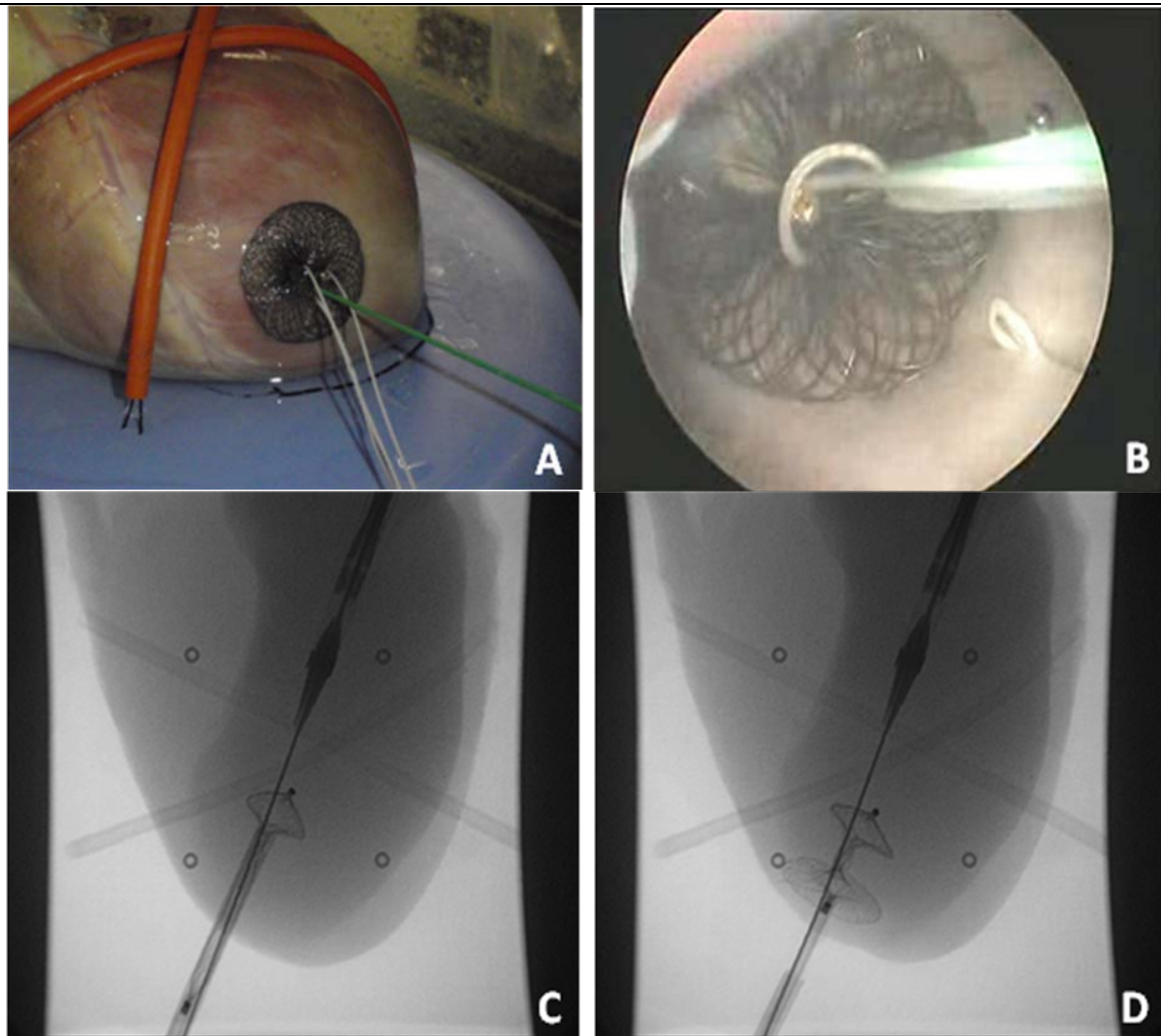


Fig 4.4 A: The macro view on the apex after occluder deployment. B: Endoscopic view from atrial side on the occluder. C: The small disk of the occluder was pushed into the heart and expanded. D: Afterwards, the apical access sheath was taken off and the big disk of the occluder expanded.

4.3.2 Tensile test on the deployed occluder

The tensile tests on the occluders in 8 hearts indicate the feasibility of the amplatzer occluder to hold the mitral valved stent in position. In the in vivo study on the transapical mitral valved stent implantation of our research group, the similar tensile test on the tethers and the stent was also conducted. The results showed, in normal porcine hearts, the range of tension on the stent to keep it in position is from 3.2 N to 5.7 N (4.5 N in average) (see Fig 4.5). In this in vitro study, the occluder could stand forces from 17.5 N to 39 N (29 N in average) before being pulled out of the apical defect. Therefore, it is reasonable to say that the occluder is able to hold the mitral valved stent in position in a beating heart.

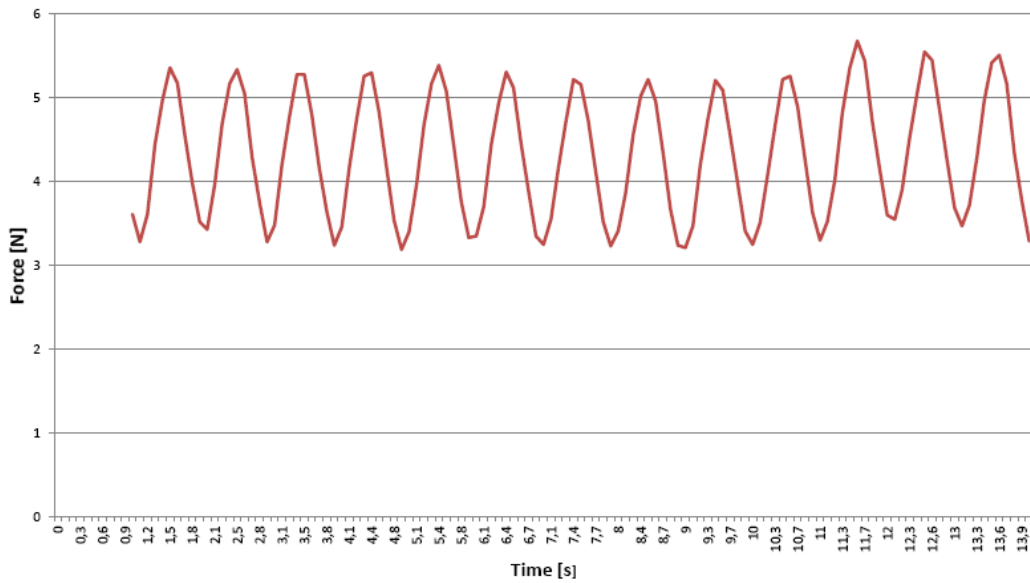


Fig 4.5 This diagram shows the tension of a well positioned mitral valved stent on the apical fixation in a beating heart.

4.4 Stent deployment: push or pull?

As we know, for percutaneous heart valved stent implantation, the catheter system should be long and soft enough to deliver the stent and the accessories into the heart. In our system, the stent storage and delivery catheter have to be turned almost 180° at the septum level. But the softer and longer the catheter is, the more serious deformation could happen when it is pushed. That means, when the soft and long pusher on the venous end is pushed to deploy the stent, a large part of the force on the pusher just increases the deformation of the catheter but does not work on the stent. External load could lead to device damage if the delivery system is not strong enough. However, tension on the tethers from apical side can directly work on the stent. By pulling the tethers, the stent could be more easily deployed and the risk of device damage could be reduced (see Fig 4.6).

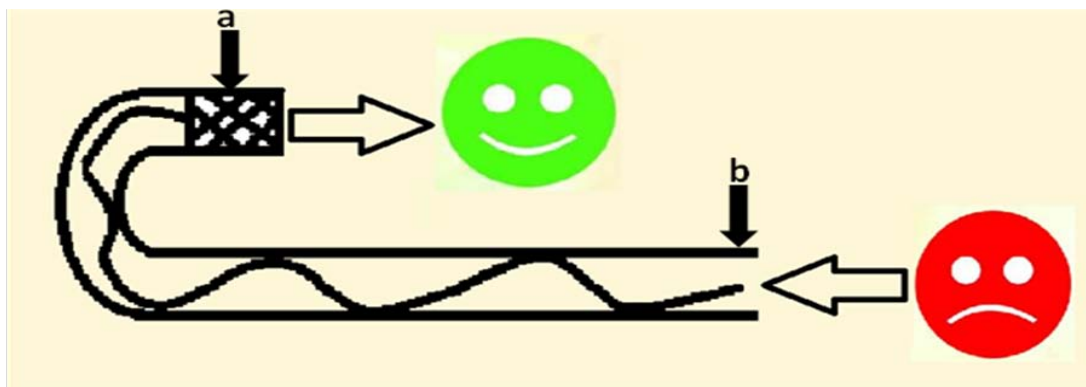


Fig 4.6 To push the stent on the venous end (b) could lead to sever deformation of the delivery catheter. But to pull the stent from the apical side directly work on the stent (a).

4.5 In vitro tests on the latest prototype

In vitro tests on the prototype showed that the implantation could be undergone in averagely 11 min 30 sec under endoscopy and 10 min 47 sec under X-ray visualization. All the 22 tests were finished without any device damage or any other interrupt failure. This result presented high operability of this prototype.

Though, in the in vivo experiments endoscopy is not practicable. The test under endoscopic view helped us to know how the applicator worked in the heart and how the problems happened in the in vitro study.

All the stents and the occluders were deployed in position. However, in 4 of the 22 hearts, the positions of the stents were below the best grade. But due to the location of the native mitral annular in a non-beating heart is much more difficult than in a beating heart. It is possible to improve stent deployment in the in vivo studies.

Moreover, as noted above, most of the occluders (in 15 of 22 hearts) could be pushed along the tethers and the guide wire track. And in the other seven hearts, the occluders could be deployed after the tethers being released. Nevertheless, various kinds of tethers should be tested in this system in the following study to find stronger and smoother tethers for the prototype.

5. Summary

To date, merits of minimal invasive or non-invasive aortic valved stent implantation in high-risk patients have already been demonstrated clinically by multiple registries from multiple centres (Webb and Wood 2012). Over 20,000 cases and over 100 publications in the last 10 years showed an absolute 20% increase in survival at 1 year in high-risk patients (Webb and Cribier 2011).

In our study, a new idea for non-invasive mitral valved stent implantation is presented. The mitral valved stent and occluder was successfully connected via transspetal and transapical access. The duration of the whole procedure under endoscopy and X-ray was acceptable clinically. Especially in the implantation under X-ray, the whole procedure of in vitro implantation could be conducted in averagely 10 min 47 sec. For the patients determined to be too high risk for surgery, shorter operative duration and less invasive probably mean faster recovery and higher survival.

The main techniques used in this in vitro study of percutaneous mitral valved stent implantation have been commonly used clinically. The history of transspetal (Allison and Linden 1953) and transapical puncture (Lehman et al., 1957; Levy and Lillehei 1964) on human is longer than 50 years. And occlusion of the defect on the left ventricle of human heart by AmplatzerTM occluder was conducted in 2011 (Jelnin et al., 2011).

The stent and its tethers fixation system for this in vitro study have been tested in more than 50 porcine hearts in the in vivo study by our research group in the last 2 years. The mid-term observation shows it has the potential to be implanted in human heart (not yet published). Compared to the transcatheter mitral valved stents reported in the last few years, this system has less PVL and lower risk of stent migration (Lutter et al., 2009; Ma et al., 2005).

Due to the gap between the mitral valved stent and the native mitral annulus and the difficulty of stent fixation, no successful transcatheter mitral valved stent implantation has been reported up to now. In this study, a novel mitral valved stent was used to reduce PVL and it was anchored onto the apex by three fixation tethers. An AmplatzerTM occluder served as an anchor point for the stent and occlusion for the apex defect. All the procedures were conducted along a femoral vein-septum-apex guide wire track. These first in vitro prototype tests showed good results in terms of operability and mitral stent fixation. It has a great potential to develop to an alternative and less invasive implantation procedure in contrast to transapical mitral valved stent implantation. But more data especially from in vivo trails are required.

6. References

Allison PR, Linden RJ. (1953) The bronchoscopic measurement of left auricular pressure. *Circulation*. May;7(5):669-73.

Andersen HR, Knudsen LL, Hasenkam JM. (1992) Transluminal implantation of artificial heart valves. Description of a new expandable aortic valve and initial results with implantation by catheter technique in closed chest pigs. *Eur Heart J*. May;13(5):704-8.

Azadani AN, Tseng EE. (2011) Transcatheter heart valves for failing bioprostheses: state-of-the-art review of valve-in-valve implantation. *Circ Cardiovasc Interv*. Dec 1;4(6):621-8.

Bai Y, Zong GJ, Wang HR, Jiang HB, Wang H, Wu H, Zhao XX, Qin YW. (2010) An integrated pericardial valved stent special for percutaneous tricuspid implantation: an animal feasibility study. *J Surg Res*. May 15;160(2):215-21.

Bonhoeffer P, Boudjemline Y, Qureshi SA, Le Bidois J, Iserin L, Acar P, Merckx J, Kachaner J, Sidi D. (2002) Percutaneous insertion of the pulmonary valve. *J Am Coll Cardiol*. May 15;39(10):1664-9.

Bonhoeffer P, Boudjemline Y, Saliba Z, Hausse AO, Aggoun Y, Bonnet D, Sidi D, Kachaner J. (2000) Transcatheter implantation of a bovine valve in pulmonary position: a lamb study. *Circulation*. Aug 15;102(7):813-6.

Boudjemline Y, Agnoletti G, Bonnet D, Behr L, Borenstein N, Sidi D, Bonhoeffer P. (2005) Steps toward the percutaneous replacement of atrioventricular valves an experimental study. *J Am Coll Cardiol*. Jul 19;46(2):360-5.

Boudjemline Y, Bonhoeffer P. (2002) Steps toward percutaneous aortic valve replacement. *Circulation*. Feb 12;105(6):775-8.

Cribier A, Eltchaninoff H, Bash A, Borenstein N, Tron C, Bauer F, Derumeaux G, Anselme F, Laborde F, Leon MB. (2002) Percutaneous transcatheter implantation of an aortic valve prosthesis for calcific aortic stenosis: first human case description. *Circulation*. Dec 10;106(24):3006-8.

Cribier A, Eltchaninoff H, Tron C, Bauer F, Agatiello C, Sebah L, Bash A, Nusimovici D, Litzler PY, Bessou JP, Leon MB. (2004) Early experience with percutaneous transcatheter implantation of heart valve prosthesis for the treatment of end-stage inoperable patients with calcific aortic stenosis. *J Am Coll Cardiol*. Feb 18;43(4):698-703.

Gurvitch R, Cheung A, Ye J, Wood DA, Willson AB, Toggweiler S, Binder R, Webb JG. (2011) Transcatheter valve-in-valve implantation for failed surgical bioprosthetic valves. *J Am Coll Cardiol*. Nov 15;58(21):2196-209.

Hernandez JM, Fernandez JF, Tenas MS, Ruigomez JG. (2012) [Update on interventional cardiology]. *Rev Esp Cardiol (Engl Ed)*. Jan;65 Suppl 1:4-11.

Iino K, Lozonschi L, Metzner A, Marczyński-Buhlow M, Renner J, Cremer J, Lutter G. (2011) Tricuspid valved stent implantation: novel stent with a self-expandable super-absorbent polymer. *Eur J Cardiothorac Surg.* Aug;40(2):503-7.

Jelnin V, Dudiy Y, Einhorn BN, Kronzon I, Cohen HA, Ruiz CE. (2011) Clinical experience with percutaneous left ventricular transapical access for interventions in structural heart defects a safe access and secure exit. *JACC Cardiovasc Interv.* Aug;4(8):868-74.

Lehman JS, Lykens HD, Musser BG. (1957) Cardiac ventriculography; direct transthoracic needle puncture opacification of the left (or right) ventricle. *Am J Roentgenol Radium Ther Nucl Med.* Feb;77(2):207-34.

Levy MJ, Lillehei CW. (1964) Percutaneous Direct Cardiac Catheterization. A New Method, with Results in 122 Patients. *N Engl J Med.* Aug;271:273-80.

Lutter G, Ardehali R, Cremer J, Bonhoeffer P. (2004) Percutaneous valve replacement: current state and future prospects. *Ann Thorac Surg.* Dec;78(6):2199-206.

Lutter G, Kuklinski D, Berg G, Von Samson P, Martin J, Handke M, Uhrmeister P, Beyersdorf F. (2002) Percutaneous aortic valve replacement: an experimental study. I. Studies on implantation. *J Thorac Cardiovasc Surg.* Apr;123(4):768-76.

Lutter G, Quaden R, Osaki S, Hu J, Renner J, Edwards NM, Cremer J, Lozonschi L. (2009) Off-pump transapical mitral valve replacement. *Eur J Cardiothorac Surg.* Jul;36(1):124-8; discussion 8.

Ma L, Tozzi P, Huber CH, Taub S, Gerelle G, von Segesser LK. (2005) Double-crowned valved stents for off-pump mitral valve replacement. *Eur J Cardiothorac Surg.* Aug;28(2):194-8; discussion 8-9.

Pavcnik D, Wright KC, Wallace S. (1992) Development and initial experimental evaluation of a prosthetic aortic valve for transcatheter placement. Work in progress. *Radiology.* Apr;183(1):151-4.

Tozzi P, Pawelec-Wojtalic M, Bukowska D, Argitis V, von Segesser LK. (2007) Endoscopic off-pump aortic valve replacement: does the pericardial cuff improve the sutureless closure of left ventricular access? *Eur J Cardiothorac Surg.* Jan;31(1):22-5.

Webb J, Cribier A. (2011) Percutaneous transarterial aortic valve implantation: what do we know? *Eur Heart J.* Jan;32(2):140-7.

Webb JG, Wood DA. (2012) Current status of transcatheter aortic valve replacement. *J Am Coll Cardiol.* Aug 7;60(6):483-92.

7. Appendix

Table 7.1 Tensile test on the depolyed occluder

Heart	Max. Force (N)
1	38
2	39
3	29
4	28
5	17.5
6	26.5
7	25
8	29
Average	29

8. Acknowledgements

Firstly, I sincerely thank Prof. Dr. med. Georg Lutter, head of the laboratory and also my supervisor, for his invitation and great supports of my visit and training at Kiel University, for his scientific instruction of this research program. I enjoyed his perfect art as a heart surgeon.

Special thanks should be given to Ms. Dr. rer. nat. Anja Metzner, for her kind help with my study in Kiel. Thank her for giving me the opportunity to participate in this interesting project.

Special thanks should be given to Dr. rer. nat. Martin Marczynski-Bühlow, for his excellent direction and enthusiastic supports throughout the project, for his careful and patient correction of this dissertation. I enjoyed being work with him in this in vitro study, discussing and overcoming every difficulty.

Thanks also give to Ms. Sarrahs Beke for her excellent expert technical assistance as well as her great help with my training and life in Kiel. I enjoyed being work with her.

Special thanks should be given to Mrs. Saskia Pokorny for her stent for this in vitro study.

I sincerely thank Ms. Dr. med. vet. Telse Maike Bähr, Ms. Jessica Bolt, Ms. Birgit Pieper and Ms. Judith Pohanke for their great supports on my live and study in Kiel.

9. Curriculum Vitae

Personal information

Name	Huangdong Dai
Gender	Male
Date of Birth	10. 11. 1983
Place of Birth	Shanghai, P.R.China
Address	Holtenuer Str. 162, 24105 Kiel
Email	riodhd@gmail.com
Cell Phone	004915211525994
Nationality	P.R.China

Career experience and academic degrees

September 1999-July 2002	Qibao Middle School, Shanghai, P.R.China
September 2002-July 2009	Master learning, Clinical Medicine in Tongji Medical College, Huazhong University of Science and Technology.
January 2006-July 2007	General internship, Union Hospital, Tongji Medical College, Huazhong University of Science and Technology, Wuhan City, Hubei Province, PRC
July 2007-April 2010	Major internship, Department of Orthopedics, Union Hospital, Tongji Medical College, Huazhong University of Science and Technology, Wuhan City, Hubei Province, PRC
July 2010-July 2013	Doctoral student, Research Department of Cardiovascular Surgery, School of Medicine, Christian-Albrechts-University, Kiel, Germany

Publications

Presentations

Dai H, Marczynski-Bühlow M, Sarrahs B, Metzner A, Cremer J, Lutter G. (2013) Percutaneous mitral stent implantation: First in vitro prototype tests. The 42nd Annual Meeting of the German Society for Thoracic and Cardiovascular Surgery (DGTHG).

Pokorny S, Hettich H, Bähr T., **Dai H**, Marczyński-Bühlow M, Sattler B, Cremer J, Lutter G. (2013) Transapical mitral valved stent implantation: Computed tomographic comparison. The 42nd Annual Meeting of the German Society for Thoracic and Cardiovascular Surgery (DGTHG).

Huenges K, Pokorny S, Bähr T, Bönke F, **Dai H**, Cremer J, Lutter G. (2013) Off-pump mitral valved stent implantation guided by Real-Time 3D-Transesophageal Echocardiography. The 42nd Annual Meeting of the German Society for Thoracic and Cardiovascular Surgery (DGTHG).

Pokorny S, Huenges K, Marczyński-Bühlow M, **Dai H**, Gundlach JP, Lozonschi L, Lutter G. (2012) Update on Mitral Valved-Stent Implantation with an Apically Tethered Valve. 12th ISMICS Annual Scientific Meeting.

Pokorny S, **Dai H**, Sattler B, Hettich H, Bähr T, Lutter G, Heller M. (2012) Transapical mitral valved stent implantation: Computertomographic studies. Experimentelle Radiologie 2012.

Submitted paper

Bolt J, Lutter G, **Dai H**, Marczyński-Bühlow M, Sarrahs B, Schoettler J, Cremer J, Metzner A. (2013) A new strategy for heart valve decellularization for tissue engineering. Biomaterials.

Pokorny S, **Dai H**, Huenges K, Bähr T, Marczyński-Bühlow M, Morlock M, Cremer J, Lutter G. (2013) Off-Pump Transapical Mitral Valved-Stent Implantation: A Comparison of Circular vs. D-Shape Atrial Element Design. The Annals of Thoracic Surgery.

Submitted abstract for scientific meeting

Dai H, Marczyński-Bühlow M, Sarrahs B, Metzner A, Cremer J, Lutter G. (2013) Percutaneous Mitral Stent Implantation: First In Vitro Prototype Tests. 13th ISMICS Annual Scientific Meeting.

Paper in preparation

Percutaneous Mitral Stent Implantation: First In Vitro Prototype Tests.

Transapical Mitral Valved Stent Implantation: Mid-term Observation of Tissue Ingrowths on Mitral Valved Stent.