

**Aus der Klinik für Urologie und Kinderurologie**

(Direktor: Prof. Dr. med. Klaus-Peter Jünemann)

im Universitätsklinikum Schleswig-Holstein, Campus Kiel

an der Christian-Albrechts-Universität zu Kiel

**MICROVESSEL DENSITY AS PROGNOSTIC FACTOR IN PENILE  
SQUAMOUS CELL CARCINOMA**

Inauguraldissertation

zur

Erlangung der Doktorwürde

der Medizinischen Fakultät

der Christian-Albrechts-Universität zu Kiel

vorgelegt von

**SAKHR MOHAMMED AHMED AL-SANABANI**

aus Dhamar, Jemen

KIEL 2011

1. Berichterstatter: PD Dr. med. C.M. Naumann

2. Berichterstatter: Prof. Dr. med. Leuschner

Tag der mündlichen Prüfung: 16.08.2013

Zum Druck genehmigt, Kiel, den 16.08.2013

gez.

**This thesis is dedicated to  
my father for his firmly–established uncompromising principles that guide my life,  
my mother for her infinite give and for leading her children into intellectual pursuits,  
my wife for her patience and continuous support,  
my children for making every thing worthwhile.**

## **Abbreviations**

ACIS: Automated Cellular Imaging System

EAU: European Association of Urology

HNSCC: Head and neck squamous cell carcinoma

LAD: Lymphadenectomy

LNM: Lymph node metastasis

MVD: Microvessel density

OAS: Overall survival

PSCC: Penile Squamous Cell Carcinoma

SLNB: Sentinel lymph node biopsy

TNM: Tumour, Node, Metastasis

vWF: von Willebrand Factor (Factor VIII)

## Table of Contents

<b>1. Introduction</b>	<b>1</b>
1.1. Carcinoma of the penis	1
1.1.1. Epidemiology and geographic distribution patterns	1
1.1.2. Etiology	2
1.1.3. Signs and symptoms	2
1.1.4. Pathology	3
1.1.5. Clinical assessment, staging and treatment of lymph nodes	3
1.1.5.1. Unsuspectious inguinal lymph nodes and their management	4
1.1.5.2. Palpable inguinal lymph nodes and their management	5
1.1.5.3. The pelvic lymph nodes and their management	5
1.2. Angiogenesis	6
1.3. Objective of the study	7
<b>2. Materials and methods</b>	<b>8</b>
2.1. Materials	8
2.1.1. Tissue samples	8
2.1.2. Characteristics of Patients	9
2.2. Methods	9
2.2.1. Immunohistochemical staining	10
2.2.2. Microvessel density assessment	12
2.2.2.1. Light microscope	12
2.2.2.2. Automated Cellular Imaging System	13
2.2.2.2.1. Calibration	13
2.2.2.2.2. Slide identification	13
2.2.2.2.3. Vessel count	13
2.4. Statistical analysis	15
<b>3. Results</b>	<b>16</b>
3.1. Morphological features of vessels according to intra and peritumoural compartments	16
3.2. MVD in lymph node positive and negative PSCC	17
3.3. MVD and its correlation with T Stage	19
3.4. MVD and its correlation with tumour grade	20
3.5. MVD and its correlation with risk groups	23
3.6. MVD and its correlation with inflammation	24

3.7. MVD and its correlation with patient survival	25
<b>4. Discussion</b>	<b>27</b>
4.1. The dilemma in the diagnosis and treatment of occult lymph node metastases	27
4.2. Correlation between microvessel density and survival	28
4.3. Morphology of intratumoural and peritumoural microvessel density	31
4.4. Correlation between microvessel density and risk group of patients with histopathologic parameters	31
<b>5. Conclusion</b>	<b>33</b>
<b>6. References</b>	<b>34</b>
<b>7. Acknowledgement</b>	<b>41</b>
<b>8. Curriculum Vitae</b>	<b>42</b>

## 1. Introduction

Penile cancer is a malignant neoplasm found on the skin or in the tissues of the penis. More than 95% of malignant tumours are carcinomas, and squamous cell carcinoma accounts for most cases of penile malignancies. The other rare neoplasms include malignant melanoma, sarcoma, Paget's disease, lymphomas and metastases from other sources as well as the urothelial carcinoma of the urethra can involve the penis by local spread [1].

### **1.1. Carcinoma of the penis**

Penile squamous cell carcinoma (PSCC) is an uncommon tumour. PSCC almost arises in the epithelium of the foreskin, coronal sulcus and glans. The behaviour of PSCC is more or less like squamous cell carcinoma (SCC) of the oropharynx, uterine cervix, vagina, vulva and anus. Nowadays, there is more information about of the natural history of the disease, earlier diagnosis, better technology, research group collaboration and centralisation of patients in centres of excellence. These factors lead to improvement the cure rate for penile cancer from 50% in the 1990s to 80% in 2008 [2].

#### **1.1.1. Epidemiology and geographic distribution patterns**

The carcinoma of the penis accounts for 0.4% of all cancers in the male population and 2–4% of all genitourinary malignancies in developed countries [3]. There is a wide geographic distribution, with low frequency in Western world and higher frequencies in Africa, Latin America, and Asia. In developed countries, primary PSCC is rare, with an incidence of less than 1 per 100,000 males in Europe and the United States of America (USA) [4,5]. In developing countries, by contrast, the incidence rate of primary PSCC is much higher and can make up 10-20% of malignant disease in men ranging from middle to old age. Despite these statistics, the incidence of penile carcinoma has been declining in many countries, partly because of increased attention to personal hygiene. Although blacks are more commonly diagnosed than whites with a ratio of 2:1, racial predilection has not been clearly proven and any observed racial differences are more likely due to socioeconomic or environmental factors. PSCC most commonly occurs in the sixth decade of life, but may occur in men younger than 40 years. Such cases have been reported in Whites, Asians, Jews, Arabs, Native Indians of South America, and Afro-Americans. There is no racial preference for penile carcinomas. Familial cases also have been noted [6].

### **1.1.2. Etiology**

Carcinoma of the penis has been strongly associated with phimosis and poor local hygiene. Phimosis is found in more than half of the patients in most series of penile carcinoma. The irritative effect of smegma, a by-product of bacterial action on desquamated epithelial cells within the preputial sac, is well known, although definitive evidence of its carcinogenic role is lacking. Neonatal circumcision as practiced by groups such as the Muslim and Jewish populations virtually eliminates the occurrence of penile carcinoma. Postponement of circumcision until puberty does not have the same benefit as neonatal circumcision, and adult circumcision does not provide any protection against carcinoma of the penis [7]. Among patients with condylomata acuminata the risk of carcinoma is increased for vulva, vagina, penis and anus [6]. Human papillomavirus (HPV) infection, particularly HPV-16, has been implicated in the development of invasive penile carcinoma, as has the number of sexual partners [8]. HPV-16 and -18 have a causal role in 70% of carcinomas of the cervix, the vagina and the anus and about 30-40% of carcinomas of the vulva, penis and oropharynx. Other cofactors are very likely to be necessary for progression from HPV infection to cancer. High-risk types of HPV, including 16, 18, 31, 33, 39, 45, 52, 58, and 59, have been linked to cervical, vulvar, penile, and a smaller percentage of oropharyngeal carcinomas [8]. Five years ago, a vaccine against HPV was recommended for immunization of females and males in the USA. Surprisingly, the presence of high-risk HPV DNA in penile carcinoma does not compromise the prognosis; instead, more recent studies suggest that the presence of high-risk HPV confers a survival advantage in patients with penile carcinoma. The consumption of tobacco products has been shown to be an independent risk factor in the development of penile carcinoma on multivariate analysis. Tobacco has been proposed as a promoter of malignant transformation in the setting of infection and chronic irritation. Thus, avoidance of tobacco products and HPV infection, penile hygiene and neonatal circumcision represent important preventive strategies against penile carcinoma [6].

### **1.1.3. Signs and symptoms**

Carcinoma of the penis usually begins with a small lesion that gradually extends to involve the entire glans, shaft, and corpora. The symptoms range from a relatively subtle induration or small excrescence to a small papule, pustule, warty growth, or a more luxuriant exophytic lesion. It may appear as shallow erosion or as a deeply excavated ulcer with elevated or rolled-in edges. Phimosis may obscure a lesion, allowing a tumour to progress silently. Foul preputial odour and discharges with or without bleeding call attention to the disease. Penile



carcinoma may present anywhere on the penis, but it occurs most commonly on the glans (48%), the prepuce (21%), or in both locations (9%), and along the coronal sulcus (6%). Rarely a mass, ulceration, suppuration or hemorrhage in the inguinal area may be due to nodal metastasis from a lesion concealed within a phimotic foreskin. Urinary retention or urethral fistulas due to local corporal involvement are rarely presenting symptoms. Pain does not develop in proportion to the extent of local destructive process and usually is not a presenting complaint. Weakness, weight loss, fatigue, and systemic malaise are secondary to chronic suppuration. On occasion, significant blood loss from the penile lesion, the nodal lesion, or both may occur. As local disease and regional disease are usually far advanced by the time distant metastasis occurs, the symptoms belonging to such metastasis are rare [6-9].

#### **1.1.4. Pathology**

SCC accounts for more than 95% of all malignant primary neoplasms of the penis with multiple histological variants. The usual type accounts for 70% of PSCC [1]. Other histological variants represent up to 25%. These include verrucous SCC, warty SCC, basaloid SCC, sarcomatous SCC, papillary SCC, adenosquamous carcinoma, and mixed carcinomas. Other malignant epithelial tumours of the penis are Merkel cell carcinoma, small cell carcinoma of endocrine type, sebaceous cell carcinoma, clear cell carcinoma, and basal cell carcinoma. It is not known how often SCC is preceded by premalignant lesions. Such premalignant lesions include lesions that are sporadically associated with SCC of the penis, e.g. cutaneous horn of the penis, Bowenoid papulosis of the penis, and balanitis xerotica obliterans (lichen sclerosus et atrophicus). Other lesions that lead to a high risk of developing SCC of the penis are erythroplasia of Queyrat (carcinoma in situ of the glans) and Bowen's disease (carcinoma in situ of the shaft). Further neoplasia of the penis includes melanocytic tumours, mesenchymal tumours, hematopoietic tumours, and secondary tumours [10].

#### **1.1.5. Clinical assessment, staging and treatment of lymph node metastases**

The therapeutic approach to clinically normal inguinal lymph nodes remains one of the biggest controversies in the treatment of invasive penile carcinomas, as 20-25% of all patients with clinically normal inguinal lymph nodes have occult metastases [11]. Patients with enlarged lymph nodes in the groin constitute 30-60% of all PSCC [12]. In about half of these patients, this is caused by metastatic invasion and in the other half by inflammatory reactions [13]. Treatment strategies are hampered by inaccuracies in the physical examination and imaging modalities, which makes it difficult to reliably identify the presence or absence of

lymph node metastases. Accurate histological diagnosis and staging of both the primary tumour and the regional nodes are necessary for making treatment decisions [14]. The lymph node status can be divided into the following types:

#### **1.1.5.1. Unsuspected inguinal lymph nodes and their management**

When the inguinal lymph nodes are not palpable, an ultrasound of both inguinal regions may show abnormal nodes and can be used as a guide for fine-needle aspiration cytology or puncture biopsy [15]. A sentinel lymph node biopsy (SLNB) [16] can not be recommended as standard procedure due to a high rate of false-negative results (25% range 9-50%) [17]. However, the performance of dynamic SLNB compared to a 'wait-and-see' policy was shown to be associated with improved survival and in a prospective study had 100% specificity and 95% sensitivity [18]. Because of the high delicacy as well as complexity of dynamic SLNB, the procedure is only available in few centres. Conventional computer tomography (CT) or magnetic resonance imaging (MRI) cannot detect micrometastases [19]. Large studies are required to confirm the good results reported using nanoparticle-enhanced MRI and positron emission tomography (PET/CT) imaging [20]. Lymphadenectomy (LAD) is mandatory for patients with inguinal lymph node metastases. LAD is often followed by prolonged lymph leakage, which can result in leg and scrotal lymphoedema (2-100%), wound infection (10-20%), skin necrosis with or without wound dehiscence (14-65%), lymphocele/seroma (19-45%), and other complications like haemorrhage and thrombosis as well as inguinal hernia [21]. These complications had been reported in 30-70% of patients. Because of this high morbidity, inguinal lymphadenectomy should be performed in centres of experience with this procedure (meticulous lymph node dissection) as well as the postoperative care of the patients (careful skin flap management, prophylactic antibiotics, compressive stocking and early ambulation). Nodal metastases were found in 100% of pT3-T4, in 82% of pT2 tumors in around 218 patients with PSCC [22]. Metastasis within T1 tumors were seen mainly in moderate to high grade tumors, with 60 % in T1G2-3 and only 16.5% in low grade T1 tumors [22]. Patients with T1G2 are recommended to undergo surgical LN staging even in the face of clinically negative groins and the absence of lymph node invasion [23]. Patients with pT3-T4 and all G3 are unequivocal candidates for bilateral LAD. Others reported lymph node metastases in 12% of pT1G2 [24], a category that is defined as 'intermediate risk' according to the EAU guidelines [2]. Dynamic SLNB appears to be very promising [25]. The acceptance of dynamic SLNB relies on the assumption that there is a stepwise progression of the primary

lymph node (sentinel lymph node) to secondary lymph nodes. There may be multiple sentinel lymph nodes [26].

#### **1.1.5.2. Palpable inguinal lymph nodes and their management**

When the inguinal lymph nodes are palpable, this would be due to either inflammatory reactions or lymph node metastasis. Up to 50% of palpable inguinal nodes are due to reactive inflammatory reactions rather than due to lymph node metastasis. This justifies the use of antibiotics for a period of 4-6 weeks to let a chance for these lymph nodes to subside. Then regional nodes should be re-evaluated within few weeks. On the contrary, nearly all enlarged lymph nodes noticed during the follow up are metastatic [12]. An assessment of distant metastases (pelvic or abdominal CT) should be restricted to patients with proven positive inguinal nodes. Although this is not a very reliable diagnostic method for the detection of micrometastasis, the detection of pelvic masses has a considerable impact on therapy and prognosis [24].

The enlarged and not fixed palpable inguinal lymph nodes don't necessarily signify metastatic disease. False-positive nodes has been reported to be as high as 50% [12,22]. Fine-needle aspiration cytology provides an excellent and rapid method to detect metastatic involvement in these patients. As dynamic SLNB is not reliable in enlarged lymph nodes [25], a repeat-fine-needle aspiration cytology in suspected cases with tumour-negative findings is recommended. Consequently, early LAD (uni- or bilateral) should be performed in all tumour-positive patients [26]. In contralateral non-palpable lymph nodes, surgical staging is recommended.

#### **1.1.5.3. The pelvic lymph nodes and their management**

There is no direct lymphatic drainage from the primary tumour to the pelvic lymph nodes [27], and the term skip lesions refers to the presence of metastasis without any evidence of inguinal lymph node involvement are very rare and should be seen as a result of haematogenous metastasis. Pelvic lymph node dissection is only indicated in the presence of two or more inguinal nodes involvement or extranodal growth. Only the number of positive inguinal lymph node as well as extracapsular extension is regarded as the main pathological predictors for the potential involvement of pelvic nodes [28]. Pelvic LAD can be performed as a secondary procedure and through a midline suprapubic extraperitoneal incision. Positive pelvic nodes were reported as high as 23% and 56% in patients with two and more than two positive inguinal nodes respectively [29].

Variable studies show a significant relation between angiogenesis as a prognostic factor in SCC of different organs, such as uterine cervix, oral cavity, oesophagus, larynx, and lung.

## **1.2. Angiogenesis**

Angiogenesis is the formation of new blood vessels from the endothelium of the existing vasculature and is the result of a complex multistep process involving extracellular matrix remodeling, endothelial cell migration and proliferation, loop formation, capillary differentiation, anastomosis, and finally lumen development [30]. Vasculogenesis is the embryonic establishment of blood supply from mesodermal precursors such as angioblasts or hemangioblasts. Tumour angiogenesis refers to a combination of angiogenesis and vasculogenesis in which the main blood supply to a tumour derives from preexisting blood vessels, but circulating endothelial cell precursors may contribute to the growing vascular tree as well [31].

Angiogenesis is an essential process involved in the normal growth and neoplasm differentiation [30]. In its defective and excessive form, angiogenesis is a crucial event in the progression of many human diseases. Excessive angiogenesis was largely investigated in psoriasis, arthritis, diabetic retinopathy and malignant tumours. Soon after the discovery of angiogenic factors and their inhibitors, angiogenesis investigation jumped from experimental studies to clinical application. Tumour-associated angiogenesis is nowadays considered as a priority in oncology, based on numerous evidences that show a significant reduction in tumour growth following anti-angiogenic therapy.

It is now generally accepted that tumour angiogenesis is crucial both for the growth of a primary neoplastic tumour and also for the development of metastasis [30]. Several studies suggest that tumour angiogenesis is associated with tumour progression and outcome in a number of malignancies [32-34]. Although it is difficult to measure angiogenesis directly in human tumours, it is suggested that a quantification of immunohistochemically stained microvessels in histological sections, microvessel density (MVD) may be used as an index [32]. As the interest for the use of angiogenic inhibitors in cancer therapy increases rapidly, it is necessary to have valid conclusions for the importance of microvessel counts and VEGF expression in order to address their impact on the prognosis and their use as surrogates [35]. The most common antibodies used for microvessel staining so far are “anti von Willbrand Factor” (Factor VIII) antibodies, CD31, CD34, and recently CD105 [36,37].

CD34 is a single-chain transmembrane glycoprotein of approximately 116 kDa. CD34 is expressed on immature haematopoietic stem/progenitor cells, capillary endothelial cells, embryonic fibroblasts and rare glial cells in nervous tissue [38]. CD34 appears to be expressed at its highest level on the earliest progenitors, and seems to decrease progressively with maturation [39]. CD34 is a stage-specific, rather than a lineage-specific, leukocyte differentiation antigen. Monoclonal antibodies to CD34 can be confined to three main classes class I, class II and class III, defined by the differential sensitivity of the corresponding CD34 epitopes to degradation by specific enzymes. The QBEnd 10 antibody is a class II monoclonal antibody that recognizes a CD34 epitope that is resistant to neuraminidase, and sensitive to glycoprotease and chymopapain. Anti-CD34 antibody is a highly sensitive marker for endothelial cell differentiation, which stains neoplastic endothelium a deeper shade than normal endothelium [40].

In this study, CD34 was selected as a marker for evaluating angiogenesis in PSCC because a CD34 is a more specific marker for neoformed vessels than other markers such as Factor VIII and according to some authors, a positive relationship of microvessel density and prognosis was reported in prostate adenocarcinoma for the endothelial marker CD34, but not for the CD31 [41].

### **1.3. Objectives of the study**

1. To study the biological features of PSCC using MVD and to assess the role of MVD in the possibility of predicting lymph node metastasis in the primary tumour.
2. To assess the role of MVD in predicting the prognosis and survival of patients with PSCC.

## **2. Materials and methods**

### **2.1. Materials**

#### **2.1.1. Tissue samples**

The material studied comprised of formalin-fixed, paraffin-embedded (FFPE) tissue samples from a total of 89 patients with histologically confirmed squamous cell carcinoma of the penis, from the Departments of Urology in of the University Hospitals in Kiel, Giessen, Marburg, and Mannheim (all Germany), collected between 1996 and 2005. The tissue samples vary from one to three sections per patient.

#### **2.1.2. Characteristics of Patients**

The inclusion criteria of the patients with PSCC included invasive tumours, initial treatment of the primary tumour in one of our study centres, known clinical groin status at first presentation (established by clinical examination and/or computer tomography /ultrasound), and a postoperative nodal status proved by lymph node dissection or uneventful follow-up of 24 months or more. The total number of patients who met the inclusion criteria was 64 cases. Three patients were excluded because of technical limitations of the staining, either weak staining intensity, or excessive background staining of the slides. The median age of the patients was 65 (39-84) years, and the follow-up after treatment was 32 (1-126) months. During the follow up period, 19 patients died (16 and 3 because of the tumour burden and other reasons, respectively). The tumours were evaluated according to the TNM and WHO classification system of 2002 and 2004, respectively [10,42]. The tumours were staged as T1 in 22 patients, T2 in 31, T3 in 7 and T4 in 1 patient. The grading was well in 12, moderate in 26 and poorly differentiated in 23 patients. The lymph node status was negative (N0) in 31 patients (N1) metastasis in a single inguinal lymph node in 12 patients, (N2) metastasis in multiple or bilateral inguinal lymph nodes in 12 patients, and (N3) extranodal extension of lymph node metastasis or pelvic lymph node(s) unilateral or bilateral in 6 patients. Table (1) summarises the clinicopathological data of these patients.

<b>Age</b>	39-84 y
<b>T Stage</b>	
T1	22
T2	31
T3	7
T4	1
<b>Grade</b>	
G1	12
G2	26
G3	23
<b>N Stage</b>	
N0	31
N1	12
N2	12
N3	6

Table1. Patients and clinicopathological parameters (n = 61).

## **2.2. Methods**

### **2.2.1. Immunohistochemical staining**

All tumour tissues were fixed in 10% neutral buffered formalin and processed for paraffin sectioning, which represents 3 micrometer paraffin sections. Normally, formalin fixation produces methylene cross-links between nucleic acids and/or proteins. This induces cross-links that may mask some epitopes, resulting in a loss of immunoreactivity. In order to prevent this process, the “unmasking” of some epitopes from Formalin-Fixed Paraffin-Embedded tissue is accomplished by antigen retrieval techniques. This is achieved by heat treatment (heat-induced antigen retrieval), which is the most commonly used approach to optimize antigen detection.

In this study immunohistochemistry was carried out using monoclonal mouse antihuman CD34 class II, code no.M7165, at a dilution of 1:50 (DAKO, Glostrup, Denmark). The ready-to-use CD34 Class II, Clone QBEnd 10, is intended for use in immunohistochemistry together with Autostainer Link instruments.

The paraffin sections were dried in a slide incubator (Medité GmbH, Germany) at 37°C over night. Figure 1.



Figure 1: Slide incubator (Medité GmbH, Burgdorf, Germany).

The deparaffinization and epitope demaskation were made in a target retrieval solution (pH 6.1) in the PT-module link (DAKO, Denmark) at 95° C over 25 min. Figure 2.





Figure 2: Pre-treatment Tanks module, PT Link, DAKO, Denmark.

After that, the slides were cooled down to 65°C in the PT-module, taken out into the wash buffer and then cooled down again to room temperature. Afterwards, the slides were put into the Autostainer Link 48 (Autostainer Link 48, Fremont, Denmark) and were left to be stained automatically. Figure 3.

In this study, the immunohistochemical treatment was done by the streptavidin-biotin method. The detection principle by this method of streptavidin-biotin conjugation was as follows:

A biotinylated secondary antibody was used to recognize the primary antibody; streptavidin complexed with biotinylated peroxidase was then bound to the secondary antibody (streptavidin has an extremely high affinity to biotin). These reactions deliver several peroxidase molecules to the primary antibody binding site and so boost the sensitivity.

The primary antibody was put on for 30 min, and washed afterwards with wash buffer. The masked secondary antibody was then incubated for 15 min with biotin and rinsing steps were done with wash buffer. Then streptavidin alkaline phosphatase was added for 20 min. The slides were again and carefully rinsed with the chromogen, which was the colour-producing reactant in the detection system. This method was applied here by using 3-amino-9-ethyl carbazole (AEC, which produces a red colour). Chromogen was applied for 10 minutes to form a biotin-streptavidin complex and was rinsed off with distilled water. A counterstaining by Haematoxylin was done for 2 min to represent the cell nuclei optimally. Bluing was then achieved by rinsing the slides under the tap water for 5 min. Lastly, the water was rinsed by 99.9% alcohol, and the slides were prepared for mounting with a cover slip and resinous

medium by removal of the alcohol by using xylene rinses. The tonsillar tissue was used as a positive control, in which the antibody labels endothelial cells. The negative control was the section of the patient's tissue, in which the antibody was not added and was replaced by non-immune serum. Both positive and negative controls were run simultaneously with the patient specimen.



Figure 3: Autostainer Link 48, DAKO, Fermont, Denmark: Automated immunostaining devices can improve standardization and reproducibility of immunohistochemical procedures.

### **2.2.2. Microvessel density (MVD) assessment**

#### **2.2.2.1. Light microscope**

The sections were examined for inflammation and vascular invasion under a light microscope (Axioskop Zeiss-Germany 350x233-18kg jpg Nikon). The immunohistochemical positive reaction of CD34 antibodies was counted, considering its expression in the cytoplasm of endothelial cells which lined the blood vessels.

#### **2.2.2.2. Automated Cellular Imaging System**

For the counting of microvessel density (MVD), the slides were scanned in DAKO, ACIS® Automated Cellular Imaging System with System software: ACIS® version 3.0.1 Operating

system: Microsoft Windows XP Professional. Figure 4. This was achieved through three main steps:

#### **2.2.2.2.1. Calibration**

Calibration was performed by using four calibration slides; a grid slide for focus and white balance, a chrome slide for black balance and two ladder slides for linearity. One-touch calibration of the computer with the microscope platform was tested and passed successfully in all magnification levels.

#### **2.2.2.2.2. Slide identification**

Each slide was given a special code number. This was established through labelling of the slides by slide number and code number, which were printed with a check mark in order to enable the computer system to recognise it later. The application MVD Histo-Red Protocol was selected. Every four slides were put on a slide carrier, then into the slide hopper of the microscope, and running of the slides was ordered.

#### **2.2.2.2.3. Vessel count**

The counting was performed according to Weidners method [64]. All slides were captured using a RGB Digital camera and digitizer and were transformed into pixels. Then they were analyzed using a combination of RGB and HSI colour spaces. The colour space transformation has three components: 1. "Hue" of colour means red versus blue. 2. "Saturation" means the purity of the colour, e.g. pink is desaturated red. 3. "Luminosity" means the brightness or intensity of the colour. This allowed for objective scoring, quantification, sensitive and rapid rare event detection and permitted the identification of hotspots.



Figure 4: Automated Cellular Imaging System (ACIS 3) version 3.0.1 Operating system, DAKO, Denmark.

The sequences of the operation included four phases of analysis 1. Find: using a 4x objective, the entire scannable area was searched for stained specimen. 2. Focus: multiple points could be used to establish autofocus. 3. Scan: a flat approximation to the specimen surface was derived from these sampled points. 4. Collection: this approximation allowed for quantity imaging during scanning and faster refocussing during collection.

The imaging system created histological reconstruction. The image of the entire tissue section was composed of hundreds or thousands of individual microscope fields. After selection of the hotspots regions for scoring, the image system immediately quantified the level of staining intensity and converted the intensity to a score, so as to achieve accurate data on the individual regions and multiple region statistics.

Scanning of the slides and hotspots at a low resolution of magnification was done by using colour to detect positive staining for CD34, and then the selected regions were revisited at a high resolution of magnification. The regions, that included dust and dirt as well as areas of artifactual staining on the slides, were excluded. The analysed slides were saved with the measured hotspot areas in the high resolution image. The number of vessels was examined at

all magnification levels of 4x, 10x, 20x, 40x, 60x and then quantified at 200 magnifications. Three to five hot spot fields were counted for vessel density. The examination of each hot spot corresponded to a number of vessels confined to an area of 0.74 mm. CD34 histochemical positive reaction was counted from intratumoural and peritumoural areas.

The intratumoural microvessel density (iMVD) was defined as a single endothelial cell or a cluster of endothelial cells, set around a visible lumen and clearly separated from adjacent connective tissue components within the neoplastic stromal tissue in one high power field representing 0.74 mm<sup>2</sup>. The peritumoural microvessel density (pMVD) was defined as a stromal tissue space starting from the tumour margin in one high power field representing 0.74 mm<sup>2</sup>.

After scanning all of the slide sections, the selected hotspots regions were saved as a tiff folder. All information data were then exported to an Excel table within the system. Blood vessel invasion, which was present in CD34 positive vessels occupied by neoplastic cells, was also estimated, as well as inflammation. MVD was counted without any previous knowledge of the patients' outcome or other pertaining data.

### **2.3. Statistical analysis**

After showing a normal distribution in a one-sample Kolmogorov-Smirnov test, the association between the different histopathological parameters and MVD was performed by using a way of variance analysis, the ANOVA system. The relation between the lymph node status and the microvessel density was compared using a t-test. Survival curves were traced according to Kaplan-Meier, and the differences were analysed using log-rank test (level of significance <0.05). High and low MVD were defined above and below the median MVD, respectively.



### 3. Results

#### 3.1. Morphological features of vessels according to intra and peritumoural compartments

The intratumoural CD34-stained vessels were highlighted in red colour and noticed to be compressed and small in comparison with the peritumoural vessels. Figures 5 and 6.

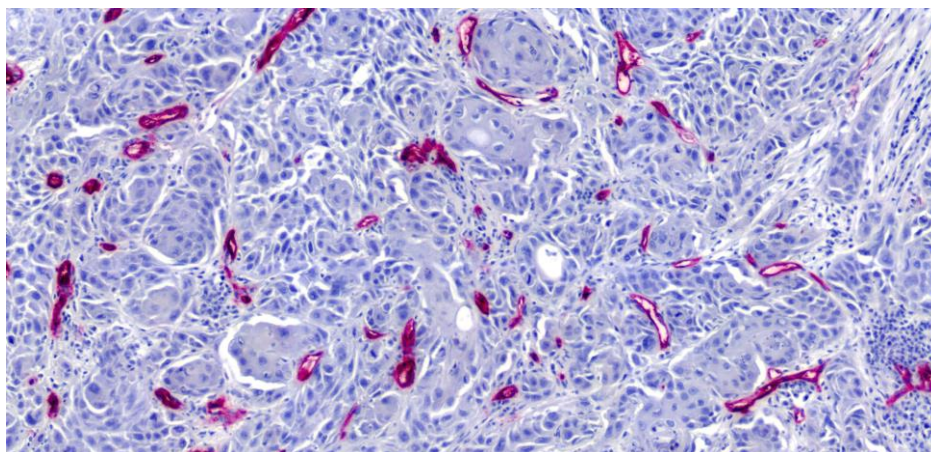


Figure 5: Intratumoural CD34-expressed endothelial cells of blood vessels. The tumour cells are pleomorphic and arranged in nests and broad sheets among them compressed vessels.

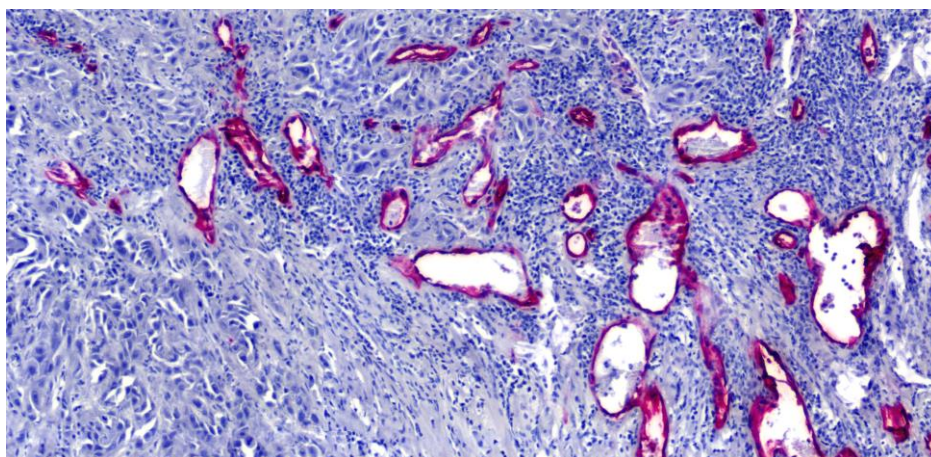


Figure 6: Peritumoural areas with CD34-expressed blood vessels showed different lumen calibres and with out compression.

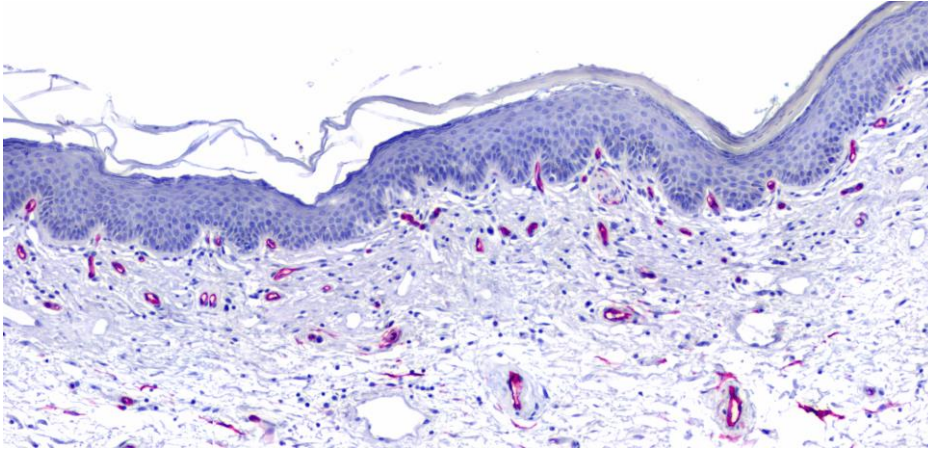


Figure 7: Non tumoural areas showing the normal vasculature beneath the epidermis.

### 3.2. MVD in lymph node positive and negative PSCC

The number of patients with lymph node metastasis is 30 compared to 31 without metastasis. 61.2% and 38.8% of patients with a low pMVD were having a node positive and negative disease respectively. 37.9% and 62.1% of patients with high pMVD were having a node positive and negative disease respectively. Figure 8.

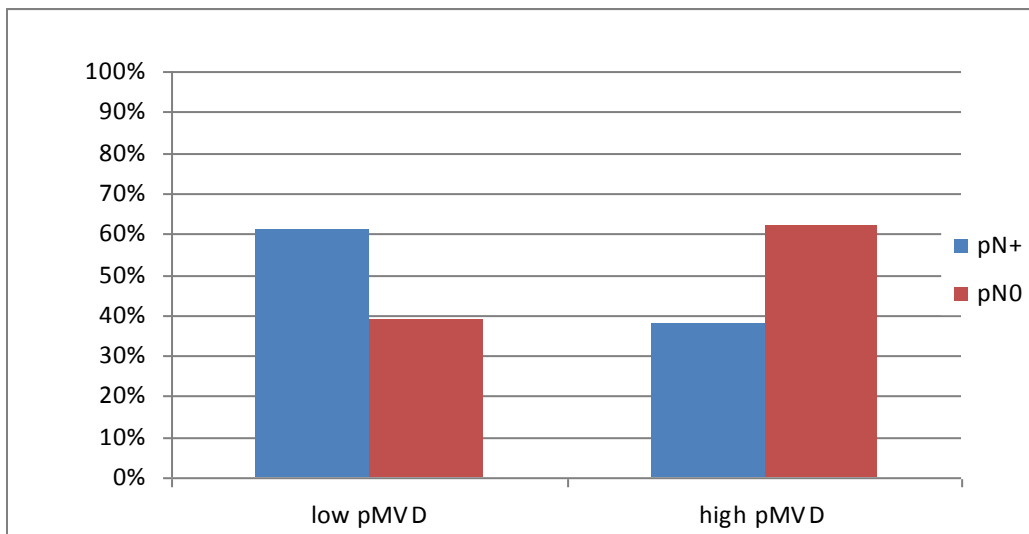


Figure 8: This figure shows the distribution of the patients according to their lymph node status to pMVD. It is noticed that the majority of node positive patients were having low pMVD.

No difference was noticed concerning iMVD. 50% of both patients groups with a low iMVD were having a node positive and negative disease. 48.3% and 51.7% of patients with high iMVD were having a node positive and negative disease respectively. Figure 9.

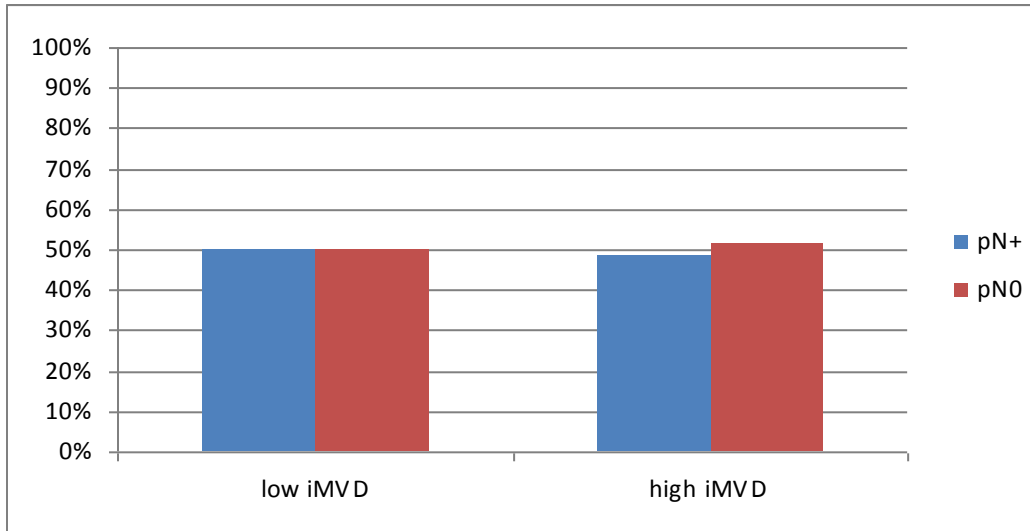


Figure 9: This figure shows the distribution of the patients according to their lymph node status to iMVD.

The mean peritumoural MVD/ $0.74\text{mm}^2$ (SD) in specimens of patients with lymph node metastasis was  $57.30 (\pm 3.93)$  and  $66.59 (\pm 7.45)$  in those without lymph node metastasis respectively ( $p=0.23$ ). Similarly, the mean intratumoural MVD showed no difference in both groups:  $38.88 (\pm 3.06)$  and  $44.72 (\pm 5.78)$ , respectively (t-test  $p=0.331$ ). Figures 10 and 11.

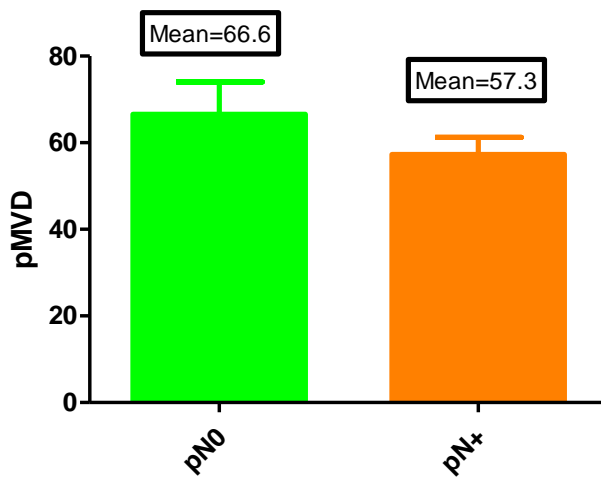


Figure 10: Peritumoural MVD in negative and positive lymph node status.



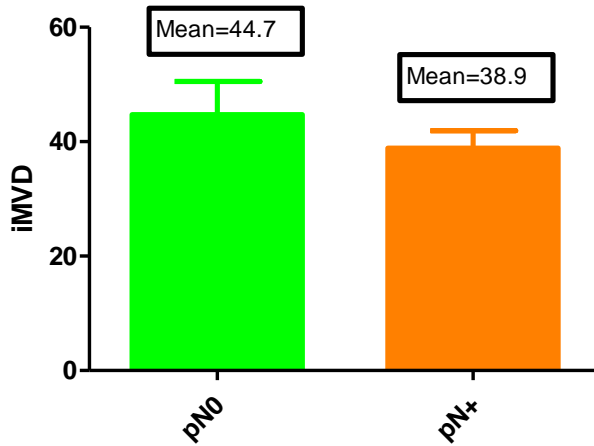


Figure 11: Intratumoural MVD in negative and positive lymph node status.

### 3.3. MVD and its correlation with T Stage

We found that the mean microvessel density MVD/0.74mm<sup>2</sup> (SD) in the non tumoural area was 28.84 ( $\pm$ 2.5) and with the comparison between peritumoural and intratumoural microvessel density further difference according to the tumour stages was also found. The comparison showed that the mean was pMVD 58.66 ( $\pm$ 3.12), and thus significantly higher than the iMVD with a mean MVD of 38.76 ( $\pm$ 2.41) (ANOVA  $p$ = <0.0001).

The mean pMVD as compared to the T stage was 55.9 ( $\pm$ 5.60), 56.8 ( $\pm$ 4.00) and 78.86 ( $\pm$ 8.71) in T1, T2 and T3, respectively (ANOVA  $p$ = 0.06). The mean iMVD was 32.35 ( $\pm$ 3.16), 37.94 ( $\pm$ 3.35) and 62.66 ( $\pm$ 5.47) in T1, T2 and T3, respectively (ANOVA  $p$ = 0.0006) with increasing tendency. The mean MVD was higher in specimens with T3 tumours and almost comparable between T1 and T2 intratumoural and peritumoural. There is only one patient with stage T4, therefore this patient is not represented in the statistics and figures. Figures 12 and 13.

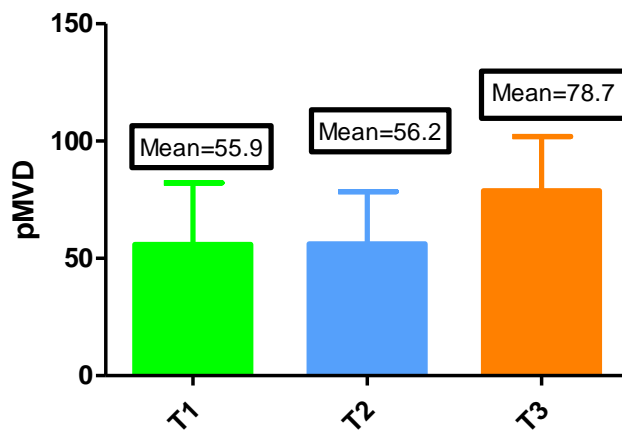


Figure 12: Peritumoural MVD according to tumour stage.

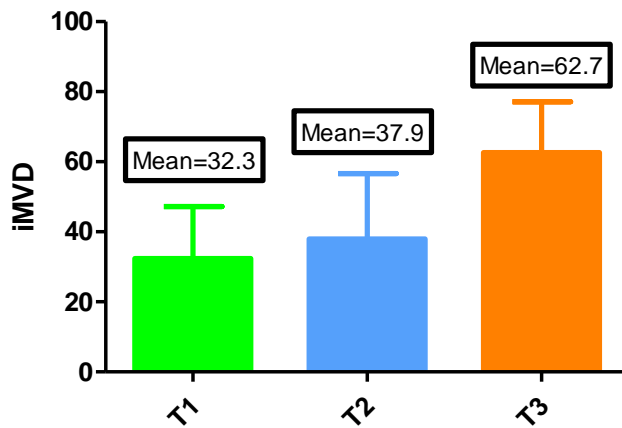


Figure 13: Intratumoural MVD according to tumour stage.

### 3.4. MVD and its correlation with the tumour grade

Regarding tumour grading, the numbers of patients with G1, G2, and G3 were 12, 26 and 23 respectively. The mean peritumoural MVD/0.74 mm<sup>2</sup> (SD) was 54.3 ( $\pm$ 9.60), 57.8 ( $\pm$ 4.01) and 61.9 ( $\pm$ 5.01) in G1, G2 and G3, respectively (ANOVA  $p=0.67$ ). The mean intratumoural MVD was 41.8 ( $\pm$ 7.36), 36.9 ( $\pm$ 3.39) and 39.3 ( $\pm$ 3.57) in G1, G2 and G3, respectively (ANOVA  $p=0.75$ ). Figures 14-21.

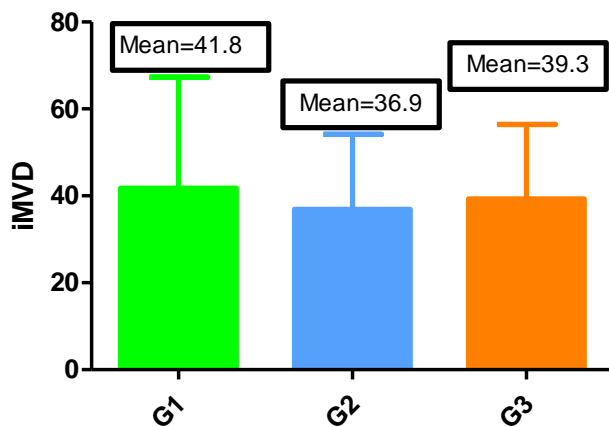


Figure 14: Intratumoural MVD according to tumour grade.

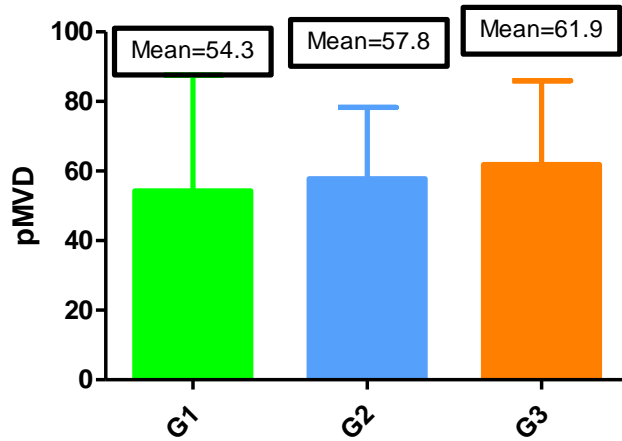


Figure 15: Peritumoural MVD according to tumour grade.

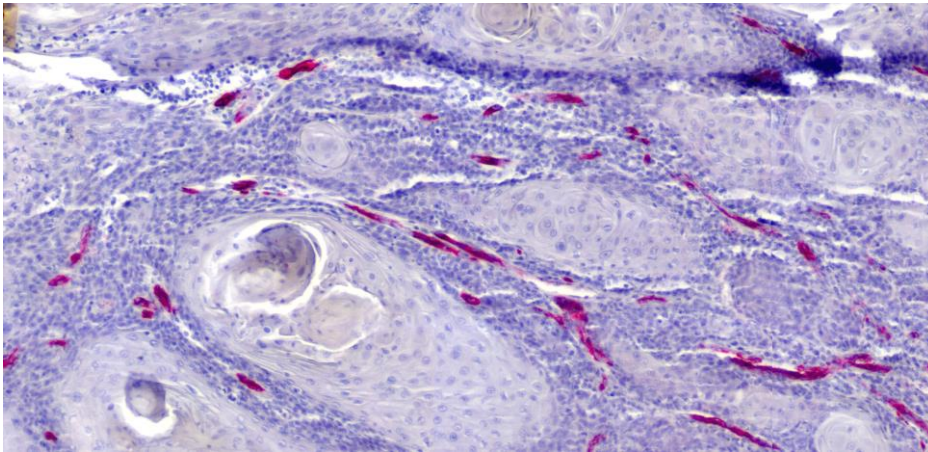


Figure16: Intratumoural MVD showed the expression of CD34 in well-differentiated squamous cell carcinoma (G1), the tumour cells resemble normal squamous epithelium and contain varying proportion of large differentiated keratinocyte-like squamous cells and always presence of intercellular bridges. Keratin pearls are frequently found with scanty mitosis.

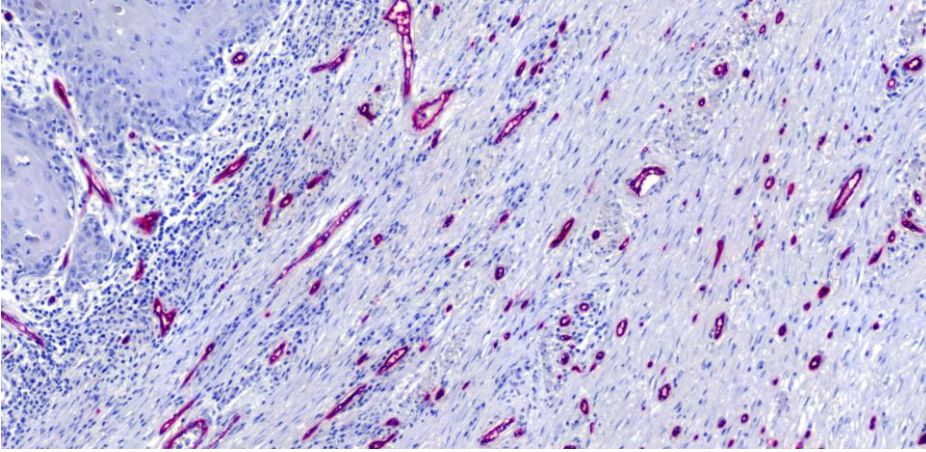


Figure 17: Peritumoral MVD showed the expression of CD34 in well-differentiated squamous cell carcinoma (G1).

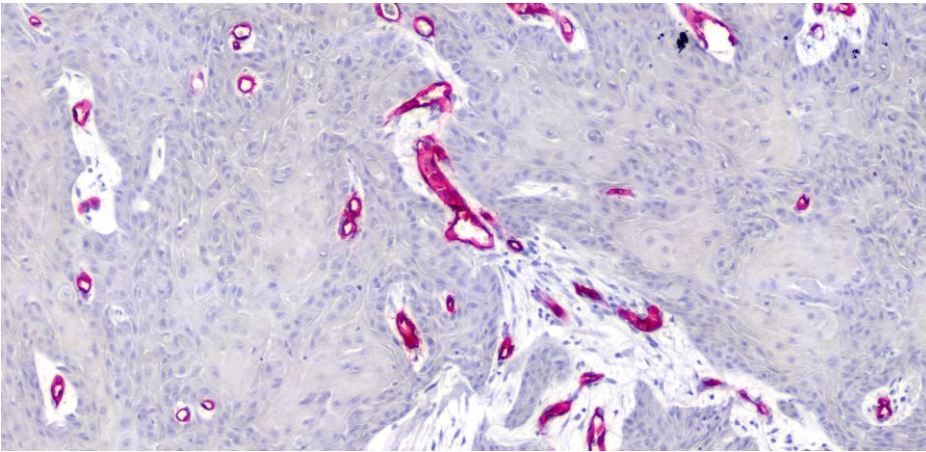


Figure18: Intratumoral MVD showed the expression of CD34 in moderately differentiated squamous cell carcinoma (G2), the tumor cells exhibit more nuclear pleomorphism and increased number of mitosis with less keratinization.

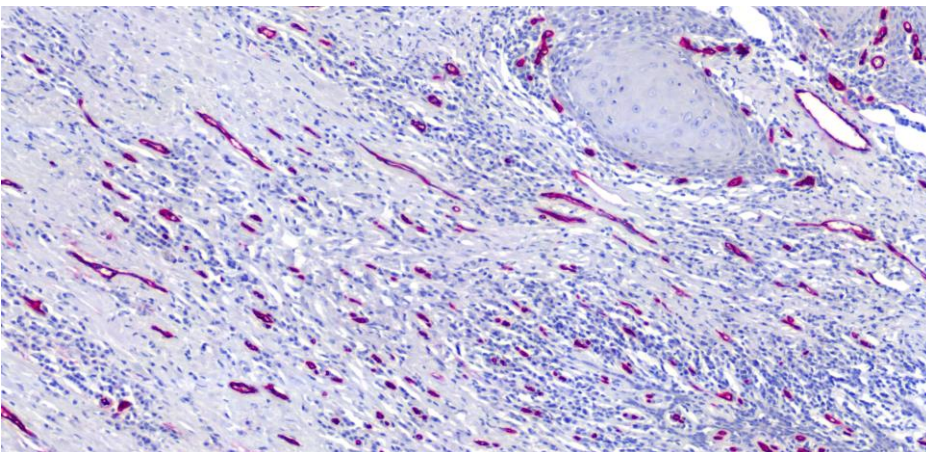


Figure19: Peritumoral MVD showed the expression of CD34 in moderately differentiated squamous cell carcinoma (G2).



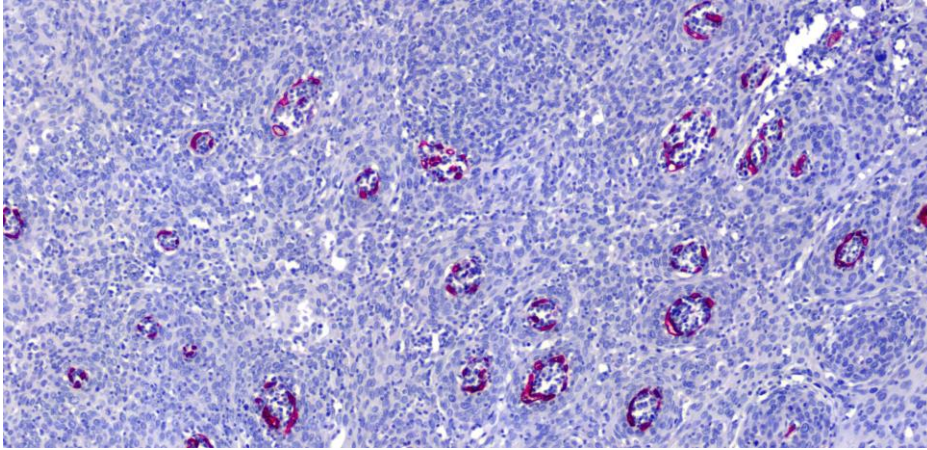


Figure 20: Intratumoral MVD in poorly differentiated squamous cell carcinoma (G3), the tumour cells are characterized by barely discernible intracellular bridges and loss of keratinization with high mitotic rate.

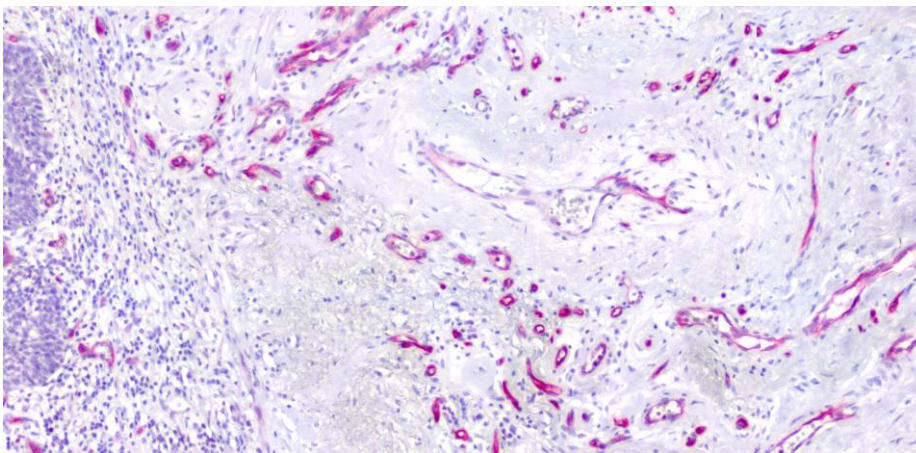


Figure 21: Peritumoral MVD showed the expression of CD34 in poorly differentiated squamous cell carcinoma (G3).

### 3.5. MVD and its correlation with risk groups

The EAU guidelines divide the patients into high, intermediate and low risk groups. The patients with high grade tumour (G3) or with involvement of the corpora ( $\geq T2$ ) and those with T1 G2 are classified as high and intermediate risk groups, respectively. The rest not setting in one of these groups are classified as low risk. The number of patients was 45, 10 and 6 in the high, intermediate, low risk group, respectively. The mean peritumoural MVD/0.74 mm<sup>2</sup> was 47.1, 61.6, and 59.6 in the low, intermediate, and high risk group respectively (ANOVA  $p= 0.47$ ). The mean intratumoural MVD/0.74 mm<sup>2</sup> was 33.5, 31.6 and 41.1 in the low, intermediate, high risk group, respectively (ANOVA  $p= 0.28$ ). Both

peritumoural and intratumoural MVD in this comparison are not statistically significant. Figures 22 and 23.

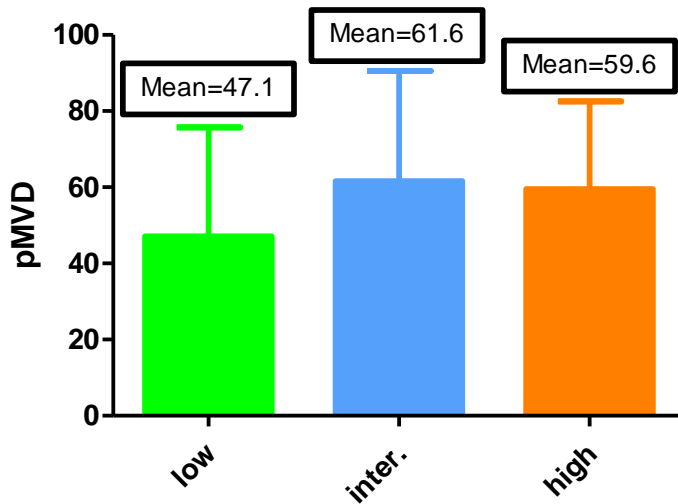


Figure 22: Peritumoural MVD according to EAU risk groups.

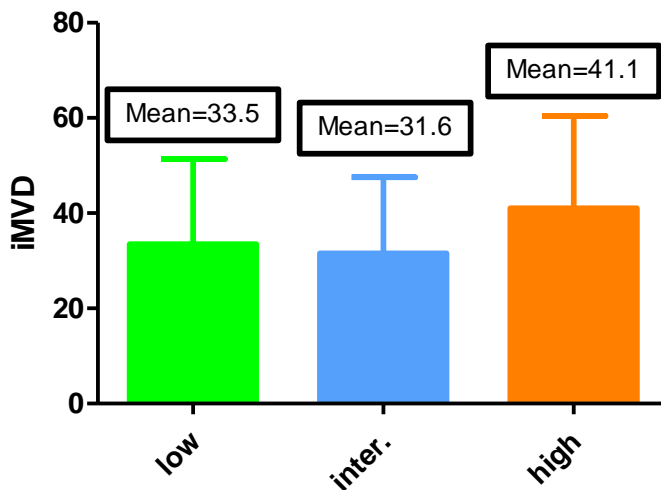


Figure 23: Intratumoural MVD according to EAU risk groups.

### 3.6. MVD and its correlation with inflammation

The number of patients with acute inflammatory cells (neutrophils, basophiles and eosinophiles granulocytes) associated with PSCC was 30, compared to 31 with chronic inflammatory cells (lymphocytes and plasma cells). The mean peritumoural MVD/0.74 mm<sup>2</sup> was 57.3 in chronic inflammation and 60.1 in acute inflammation (p value test = 0.66). The mean intratumoural MVD/0.74 mm<sup>2</sup> was 37.2 in chronic inflammation and 40.4 in acute inflammation (p value test = 0.52). Figures 24-27.

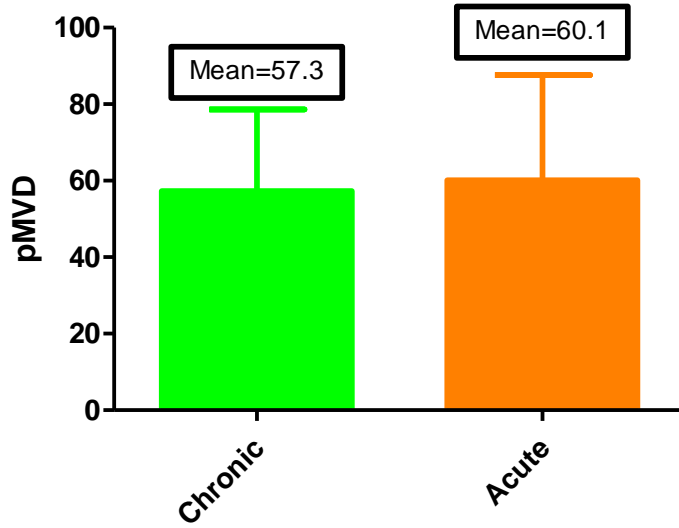


Figure 24: Peritumoural MVD in chronic and acute inflammation.

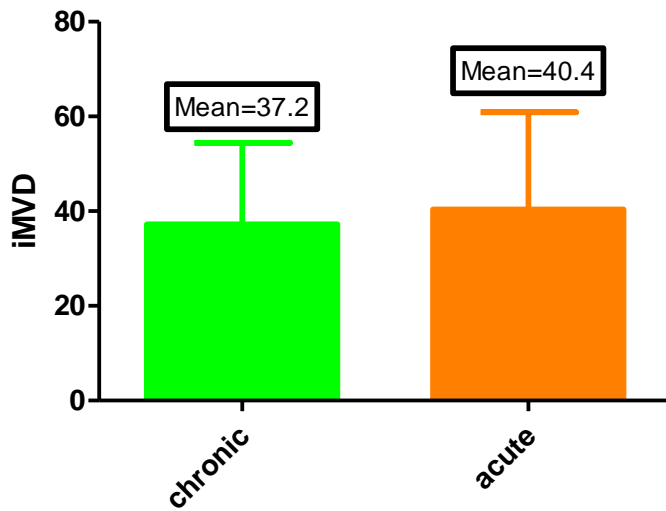


Figure 25: Intratumoural MVD in chronic and acute inflammation.

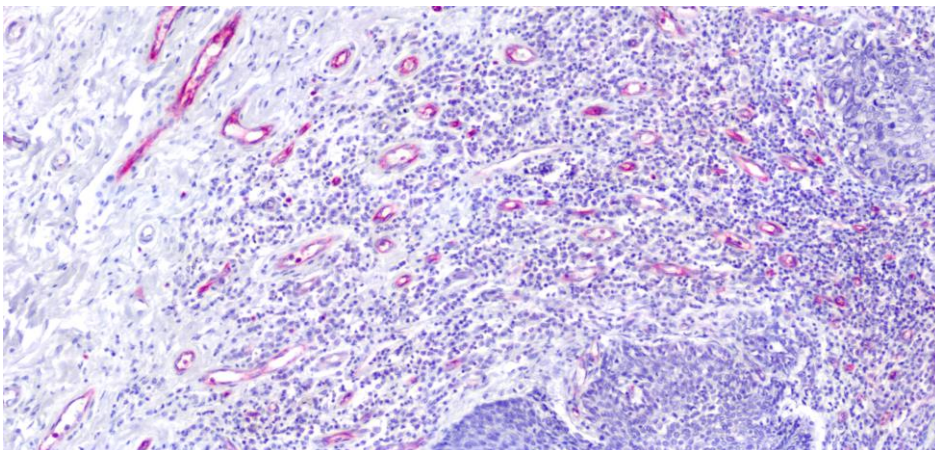


Figure 26: Acute inflammatory cells at the periphery of tumour cells.



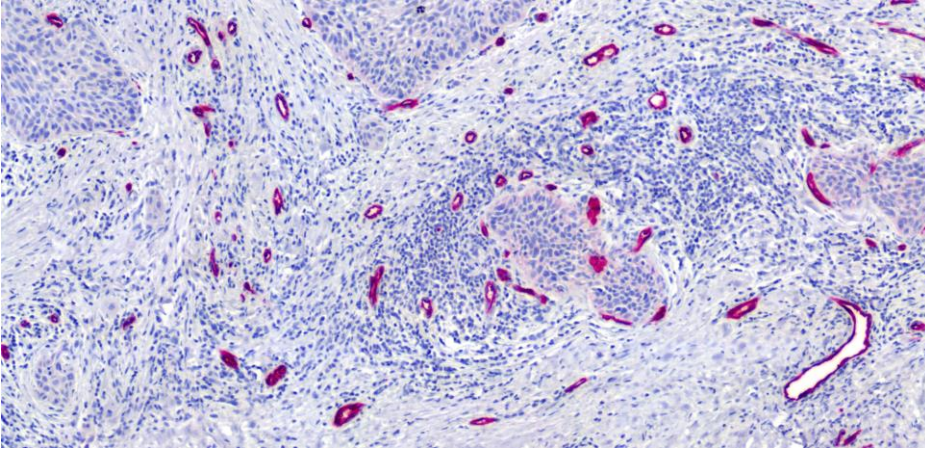


Figure 27: Neoplastic cells surrounded by chronic inflammatory cells.

### 3. 7. MVD and its correlation with patient survival

The overall survival was significantly higher in patients with a high peritumoural MVD (over the median) as compared to low MVD. The 5-year overall survival (OAS) was 75% and 30% for those with a high and low peritumoural MVD respectively (log-rank  $p=0.017$ ). Figure 28. No difference was noticed in the tumour with regard to low and high intratumoural MVD. The overall survival was 65.03% and 60.56% for those with high and low intratumoural MVD respectively (log-rank  $p=0.99$ ). Figure 28.

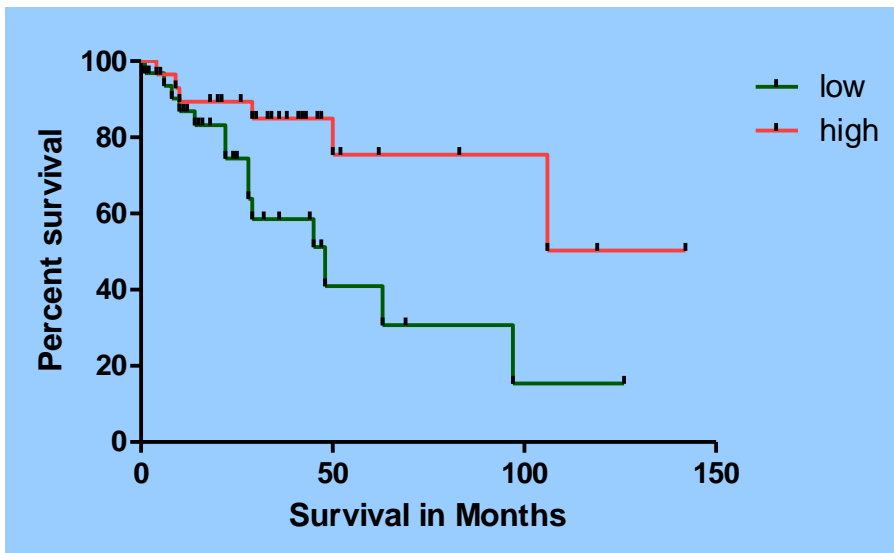


Figure 28: Kaplan Meier graphs showing the survival of patients with PSCC at and above the median pMVD. Patients with a higher pMVD had better 5-year survival rates of 75% compared to 30% for those with a low pMVD ( $p=0.017$  using log rank test).



## 4. Discussion

### 4.1. The dilemma in the diagnosis and treatment of occult lymph node metastases

The most common controversy in the treatment of PSCC focuses on the pathological lymph node (pN) status, which is considered a dilemma. The main reason behind this dilemma is the unreliability of clinical methods to detect lymph node metastasis at an early stage. With non-invasive methods occult metastasis cannot be detected, whether by physical examination, ultrasonography, CT or MRI. Up to 60% of patients presenting with PSCC have enlarged lymph nodes in the groin. In about 50% of them this is caused by metastatic invasion and in the other half by inflammatory reactions. In 20% of those patients presenting with no clinical signs of nodal metastasis, will develop metastasis later [11,13,43-45]. Therefore the presence, the extent and adequate therapy of inguinal lymph node metastases (LNMs) in patients with penile carcinoma are all crucial determinants of the survival rate [3]. Patients with penile carcinoma benefit from the early removal of occult LNM. However, lymph node dissection as a standard procedure in all patients often leads to unnecessary surgery, accompanied by increased morbidity rates [46,47]. Up to date there is no non-invasive or minimally invasive staging technique that can determine the lymph node status of penile cancer patients with 100% accuracy. In order to reduce the number of unnecessary lymph node dissections, several attempts have been made to predict nodal involvement in the squamous cell carcinoma (SCC) of the penis. These attempts involve sentinel lymph node (SLN) biopsy, which involves subjecting patients with penile carcinoma to lymphangiography to detect the anatomical position of one or more of lymph node metastases. This method remains the best minimally invasive staging modality [48,49], however, it is expensive and not available in all urological centres.

A predictor for the presence of lymph node metastases may be deduced from tumor characteristics other than tumour stage and tumour grade categories. Risk factors of lymph node metastases identified from retrospective studies of PSCC include pathological subtype, perineural invasion, lymphovascular invasion, tumour depth or thickness, anatomical site, size and growth pattern, depth of invasion, positive surgical margins and urethral invasion [50]. The most important adverse pathological prognostic factors associated with lymph node metastasis appear to be perineural invasion, vascular invasion and a high histological grade [12]. Histopathological staging and grading of penile SCC are important in characterizing the malignant and metastatic potential of this rare tumour [51]. Therefore, we tried to find a

possible mechanism in this study to predict tumour-aggressiveness through the assessment of angiogenesis by using microvessel density (MVD) of the primary tumour. According to our knowledge, the role of angiogenesis in PSCC has never been discussed and this is the first translational study to report a correlation between MVD and the outcome in PSCC using a fully automated method for vessel counting with defined inclusion criteria. A commonly used surrogate parameter of angiogenesis is the microvessel density, i.e. the number of blood vessels counted in a given area of tissue.

#### **4.2. Correlation between microvessel density and survival**

In genitourinary tumours a high MVD was a predictor of poor outcome in certain tumours, including carcinoma of the bladder [52], prostate [53], kidney [54] and tumours of the testes [55]. However, this is not universally the case and some studies have found no significant correlation between MVD and outcome [56,57], while others found that a high MVD correlated with a better outcome in carcinoma of the kidney and urinary bladder [58,59]. Although most studies have demonstrated that there is an inverse relationship between tumour vascularity and patient survival in various types of tumours, there are also conflicting reports regarding the relationship between the two. Inconclusive results have been published not only on the level of different urological tumours but also on the level of squamous cell carcinoma of head and neck, and uterine cervix [60-75]. Thus, until now the correlation between MVD and survival in patients with squamous cell carcinoma is also still controversial.

In our study the numbers of patients with lymph node metastasis were 30 compared to 31 cases with no metastasis. The mean peritumoural MVD in specimens of patients with lymph node metastasis /0.74mm<sup>2</sup> (SD) was 57.30 ( $\pm$ 3.93) and 66.59 ( $\pm$ 7.45) in those without lymph node metastasis, respectively (t test p= 0.23). Similarly, the mean intratumoural MVD showed no difference in both groups 38.88 ( $\pm$ 3.06) and 44.72 ( $\pm$ 5.78) respectively (t test p= 0.331). We found no correlation between lymph node metastasis and MVD neither intratumourally nor peritumourally. This may be due the tumour tendency to invade the lymph vessel before the blood vessel. Naumann et al. studied the lymph vessel density (LVD) in the squamous cell carcinoma of the penis as a possible mechanism responsible for LNM. The authors concluded that increased LVD does not significantly affect the lymphatic spread in penile carcinomas and that there is no correlation between LVD in penile SCC and tumour stage, differentiation or prognosis of patients [76].

The overall survival was significantly higher in patients with a high peritumoral MVD (over the median) as compared to low MVD. The 5-year overall survival (OAS) was 75% and 30 %

for those with a high and low peritumoural MVD, respectively (log rank  $p= 0.017$ ). This result may be related to the unique biological vascularity of the penis, and the tumour itself is almost always associated with inflammation. The continuous exposure of tumour to body immune system in the form of lymphocytes and plasma cells response could reduce the tumour aggressiveness. No difference was noticed for OAS with regard to low and high intratumoural MVD. The overall survival was 65.03% and 60.56% for those with high and low intratumoural MVD respectively (log rank  $p= 0.99$ ). In a study of Ranieri et al. assessed MVD using CD34 in head and neck squamous cell carcinoma. These results measured the MVD within the tumour, and no data were reported about the peritumoral field. The data showed a better survival for patients with high intratumoral MVD [60]. Furthermore, Zätterström et al. showed that the degree of vascularisation in cases of a primary squamous cell carcinoma of the head and neck was associated with a better survival. The authors reported no correlation between MVD and TNM stage, clinical stage, and histological grade [61]. Other studies reported a higher MVD to be seen with increasing T and N stages in patients with head and neck SCC [62]. On the other hand, Kyzas et al. showed that high MVD and VEGF expression were associated with a worse overall survival and high clinical stage in specimens with HNSCC as well as no correlation with the lymph node metastasis was noticed [63]. Rubio et al. detected in nasopharyngeal carcinoma patients no statistical differences between clinicopathological variables and microvessel number. As a result, angiogenesis can be seen as an independent prognostic factor beside tumoural type, size and stage, as well as beside metastasis, sex and age of patients [64]. Therefore, inconclusive results have been published about the role of MVD in head and neck squamous cell carcinoma (HNSCC). These inconsistencies are most likely to be explained by the heterogeneity in the populations studied, the antibody detection method, quantification methods, and the treatment modalities employed.

In squamous cell carcinoma of uterine cervix, conflicting results have been reported. Randall et al. showed in patients with stage IB uterine cervix SCC, that the 5-year survival rate for women with high MVD was 90% versus 63% in women with low MVD [65]. Additional study has supported these findings [66]; however, high MVD has also been shown to be associated with improved survival [67] or to not correlate with the outcome at all [68]. These authors reported the simultaneous quantification and analysis of two separate markers of MVD in the same patient cohort. These data showed that CD31 MVD was significantly associated with an improvement in both patient free survival and overall survival (OAS) independent of prognostic clinical covariates. Triratanachat et al. found MVD was not a poor

prognostic parameter in frankly invasive cervical carcinoma, stage >IA [69], which also confirms our results. However, Rutgers et al. found no correlation between the main vessel count and stage or vessel count and prognosis in stage I-IV carcinoma [68]. They concluded that with a power of approximately 70%, the study excludes the hypothesis that an increased microvessel density is associated with a worsened prognosis in cervical SSC. Wiggins et al. showed that there was no correlation between microvessel count and node status, parametrial involvement, depth of invasion, or gross disease. Microvessel count was significantly correlated with vascular space involvement [70]. Kainz et al. compared stage IB with stage IIB and similarly found no correlation between angiogenesis and tumour stage [71]. Obermair et al. reported worse outcome in women with high tumour MVD [72]. Vieira et al. found that microvessel density was higher in undifferentiated carcinomas. Their study suggested that anti-CD34 antibody reactivity in cervical carcinoma was associated with pathoanatomical features indicative of poorer prognosis [73].

Discrepancies in the prognostic significance of MVD can be explained, in part, by different endothelial markers utilized (CD34, CD31, FVIII, CD105 and CD146). The endothelium of tumour and normal tissues is heterogeneous. Thus, pan-endothelial antibodies may not stain tumour vessels to the same degree and may generally react better with larger vessels. The immunohistochemical detection of tumour-associated microvessels has most commonly been performed by using anti von Willbrand Factor (anti-vWF) antibodies directed against the endothelial membranes. The antibodies against vWF give good staining of endothelial cells in large blood vessels and may provide sufficient information on patient prognosis, however, vWF is present in diminished quantities or even absent from some microvessels in normal tissues and from many microvessels in tumours. Moreover, vWF is also present on lymphatic endothelium. Variability in staining and cross-reactivity with other antigens may produce equivocal results. Recent reports have stated that an anti-CD34 antibody gave consistent and reproducible staining and did not exhibit the problems inherent to vWF staining [73]. Staining for CD34 is both more sensitive and more specific than that for vWF, and is easy to interpret, because the anti-CD34 antibody does not have any cross reactivity with stroma. Moreover, the microvessel count using CD34 staining was three to four times higher than that using vWF, because CD34 identifies the small caliber microvessels associated with neovascularization more efficiently than vWF. Thus, microvessels stained with anti-CD34 antibodies may provide more usable and reliable information than those stained for vWF [41].

Additional factors that may have impact on the discrepancies in the prognostic significance of MVD could be the variability in the choice of hotspots and the method of vessel counting (manual vs. automated) as well as the organ involved. Another factor to be considered is the tumour neovascularisation, which is a dynamic pathophysiological process. The sequence of actions requires quantitative, non-invasive and repeatable assays to estimate the functional angiogenic activity of the tumour.

#### **4.3. Morphology of intratumoural and peritumoural microvessel density**

In this study we have found that MVD increased in the peritumoural area more than within the tumour itself. These examination results of the intratumoural CD34-stained vessels revealed smaller, collapsed or narrower lumen than in the peritumoural present vessels. These observations mirror the results of animal studies, which have shown compression of the intratumoural vessels than the vessels present peritumoural because of high interstitial pressure [74].

#### **4.4. Correlation between microvessel density and risk group of patients with histopathologic parameters**

We have found that the mean peritumoural MVD in low, intermediate and high risk groups was 47.1, 61.6 and 59.6, respectively (ANOVA  $p= 0.47$ ). The mean intratumoural MVD in low, intermediate and high risk groups was 33.5, 31.6, and 41.1, respectively (ANOVA  $p= 0.28$ ). These results showed no statistical significance with respect to the correlation between intra- and peritumoural MVD and different patients risk groups.

We have found intratumoural microvessel density and peritumoural microvessel density increased with increasing tumour stages. The mean peritumoural and intratumoural MVD as compared to the T stage was with an increasing tendency from T1 to T2 and higher in specimens with T3. We could not find a statistically significant relationship between MVD and tumour stage. Our results correlate with the results reported by Lopes et al. The authors showed that MVD was not influenced by the pathological stage and histological grade of the primary tumour [75].

Regarding the tumour grade, we have found that the mean peritumoural MVD was 54.3, 57.8 and 61.9 in G1, G2 and G3, respectively (ANOVA  $p= 0.67$ ). The mean intratumoural MVD was 41.8, 36.9 and 39.3 in G1, G2 and G3, respectively (ANOVA  $p= 0.75$ ). Maiolino et al. [77] evaluated microvessel density in canine cutaneous squamous cell carcinomas. The authors noted that MVD progressively increased from more-differentiated (Grade I) to poorly-

differentiated (Grade IV). Bowden et al. showed VEGF was expressed in cutaneous squamous cell carcinoma of the head and neck, and it was significantly associated with the degree of tumor differentiation [78]. These results agree with our results.

We also have found that the mean peritumoural MVD was in chronic inflammation 57.3 and in acute inflammation 60.1 ( $p= 0.66$ ). The mean intratumoural MVD was in chronic inflammation 37.2 and in acute inflammation 40.4 ( $p= 0.52$ ). We have found no statistical significance in correlation between peritumoural and intratumoural MVD and inflammation. All investigated specimens of PSCC were associated with either acute or chronic inflammation. Ono Y. et al. suggested that Tumor-associated tissue eosinophilia improves the survival of patients with advanced penile cancer [79]. In 1979, Mihatsch et al. were the first to report a significantly better 1-year survival when lymphocytes, plasma cells and/or lymph follicles were present in invasive carcinoma of the bladder [80]. In another study in urothelial carcinoma, Offersen et al. [59] showed a survival advantage for patients with intense inflammation in their tumours with a correlation to significantly increased vascular density. MVD was very closely associated to the degree of inflammation and even represented an independent parameter for better survival using overall death as the end-point. The survival advantage was described to reflect a host versus tumour response, which could reflect the ability of the patient to mount an immune response.

In our study, all other correlations between MVD and histopathologic parameters, as tumour stage, grade and association with acute or chronic inflammation in the tumor itself or tumour boundaries, revealed no significant values ( $p> 0.05$ ).

## 5. Conclusion

Although SCC of the penis is a rare neoplasm in most countries of the western world, the main clinical and pathological prognostic status of lymph node is well known. Contemporary imaging modalities are unable to detect clinically occult metastasis resulting from penile carcinoma. Only invasive procedures are capable of reliably the presence of lymph node metastasis, therefore lymphadenectomy plays a paramount role in treating the metastatic penile carcinoma. Unfortunately the timing of lymphadenectomy in clinically node-negative patients is often a choice between unnecessary and overtreatment.

Our results show that survival of patients with PSCC was associated with higher peritumoural MVD values with a 5-year OAS of 75% vs. 30% with low peritumoural MVD. This result may be related to the unique biological vascularity of the penis; moreover, the tumour is almost always associated with inflammation, thus the continuous exposure of the tumour to increased blood circulation is also associated with host lymphocytes and plasma cell response. This may lead to a persistent defence and withstanding of immune system against the tumour cells. The fact that there is no significant difference between MVD in metastatic and non-metastatic PSCC might indicate that not the absolute number of tumour microvessels, but the proliferative and neovascularized tumour areas are of particular interest.

Furthermore, in this work, the pan-endothelial marker CD34 was used to highlight the blood vessels. However, this marker is limited by its inability to distinguish between active and resting angiogenic vessels. We conclude that MVD is a prognostic factor in patients with PSCC, while the use of specific vascular proliferation markers would permit a distinction between active and resting endothelial cells. Nevertheless, further studies are required to improve the understanding of the metastatic mechanisms of PSCC.

## 6. References

1. Goldblum JR, Zhou M, Magi-Galluzz C (2007): Genitourinary pathology (a volume in the foundations in diagnostic pathology series), 1st Edition, Churchill Livingstone Elsevier, Philadelphia, USA.
2. Pizzocaro G, Algaba F, Horenblas S, Solsona E, Tana S, Van Der Poel H, Watkin NA: EAU Penile Cancer Guidelines 2009. *Eur Urol* 2010;57(6):1002-1012.
3. Culkin DJ, Beer TM: Advanced penile carcinoma. *J Urol* 2003;170:359-365.
4. Barnholtz-Sloan JS, Maldonado JL, Pow-sang J, Giuliano AR: Incidence trends in primary penile cancer. *Urol Oncol* 2007;25(5):361-367.
5. ENCR (European Network of Cancer Registries). Eurocim version 4.0. European incidence database V2.2 (1999). Lyon, France: IARC, 2001.
6. Mills ES, Carter D, Greenson JK, Reuter EV, Stoler HM (2010): Sternberg's Diagnostic Surgical Pathology, 5th Edition, Wolters Kluwer, Lippencott Williams & Wilkins, Philadelphia. Baltimore. New York. London. Buenos Aires. Hong Kong. Sydney. Tokyo.
7. DeVita, Hellman, and Rosenberg's (2008): Cancer principles and practice of Oncology, 8th edition, Wolters Kluwer, Lippencott Williams & Wilkins, Philadelphia. Baltimore. New York. London. Buenos Aires. Hong Kong. Sydney. Tokyo.
8. Heideman DA, Waterboer T, Pawlita M, et al: Human papillomavirus-16 is the predominant type etiologically involved in penile squamous cell carcinoma. *Clin Oncol* 2007;25: 4550-4556.
9. Wein JA, Kavoussi RL, Novick CA, Partin WA, Peter AC (2006): Campbell-Walsh Urology, 9th edition, Elsevier Saunders, USA.
10. Eble J, Sauter G, Epstein JI (2004): World Health Organization Classification of Tumors. Pathology and Genetics of Tumours of the Urinary System and Male Genital Organs. Lyon: International Agency for Research on Cancer (IARC).
11. Theodorescu D, Russo P, Zhang ZF, Morash C, Fair WR: Outcomes of initial surveillance of invasive squamous cell carcinoma of the penis and negative nodes. *J Urol* 1996;155:1626-1631.
12. Ornellas AA, Seixas AL, Marota A, Wisnesky A, Campos F, de Moraes JR: Surgical treatment of invasive squamous cell carcinoma of the penis: retrospective analysis of 350 cases. *J Urol* 1994;151:1244-1249.
13. Abi-Aad AS, deKernion JB: Controversies in ilioinguinal lymphadenectomy for cancer of the penis. *Urol Clin North Am* 1992;19:319-324.



14. Solsona E, Iborra I, Rubio J, Casanova JL, Ricós JV, Calabuig C: Prospective validation of the association of local tumor stage grade as a predictive factor for occult lymph node micrometastasis in patients with penile carcinoma and clinically negative inguinal lymph nodes. *J Urol* 2001;165(5):1506-1509.
15. Kroon BK, Horenblas S, Deurloo EE, Nieweg OE, Teertstra HJ: Ultrasonography-guided fine needle aspiration cytology before sentinel node biopsy in patients with penile carcinoma. *BJU Int* 2005;95(4):517-521.
16. Catalona WJ: Modified inguinal lymphadenectomy for carcinoma of the penis with preservation of saphenous veins: technique and preliminary results. *J Urol* 1988;140(4):306-310.
17. Pettaway CA, Pisters LL, Dinney CPN, Jularbal F, Swanson DA, von Eschenbach AC, Ayala A: Sentinel lymph node dissection for penile carcinoma: the M.D. Anderson Cancer Center Experience. *J Urol* 1995;154(6):1999-2003.
18. Perdonà S, Gallo L, Claudio L, Marra L, Gentile M, Gallo A: Role of crural inguinal Lymphadenectomy and dynamic sentinel lymph node biopsy in lymph node staging in squamous-cell carcinoma of the penis. *Tumori* 2003;89(4):276-279.
19. Mueller-Lisse UG, Scher B, Scherr MK, Seitz M: Functional imaging in penile cancer: PET/computed tomography, MRI, and sentinel lymph node biopsy. *Curr Opin Urol* 2008;18(1):105-110.
20. Scher B, Seitz M, Albinger W, Reiser M, Schlenker B, Stief C, Mueller-Lisse U, Dresel S: Value of PET and PET/CT in the diagnostics of prostate and penile cancer. *Recent Results Cancer Res* 2008;170:159-179.
21. Horenblas S: Lymphadenectomy for squamous cell carcinoma of the penis. Part 2: The role and technique of lymph node dissection. *BJU International* 2001;88:473-483.
22. Pizzocaro G, Piva L, Nicolai N: Treatment of lymphatic metastasis of squamous cell carcinoma of the penis: experience at the National Tumor Institute of Milan. *Arch Ital Urol Androl* 1996;68(3):169-172.
23. Naumann CM, Alkatout I, Al-Najar A, Korda JB, Hegele A, Bolenz C, Ziegler H, Klöppel G, Juenemann KP, van der Horst C: Lymph-node metastases in intermediate-risk squamous cell carcinoma of the penis. *BJU Int* 2008;102(9):1102-1106.
24. Zhu Y, Zhang SL, Ye DW, Yao XD, Jiang ZX, Zhou XY: Predicting pelvic lymph node metastases in penile cancer patients: a comparison of computed tomography, Cloquet's node, and disease burden of inguinal lymph nodes. *Onkologie* 2008;31(1-2):37-41.

25. Kroon BK, Horenblas S, Estourgie SH, Lont AP, Valdes Olmos RA, Nieweg OE: How to avoid false negative dynamic sentinel node procedures in penile carcinoma. *J Urol* 2004;171:2191-2194.
26. Perdonà S, Autorino R, Gallo L, Di Lorenzo G, Cascini GL, Lastoria F, Marra L, De Sio M, Damiano R, Gallo A: Role of dynamic sentinel node biopsy in penile cancer. *J Surg Oncol* 2006;93(3):181-185.
27. Preis E, Jakse G: The significance of inguinal lymphadenectomy in carcinoma of the penis. *Urologe* 2006;45(4):176-180.
28. Lont AP, Kroon BK, Gallee MP, van Tinteren H, Moonen LM, Horenblas S: Pelvic lymph node dissection for penile carcinoma: extent of inguinal lymph node involvement as an indicator for pelvic lymph node involvement and survival. *J Urol* 2007;177(3):947-952.
29. Lopes A, Bezerra AL, Serrano SV, Hidalgo GS: Iliac nodal metastases from carcinoma of the penis treated surgically. *BJU Int* 2000;86(6):690-693.
30. Folkman J: What is the evidence that tumors are angiogenesis dependent? *J Natl Cancer Inst* 1990;82:4-6.
31. Reinmuth N, Parikh AA, Ahmad SA, Liu W, Stoeltzing O, Fan F, Takeda A, Akagi M, Ellis LM: Biology of angiogenesis in tumors of the gastrointestinal tract. *Microsc Res Tech* 2003;60:199-207.
32. Weidner N, Semple JP, Welch WR, Folkman J: Tumor angiogenesis and metastasis-correlation in invasive breast carcinoma. *N Engl J Med* 1991;324:1-8.
33. Xiangming C, Hokita S, Natsugoe S, Tanabe G, Baba M, Takao S, Kuroshima K, Aikou T: Angiogenesis as an unfavourable factor related to lymph node metastasis in early gastric cancer. *Ann Surg Oncol* 1998;5:585-589.
34. Linder S, Blasjo M, von Rosen A, Parrado C, Falkmer UG, Falkmer S: Pattern of distribution and prognostic value of angiogenesis in pancreatic duct carcinoma: a semiquantitative immunohistochemical study of 45 patients. *Pancreas* 2001;22(3):240-247.
35. Underiner TL, Ruggeri B, Gingrich DE: Development of vascular endothelial growth factor receptor (VEGFR) kinase inhibitors as anti-angiogenic agents in cancer therapy. *Curr Med Chem* 2004;11:731-745.
36. Schimming R, Marme D: Endoglin (CD105) expression in squamous cell carcinoma of the oral cavity. *Head Neck* 2002;24:151-156.
37. Uzzan B, Nicolas P, Cucherat M: Microvessel density as a prognostic factor in women with breast cancer: a systematic review of the literature and metaanalysis. *Cancer Res* 2004;64:2941-2955.

38. Krause DS, Fackler MJ, Civin CI, May WS: CD34 structure, biology, and clinical utility. *Blood* 1996;87:1-13.
39. Civin CI, Strauss LC, Fackler MJ, Trischmann TM, Wiley JM, Loken MR: Positive stem cell selection - basic science. *Prog Clin Biol Res* 1990;333:387-402.
40. Kuzu I, Bicknell R, Harris AL, Jones M, Gatter KC, Mason DY: Heterogeneity of vascular endothelial cells with relevance to diagnosis of vascular tumors. *J Clin Pathol* 1992;(45)143-148.
41. Vermeulen PB, Gasparini G, Fox SB: Quantification of angiogenesis in solid human tumours: an international consensus on the methodology and criteria of evaluation. *Eur J Cancer* 1996;32(14):2474-2484.
42. Sobin LH, Wittekind C (2002): *TNM Classification of Malignant Tumors*, 6th ed. New York. Wiley-Liss.
43. Ayyappan K, Ananthakrishnan N, Sankaran V: Can regional lymph node involvement be predicted in patients with carcinoma of the penis? *Br J Urol* 1994;73:549-553
44. Solsona E, Iborra I, Ricos JV: Corpus cavernosum invasion and tumour grade in the prediction of lymph node condition in penile carcinoma. *Eur Urol* 1992;22:115-118.
45. Horenblas S: Lymphadenectomy for squamous cell carcinoma of the penis. Part 1: diagnosis of lymph node metastasis. *BJU Int* 2001;88:467-472.
46. Kroon BK, Horenblas S, Lont AP, Tanis PJ, Gallee MPW, Nieweg OE: Patients with penile carcinoma benefit from immediate resection of clinically occult lymph node metastases. *J Urol* 2005;173:816-819.
47. Nauman CM, van der Horst C, Volkmer B, Kurtz F, Portillo MFJ, Seif C, Hautmann S, Braun PM, Hautmann R, Jünemann KP: The influence of T stage on the risk of metastasis of penis cancer: T1 vs. T2. *Urologe* 2006;45:1424-1430.
48. Naumann CM, Hamann MF, Wefer B, Kaufmann S, Al Najjar A, Seif C, Braun PM, Hautmann S, Jünemann KP, van der Horst C: 30 Years of sentinel lymph node diagnostic in penile carcinoma. Development of a diagnostic procedure and current results. *Urologe* 2007;46(11):1514-1518.
49. Hughes B, Leijte J, Shabbir M, Watkin N, Horenblas S: Non-invasive and minimally invasive staging of regional lymph nodes in penile cancer. *World J Urol* 2009;27(2):197-203.
50. Cubilla AL: The role of pathologic prognostic factors in squamous cell carcinoma of the penis. *World J* 2009;27(2):169-177.

51. Alkatout I, Naumann CM, Hedderich J, Hegele A, Bolenz C, Jünemann KP, Klöppel G: Squamous cell carcinoma of the penis: Predicting nodal metastases by histologic grade, pattern of invasion and clinical examination. *Urol Oncol* 2011;29(6):774-781
52. Hawke CK, Delahunt B, Davidson PJ: Microvessel density as a prognostic marker for transitional cell carcinoma of the bladder. *Br J Urol* 1998;81:585-590.
53. Bettencourt MC, Bauer JJ, Sesterhenn IA: CD34 immunohistochemical assessment of angiogenesis as a prognostic marker for prostate cancer recurrence after radical prostatectomy. *J Urol* 1998;160:459-465.
54. Yoshino S, Kato M, Okada K: Evaluation of the prognostic significance of microvessel count and tumor size in renal cell carcinoma. *Int J Urol* 1998;5:119-123.
55. Fukuda S, Shirahama T, Imazono Y: Expression of vascular endothelial growth factor in patients with testicular germ cell tumors as an indicator of metastatic disease. *Cancer* 1999;85:1323-1330.
56. Dinney CP, Babkowski RC, Antelo M: Relationship among cystectomy, microvessel density and prognosis in stage T1 transitional cell carcinoma of the bladder. *J Urol* 1998;160:1285-1290.
57. Rubin MA, Buyyounouski M, Bagiella E, et al: Microvessel density in prostate cancer: lack of correlation with tumor grade, pathologic stage, and clinical outcome. *Urology* 1999;53:542-547.
58. Delahunt B, Bethwaite PB, Thornton A: Prognostic significance of microscopic vascularity for clear cell renal cell carcinoma. *Br J Urol* 1997;80:401-404.
59. Offersen BV, Knap MM, Marcussen N, Horsman MR, Hamilton-Dutoit S, Overgaard J: Intense inflammation in bladder carcinoma is associated with angiogenesis and indicates good prognosis. *Br J Cancer* 2002;12:1422-1430.
60. Ranieri G, Labriola A, Achille G: Microvessel density, mast cell density and thymidine phosphorylase expression in oral squamous carcinoma. *Int J Oncol* 2002;21:1317-1323.
61. Zätterström UK, Brun E, Willén R: Tumor angiogenesis and prognosis in squamous cell carcinoma of the head and neck. *Head Neck* 1995;17:312-318.
62. Erovic BM, Neuchrist C, Berger U: Quantitation of microvessel density in squamous cell carcinoma of the head and neck by computer-aided image analysis. *Wien Klin Wochenschr* 2005;117:53-57.
63. Kyzas PA, Stefanou D, Batistatou A: Prognostic significance of VEGF immunohistochemical expression and tumor angiogenesis in head and neck squamous cell carcinoma. *J Cancer Res Clin Oncol* 2005;131:624-630.

64. Rubio L, Burgos JS, Morera C, Vera-Sempere FJ: Morphometric study of tumor angiogenesis as a new prognostic factor in nasopharyngeal carcinoma patients. *Pathol Oncol Res.* 2000;6(3):210-216.
65. Randall LM, Monk BJ, Darcy KM, Tian C, Burger RA, Liao SY, Peters WA, Stock RJ, Fruehauf JP: Markers of angiogenesis in high-risk, early-stage cervical cancer: A Gynecologic Oncology Group study. *Gynecol Oncol.* 2009;112(3):583-589.
66. Dellas A, Moch H, Schultheiss E: Angiogenesis in cervical neoplasia: microvessel quantitation in precancerous lesions and invasive carcinomas with clinicopathological correlations. *Gynecol Oncol* 1997;67:27-33.
67. West CM, Cooper RA, Loncaster JA: Tumor vascularity: a histological measure of angiogenesis and hypoxia. *Cancer Res* 2001;61:2907-2910.
68. Rutgers JL, Mattox TF, Vargas MP: Angiogenesis in uterine cervical squamous cell carcinoma. *Int J Gynecol Pathol* 1995;14:114-118.
69. Triratanachat S, Niruthisard S, Trivijitsilp P, Tresukosol D, Jarurak N: Angiogenesis in cervical intraepithelial neoplasia and early-staged uterine cervical squamous cell carcinoma: clinical significance. *Int J Gynecol Cancer.* 2006;16(2):575-580.
70. Wiggins DL, Granai CO, Steinhoff MM, Calabresi P: Tumor angiogenesis as a prognostic factor in cervical carcinoma. *Gynecol Oncol* 1995;56:353-356.
71. Kainz C, Speiser P, Wanner C, et al: Prognostic value of tumour microvessel density in cancer of the uterine cervix stage IB to IIB. *Anticancer Res* 1995;15:1549-1551.
72. Obermair A, Wanner C, Bilgi S: Tumor angiogenesis in stage IB cervical cancer: correlation of microvessel density with survival. *Am J Obstet Gynecol* 1998;178:314-319.
73. Vieiraa SC, Silva BB, Pinto GA, Vassallo J, Moraes NG, Santana JOI, Santos LG, Carvasand GAF, Zeferino LC: CD34 as a marker for evaluating angiogenesis in cervical cancer. *Pathol Res and Prac* 2005;201:313-318.
74. Leu AJ, Berk DA, Lymboussaki A: Absence of functional lymphatics within a murine sarcoma: A molecular and functional evaluation. *Cancer Res* 2000;60:4324-4327.
75. Lopes A: Prognostic factors in carcinoma of the penis: multivariate analysis of 145 patients treated with amputation and lymphadenectomy. *J Urol* 1996;156:1637-1642.
76. Naumann CM, Al-Najar A, Alkatout I, Hegele A, Korda JB, Bolenz C, Kalthoff H, Sipos B, Juenemann KP, van der Horst C: Lymphatic spread in squamous cell carcinoma of the penis is independent of elevated lymph vessel density. *BJU Int* 2009;103(12):1655-1659.

77. Maiolino P, Papparella S, Restucci B, De Vico G: Angiogenesis in squamous cell carcinomas of canine skin: an immunohistochemical and quantitative analysis. *J Comp Pathol* 2001;125:117-121.
78. Bowden J, Brennan PA, Tijjani U, Cronin A: Expression of vascular endothelial growth factor in basal cell carcinoma and cutaneous squamous cell carcinoma of the head and neck. *J Cutan Pathol* 2002;29:585-589.
79. Ono Y, Osawa M, Tamura Y, Suzuki T, Suzuki K, Kurokawa K: Tumor-associated tissue eosinophilia of penile cancer. *Int J Urol* 2002;9:82-87.
80. Mihatsch MJ, Rist M, Romppanen T, Rutishauser G: Prognostic significance of peritumoural inflammation in invasive urothelial bladder carcinoma. *Urol Res* 1979;22:7:97-102.

## **8. Acknowledgement**

I would like especially to thank my supervisor PD Dr. med. Carsten Maik Naumann for guiding me to establish this study as well as my special thanks for Prof. Dr. Klaus-Peter Jünemann, who allowed this work to be delivered to life.

I gratefully thank Prof. Dr. med. Hermann Herbst for the permission to perform this work in his institute with continuous helping, scientific advice and valuable instructions for this thesis. Also my best thank to Dr. med. Amr Al-Najar for his aid and encouragement as well as his ideas, which facilitate the success of this thesis. I would like also to thank Ms. S. Kleimenhagen (Institute of Pathology, Vivantes clinic Neukoelln, Berlin) for performing the histological staining and Dr. M. Ploghöft for introduction to the handling of ACIS, as well as DAKO for providing this system free for this work. My thanks include Mr. Jürgen Hedderich for his statistical advice (Institute of Medical Information and Statistic- University hospital, Schleswig Holstein, Camus Kiel).

## **9. Curriculum Vitae**

### **Personal Data**

Name: Sakhr Mohammed Ahmed Al-Sanabani

Date and place of Birth: 15.04.1975 in Dhamar, Yemen

Family status: married

Nationality: yemeni

Children: three

### **School Study**

1981-1986: Al-Thawra primary school, Sana'a Yemen

1987-1989: Al-Sha'ab middle school Sana'a Yemen

1990-1993: Abdunaser secondary Sana'a Jemen

### **Study of human medicine**

September 1994-Juni 2001: Faculty of Medicine, Sana'a University, Yemen

### **Experience**

Jun. 2001- 2002: Residency in Al-Kwait university hospital Sana'a

Nov.2002–2005: Residency in Unity hospital and demonstrator in faculty of medicine, Thamar University, Yemen

Nov. 2006-2011: Residency in Institute of Pathology in Vivantes-Neukoelln clinic, Berlin

### **Other Qualifications**

2003: Computer fundamentals, windows 98, MS Word, MS Excel, MS power point and MS Access.

### **Memberships**

Member of international academy of pathology, German division

Member of Federal Association of German Pathologists

### **Sakhr Mohammed Ahmed Al-Sanabani**

Berlin, 25.07.2011



