

Establishing valid neuropsychological assessments in patients with gliomas undergoing awake surgery

Dissertation

zur Erlangung des Doktorgrades

der Philosophischen Fakultät

der Christian-Albrechts-Universität

zu Kiel

vorgelegt von Juliane Becker

Kiel

(2016)

Erstgutachterin: Dr. Dipl.-Psych. Gesa Hartwigsen

Zweitgutachterin: PD Dr. Friederike Knerlich-Lukoschus

Tag der mündlichen Prüfung: 31.1.2017

Durch den aktuellen Prodekan: Prof. Dr. Elmar Eggert

zum Druck genehmigt am: 8.2.2017

Acknowledgements

Thank you

To all contributors of this work.

Dedicated to my executive function C.P.

List of Publications

The present dissertation is based on two research articles and one case report:

- Publication I **Becker, J.**, Steinmann, E., Könemann, M., Gabske, S., Mehdorn, H. M., Synowitz, M., Hartwigsen, G., Goebel, S. (2016). Cognitive screening in patients with intracranial tumors: validation of the BCSE. *Journal of neuro-oncology*, 127(3), 559–567. doi:10.1007/s11060-016-2064-6
- Publication II **Becker, J.**, Jehna, M., Steinmann, E., Mehdorn, H. M., Synowitz, M., & Hartwigsen, G. (2016). The sensory-motor profile awake - A new tool for pre-, intra-, and postoperative assessment of sensory-motor function. *Clinical Neurology and Neurosurgery*, 147, 39–45. doi:10.1016/j.clineuro.2016.05.022
- Publication III: **Becker, J.**, Jehna, M., Larsen, N., Synowitz, M., & Hartwigsen, G. (2016). Case report Glioblastoma in hemihydranencephaly: preoperative and postoperative language ability of the right hemisphere. *Acta Neurochirurgica*, 158(7), 1317–1323. doi:10.1007/s00701-016-2825-1

CONTENTS

1 INTRODUCTION	9
1.1 Historical background and definition of clinical neuropsychology	9
1.2 Intracranial tumors	10
1.3 Awake craniotomies and brain mapping	13
1.4 Neuropsychological impairments in intracranial tumors	16
1.5 Neuroplasticity	22
2 METHODOLOGICAL BACKGROUND AND CONSIDERATIONS	25
2.1 Neuropsychological assessment in intracranial tumors	25
2.1.1 Neuropsychological diagnostics	26
2.1.2 Quality criteria for diagnostic tools	28
2.1.2.1 Objectivity	29
2.1.2.2 Reliability	31
2.1.2.3 Validity	32
2.1.2.4 Measures of test performance: Sensitivity and Specificity	33
2.2 Requirements for neuropsychological diagnostics in the neurosurgical emergency hospital	36
2.2.1 The patients	36
2.2.2 The setting	38
2.2.3 Examination purposes and approaches	38
2.2.3.1 Preoperative diagnostics	39
2.2.3.1.1 Cognitive status diagnostic	39
2.2.3.1.2 Patients' eligibility for an awake craniotomy	40
2.2.3.1.2.1 Functional eligibility	42
2.2.3.1.2.2 Psychological eligibility	44
2.2.3.2 Intraoperative diagnostics	46
2.2.3.3 Postoperative diagnostics	49

2.3 Research questions and study aims	50
3 EMPIRICAL STUDIES	52
3.1 Publication I - Cognitive screening in patients with intracranial tumors: Validation of the BCSE	52
3.2 Publication II - The sensory-motor profile awake - A new tool for pre-, intra-, and postoperative assessment of sensory-motor function	62
3.3 Publication III - Glioblastoma in Hemihydranencephaly: pre- and postoperative language ability of the right hemisphere	70
4 GENERAL DISCUSSION AND CONCLUSIONS	78
4.1 Cognitive screening in patients with intracranial tumors: A vote for a comprehensive neuropsychological assessment	78
4.2 Assessment of sensory-motor function in awake craniotomy	81
4.3 Neuroplasticity as a key concept: The ability of the right hemisphere for language functions	86
4.4 An integrative approach of comprehensive neuropsychological assessment in glioma patients undergoing awake surgery	88
4.5 Concluding remarks	92
5 SUMMARY	94
6 DEUTSCHE ZUSAMMENFASSUNG (SUMMARY IN GERMAN)	100
7 REFERENCES	111
8 APPENDIX	122

1 INTRODUCTION

1.1 Historical background and definition of clinical neuropsychology

Clinical neuropsychology represents an important field of expertise within psychology and found its origin in the 18th century, when Franz Josef Gall (1758-1828) aimed to link skull formations with personality traits. During the following decades, technical, medical, political as well as social changes led to a rapid development of this area of expertise. In the 21st century clinical neuropsychology is seen as self-contained subarea of the cognitive neurosciences including university chairs, associations and peer reviewed journals (Goldenberg, 2007). As a scientific discipline clinical neuropsychology aims to understand the central nervous mechanisms underlying human behavior and perception (Hartje & Poeck, 2006). For this purpose, methods and findings from classical psychology, neurology, neuroanatomy and neurophysiology are brought together. As an interdisciplinary intersection between psychology and medicine, the importance of clinical neuropsychology is growing due to increasing age of the general population and an increasing incidence of brain diseases. For prognosis as well as for therapy of a brain disease and its symptoms, valid diagnostic during the course of the disease is highly relevant.

Consequently, a major field of work for neuropsychologists represents **diagnostics** i.e. registration and description of cognitive and affective impairments after brain damage (Sturm, Herrmann, & Münte, 2007). To answer specific diagnostic questions regarding the actual functional state, the course of disease or patient-oriented treatment plans, information from neurological, neuro-radiological and electrophysiological assessments need to be integrated. In addition, standards for objective diagnostics, mainly oriented to those of clinical/psychological diagnostics, need to be set. For correct planning of an assessment and valid interpretation of the results, basic knowledge about psychological test theory as well as functional-anatomic relationships are necessary (Hartje & Poeck, 2006). Neuropsychological assessment focuses on basic and higher perception performance, memory, attention and sensory-motor functions as well as particular educational and job dependent performance. In addition, the patient's affective status and personality are evaluated (Hartje & Poeck, 2006). The second major field of work is neuropsychological **therapy** of brain damage associated functional disturbances. Depending on the severity of brain damage, the duties of a neuropsychologist range from early rehabilitation, with

training of language and orientation, to longer scheduled treatment in several rehabilitative phases with the ultimate goal to reintegrate the patient into his social and professional life (Sturm et al., 2007). The attendance in highly structured inpatient rehabilitation is often followed by ambulant consultations of a neuropsychologist, regularly with a focus on coping with the underlying brain affecting disease and its impact on social and professional life.

The duties of a clinical neuropsychologist in working fields such as ambulant diagnostics, rehabilitation or consultation are well characterized in the literature. However, attention is rarely drawn on the scope of work in a neurosurgical context. To date there is a lack of published recommendations on the characterization of external requirements and specifications of diagnostic questions in this special field of interest. In addition, clinical research on particular topics of this field is rare.

The present work seeks to describe and define the requirements for neuropsychological diagnostic in emergency hospitals treating patients with intracranial tumors. The aim is to validate current methods and to establish a reliable neuropsychological assessment routine for patients undergoing awake surgeries. In addition, a specific diagnostic method for the very special context of intraoperative diagnostics in awake craniotomy is supposed to be introduced and evaluated.

1.2 Intracranial tumors

Intracranial tumors are defined as neoplasm inside of the bony skull (Münste & Herrmann, 2007). They can be roughly discriminated based on the origin of their tissue as primary and secondary brain tumors (Poeck & Hacke, 1998). **Primary brain tumors** can emanate from various sources such as neurons and glial supporting tissue (gliomas), meninges (meningiomas), the pituitary gland, germ cells or from congenital malformations like dysembryoplastic neuroepithelial tumors (Poeck & Hacke, 2006). **Secondary brain tumors** refer to tumors of the skull bone and metastases with an origin in other body parts.

The **incidence** for intracranial tumors is estimated to 15 newly diagnosed adults per 100.000 inhabitants per year (Poeck & Hacke, 2006). The prevalence amounts 50 patients per 100.000 inhabitants. The portion of brain tumors in tumor diseases ranges between 7-9% whereas primary brain tumors represent only 5% (Poeck & Hacke, 2006). With increasing

age, the risk of acquiring a brain tumor raises (Robert Koch-Institut / Gesellschaft der epidemiologischen Krebsregister in Deutschland e.V., 2013). Malignant brain tumors are found more often in men. An extensive description of the medical and biological properties of brain tumors can be found in Berlit (2006) or Hacke and Poeck (2006).

Tumors can be **classified** according to their histological profile into benign and malignant neoplasms (Poeck & Hacke, 2006). For classification of brain tumors the scheme provided by the world health organization (**WHO**), which **differentiates** four grades of malignancies, is widely used (Louis et al., 2007). These grades characterize the biological growth behavior of the tumor considering factors such as cell density or necrosis and provide the estimated time of survival as shown in Table 1 (Berlit, 2006). Here, the **degree of anaplasia** of cells is one important criterion for determination of malignancy of a tumor (Röther, 2006). Anaplasia of cells refers to the regression of mature cells back to undifferentiated cells, which leads to a loss of structural and functional differentiation (for further information see Röther, 2006). This can lead for example to deformed cell nuclei, giant cells and disturbed patterns of orientation of the cells to one another (Weinberg, 2013). As a result, tumors emerging from the same cell type can be classified into tumors of different WHO grades depending on the anaplasia of the cells and the other histological parameters/characteristics (Louis et al., 2007; Weinberg, 2013). An example for a tumor consisting of astrocytes (astrocytoma) and its different nomenclature according to its histological profile and allocation to a WHO grade is provided in Table 1. It is common to divide gliomas into low and high grade gliomas (LGG, respectively HGG) due to their different biological behavior.

Table 1: Histological classification of primary brain tumors according to the WHO-scheme

WHO Grade	Dignity	Estimated survival time	Exemplary tumor entity
I	benign	>5-(50) years	pilocytic astrocytoma
II	semi-benign	3-5 years	diffuse astrocytoma
III	semi-malignant	2-3 years	anaplastic astrocytoma
IV	malignant	6 months (to 2 years)	glioblastoma multiforme

Note. WHO = world health organization

Only 15-20% of all primary gliomas are classified as LGG, which refers to a WHO grade of I or II (van Loon et al., 2015). Their mean incidence in Europe is approximately 1/100.000 persons per year (van Loon et al., 2015). LGGs show a tendency for transformation of their cells from former benign status (grade I or II) to more and more malignant portions (**anaplastic transformation**). For instance, this transformation from an astrocytoma grade II to an anaplastic astrocytoma grade III or even a glioblastoma multiforme (GBM; highest graded astrocytoma) affects about 79% of the patients initially diagnosed with a LGG (Shaw et al., 2002). These so called secondary GBMs are more common in younger patients (Ohgaki & Kleihues, 2009). In cohorts of higher age metastases and malignant gliomas dominate (Röther, 2006). Here for example GBMs without former history of a low grade astrocytoma can be found (Berlit, 2006).

Medical treatment of intracranial tumors consists currently of a neurosurgical operation, radiation and/or chemotherapy. Depending on the tumors' histology and its localization inside the brain, these methods are combined and if necessary repeated. For some cases of benign tumors, like most meningiomas or some cases of pilocytic astrocytoma, one surgery is sufficient to prevent the tumor from growing back again and the patient is considered as cured. The **prognosis** is completely different in semi-benign and malignant gliomas, where despite repeated surgeries, radiation and chemotherapy, a recurrence of the tumor cannot be impeded. For LGGs, due to their slow growth rate and small rate of symptoms in neurological exams, in the past a "wait-and-see" approach was employed until symptoms manifested and a surgery was inevitable (Shields & Choucair, 2014). Today for the treatment of LGGs an early operation is recommended to prevent infiltration and anaplastic transformation, including evidence for a prolonged overall survival (Shields & Choucair, 2014).

Due to these differences between gliomas and other primary and secondary brain tumors regarding biological behavior (f. e. infiltrating vs. non-infiltrating), treatment (operation, chemo- and radiotherapy) and the resulting difference in their impact on the patient's cognitive, psychological and physical wellbeing, this work will mainly focus on gliomas.

For tumors located near or in so called **eloquent areas** (areas specialized for dedicated functions like for instance language or motor function where resection would induce permanent deficits) the surgery can be done under awake conditions to minimize the risk of

permanent impairment. This approach of an **awake craniotomy** is mainly used in glioma patients and described in detail in the following section.

1.3 Awake craniotomies and brain mapping

In the 1930s, Wilder Penfield's approach of **stimulating** the **exposed brain surface** with electric currents during surgeries for epilepsy paved the way for awake craniotomies. By directly evoking responses to focal electrical stimulation of different cortical targets, this approach aimed at identifying eloquent motor areas to preserve respective cortex areas where stimulation elicited observable reactions (Penfield & Boldrey 1937). The resulting map of the human "homunculus" aligned to the brain's surface on the location of the motor and sensory areas is the most popular result of this work (Snyder & Whitaker, 2013). Years later, Ojemann optimized the technique and the rating of the intraoperative tasks (Whitaker & Ojemann, 1977). In 1992, Berger introduced direct cortical stimulation (DCS) to map language and motor functions on the exposed cortex during resections of intracranial tumors (Berger & Ojemann, 1992). Since then, DCS based brain mapping became the standard method for mapping brain functions in neurosurgery worldwide (Mandonnet, 2011). Despite major technical improvements of preoperative functional imaging it is still not possible to predict the resectability (risk of permanent impairment) of a given brain area with high reliability (Ius, Angelini, Thiebaut de Schotten, Mandonnet, & Duffau, 2011). Therefore, DCS based brain mapping remains the gold standard procedure for tumor resection in eloquent areas.

In general, **the formal course of an awake craniotomy** following an awake-awake-awake protocol can be described as follows: The patient is prepared with the routine monitoring devices for medical functions and lightly sedated, but still able to speak, react and move. After analgesia of the patient's scalp works, it is incised and the subjacent skull is opened with a drill and a saw. Finally, the dura mater is incised and stitched to the sides. After that, the neurosurgeon uses a pin shaped electronic probe and applies short electric impulses, which can either disturb, inhibit or elicit neuronal function in a small area (**transient virtual lesion**) (Duffau, 2011a). Simultaneously with the stimulating electric current, which lasts only for seconds, the patient is asked to execute a specific task like picture naming. If task execution is disturbed or not feasible for the patient, the site is considered with **positive**

response to DCS. In consequence, such sites are regarded as functionally **essential** and will not be removed (Duffau, 2011b). To increase the reliability of DCS positive results, the gold standard to date is to stimulate a brain site for three times and to spare it, if *all* stimulations led to disturbances in the monitored function (Duffau, 2011a). Behavioral reactions are often visualized by applying sterile paper numbers and letters on the brain surface, which represent the different patient reactions to DCS. The result is an individual **map of the patients' functions** on his brains surface as shown in Figure 1. After to cortical mapping the resection of the tumor is initiated (Talacchi, Santini, Casartelli et al., 2013). Stimulation on subcortical white matter tracts is used for further resection with the goal to identify the deep functional limits of the resection (Duffau, 2011b). In awake surgery and DCS the **neuropsychological** diagnostic has the responsibility to ensure the mapping of functions located near the tumor and monitor these functions during the tumor resection. Alterations of the assessed functions are recorded and reported to the neurosurgeon. In addition, the neuropsychologist has the responsibility to ensure the patients' compliance and well-being. Details of the intraoperative neuropsychological diagnostic are described in the section "intraoperative diagnostics" below.

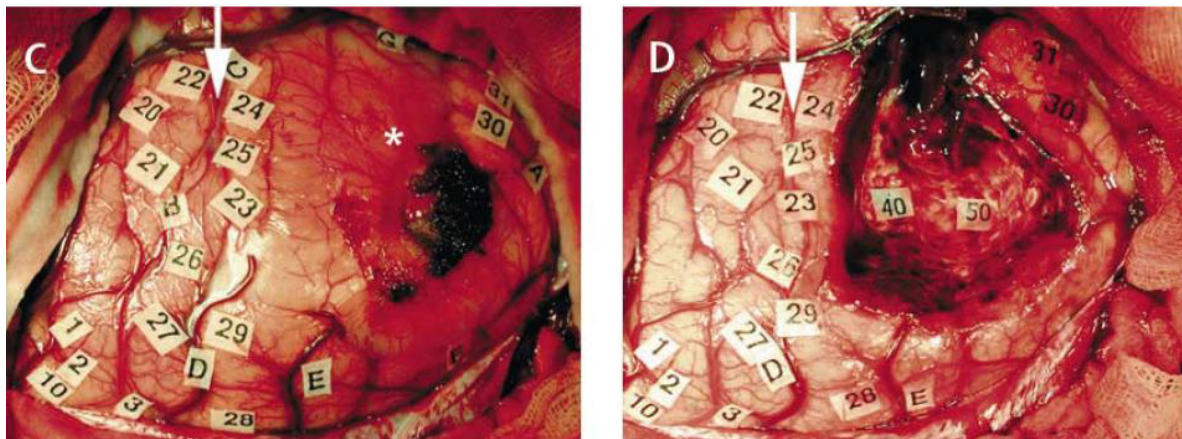


Figure 1: Intraoperative image of a brain's surface. Sterile paper number tags indicate different brain sites stimulated with DCS. The tags correspond to the patient's behavior in reaction to DCS. **Left side (C):** Mapped cortex before any resection, tumor is marked with an asterisk (*). **Right side (D):** Completed resection of the tumor with spared functional areas in the resection cavity indicated by number 40 and 50 (with kind permission taken from Duffau, 2005).

In contrast to the former approach, the patient is deeply sedated until brain mapping can start during an **asleep-awake-asleep** protocol. Mapping is performed during the awake state

and the patient is narcotized before and after this procedure. This approach is not used in all clinics, due to the risk of non-compliance caused by deep sedation and the need for intubation (Talacchi, Santini, Casagrande et al., 2013).

The **objective of an awake craniotomy** is to balance the oncological outcome (improve the survival of the patient) and the functional outcome (preserve quality of life) (Klein, Duffau, & Witt Hamer, 2012; Yordanova, Moritz-Gasser, & Duffau, 2011). For this balancing between maximizing the tumor resection and minimizing permanent neurological deficits Duffau introduced the term „**onco-functional balance**” (Duffau & Mandonnet, 2013).

Maximization of the **survival time** can be achieved by expanding the resection even beyond the visible tumor borders (Duffau, 2011c; Yordanova et al., 2011). This reduces tumor infiltrated brain tissue and therewith a recurrence and the potential for anaplastic transformation (Duffau, 2011c; Yordanova et al., 2011). Studies document the positive correlation between overall survival time and the extent of resection (Berlit, 2006). However, an aggressive resection bears the risk of permanent functional loss, which can ultimately reduce the patient’s quality of life (Giovagnoli, 2005). Minimizing such risks of permanent deficits can be achieved by sparing functional areas during the resection with the help of a functional brain map, as provided by DCS in awake craniotomy (Duffau, 2011c).

Usually, the resection is stopped when no more tumor tissue is apparent by visual inspection and a safety margin of 1 or 2 cm around the former tumor is resected (Berlit, 2006). A more aggressive approach was introduced by Duffau’s group, suggesting that resection should be stopped when reaching functional borders like for example eloquent subcortical pathways (Talacchi, Santini, Casagrande et al., 2013). According to this group, the greater extent of resection increases the overall survival time without decreasing the cognitive and physical wellbeing of the patient (Bello et al., 2011; Duffau, 2009b; Duffau & Mandonnet, 2013). Despite these promising results, there is “not enough data to validate this strategy to date” and future studies on feasibility, reproducibility and safety are mandatory (Talacchi, Santini, Casagrande et al., 2013).

A good intraoperative detection of the functional borders is only possible when patient selection, preparation, intra-operative diagnostic and postoperative outcome evaluation follow a high diagnostic standard. Here, the central role of neuropsychological diagnostics becomes evident. Because cognitive and physical functioning are pivotal for social

participation and quality of life (Ownsworth, Hawkes, Steginga, Walker, & Shum, 2009), it is one of the main goals of neuropsychological diagnostics in the neurosurgery context to support every attempt to preserve these functions.

1.4 Neuropsychological impairments in intracranial tumors

The effects of an intracranial tumor “vary according to such factors as their nature, site, size, rate of growth, and their treatment(s)” (Lezak, 2012, p. 333). The most common consequences of an intracranial tumor are neurological deficits and (neuro-) psychological changes of intellect and personality.

Several factors regarding the basic **neurobiological principles** of brain tumors are responsible for cognitive impairment. All brain tumors share an increase of the **intracranial pressure** due to their mass effect inside the skull. In case of slow growing tumors, the brain is able to tolerate their growth in some parts by shrinkage of the ventricles and compression of the brain tissue. This process can continue over years before any signs of an increased intracranial pressure or neuronal malfunction become evident (Poeck & Hacke, 2006). Due to constant pressure on the brain tissue, cerebral perfusion decreases and relative oxygen shortage occurs. In addition, newly built vessels lack a blood-brain-barrier in some tumors. As a consequence, the surrounding brain tissue may store liquid and thus swells. This mechanism is known as tumor induced **edema** of the brain. On the long run, shortage of oxygen, as well as edema, disturb routine neuronal communication leading to impairments. Overall, cognitive decline increases with edema and tumor size and a higher WHO grade (Talachchi, Santini, Savazzi, & Gerosa, 2011; Taphoorn & Klein, 2004). In addition, depending on the kind of tumor, the borders between tumor and healthy brain tissue are to a greater or lesser extent differentiated. In particular low grade gliomas (LGG; primary brain tumors with low WHO grade) tend to grow along cerebral fibers and **infiltrate** large areas of brain tissue without causing a clear mass effect for a longer period (Duffau, 2011b). The extent of infiltration of healthy brain tissue and resulting degeneration of neuronal communication also contributes to cognitive impairment (Bosma et al., 2007; Taphoorn & Klein, 2004). In addition, every third brain tumor patient experiences **epileptic seizures**, often as an initial symptom (Poeck & Hacke, 2006). About 65%-85% of patients with LGG do experience seizures as general symptom of the disease (Shields & Choucair, 2014). Epileptic seizures

hamper cognitive functioning and require medication (Bosma et al., 2007; Correa et al., 2007; Klein et al., 2001; Klein et al., 2012). However, anti-epileptic medication may have a negative influence on attention and executive functions (Klein et al., 2002; Klein et al., 2003). Furthermore, **radio- and chemotherapy** can also lead to a reduced cognitive and physical performance status (Correa et al., 2007; Correa et al., 2008; Klein et al., 2002). In summary, factors of tumor characteristics, treatment modalities and comorbidities can account for the observed variations of cognitive functioning in patients with gliomas over time (van Loon et al., 2015).

Tumor related neurological impairments are movement disorders and hemiparesis, as well as sensory deficits and visual disturbances (Poeck & Hacke, 2006). Symptoms caused by increased intracranial pressure include headache, deceleration, a general lack of interest as well as changes in affect and motivation (Poeck & Hacke, 2006). In addition, **cognitive symptoms** such as disturbances of language, memory, attention, orientation or planning are frequently found in patients with intracranial tumors (Klein et al., 2002; Meyers, Hess, Yung, & Levin, 2000; Murray et al., 2000; Santini, Talacchi, Squintani et al., 2012; Satoer et al., 2012; Scheibel, Meyers, & Levin, 1996; Scotland, Whittle, & Deary, 2012; Talacchi et al., 2011; Taphoorn & Klein, 2004; Tucha, Smely, Preier, & Lange, 2000). The prevalence of cognitive decline before treatment (surgery, radio- or chemotherapy) in patients with intracranial tumors is shown in Table 2. Only studies applying a neuropsychological test battery, a clear definition of patient sample and assessment date were included. Although glioma induced impairments can affect all cognitive domains, a substantial portion of patients show no signs of cognitive deficits at all (Habets et al., 2014; Klein et al., 2002; Meyers et al., 2000; Murray et al., 2000; Santini, Talacchi, Squintani et al., 2012; Satoer et al., 2012; Scheibel et al., 1996; Scotland et al., 2012; Talacchi et al., 2011; Taphoorn & Klein, 2004; Tucha et al., 2000).

Table 2: Cognitive impairment in patients with brain tumors *before* treatment in comparison with healthy subjects

study	cognitive domains		neuropsychological tests	
	impaired	most often impaired	impaired	most often impaired
Santini, Talacchi, Squintani et al., 2012: n = 22, gliomas in the left hemisphere, scheduled for awake craniotomy, “preoperative”	37% of the patients showed deficits in one or more domains	visual-spatial memory	59% of the patients showed deficits in one or more tests	visual-spatial memory, verbal memory, word fluency
Talacchi et al., 2011: n = 29, gliomas, 1-5 days prior to the operation	38% of the patients showed deficits in one or more domains executive functions, memory, language, gnosis, kinetic praxia	executive functions	79% of the patients had deficits in at least one of the tests	verbal memory, visual-spatial memory, word fluency
Tucha et al., 2000: n = 139, primary or secondary intracranial tumors, before operation (not further specified)	/	/	91% of the patient had deficits in one or more tests	memory, attention, executive functions
Habets et al., 2014: n= 62, high grade gliomas, week before operation	79% impairment in at least one domain	verbal memory, attention	/	/
Satoer et al., 2012: n = 28, gliomas in left hemisphere, 1-2 months before the operation	language, memory, executive functions	/	/	/
Satoer et al., 2014: n = 45, gliomas in eloquent areas 93.3% left hemisphere, 1-2 months before operation	language, memory, attention, executive functions	/	/	/

Note. / = no data available

In patients with LGGs, the prevalence of cognitive impairments regarding memory, attention and executive functioning range from 19% to 83% (van Loon et al., 2015). Comparing high and low grade gliomas, a recent finding by Campanella and colleagues (2015) supports the assumption that patients with HGG show lower preoperative cognitive functioning over LGG patients. The ability of the brain to compensate for tumor induced neuronal malfunctions and to reorganize after lesions is referred to as **neuroplasticity** (Duffau, 2011b) and discussed in detail in section 1.5 Neuroplasticity. In this section, the relationship of tumor grade and impairment is also further specified.

The dimension of **surgery induced cognitive impairments** cannot be validly estimated since the existing literature on the comparison of pre- and direct postoperative cognitive functionality is scarce (Klein et al., 2012). Evidence for surgery induced impairments was demonstrated in a small cohort study by Reijneveld and colleagues (2001), who evaluated which treatment option (wait-and-see vs. surgery) is preferable for patients with LGGs regarding cognitive functionality. The cognitive performance of 24 patients with suspected LGG (wait-and-see group) was assessed via a neuropsychological test battery and compared to the performance of i) patients with operation or ii) biopsy approved LGGs and iii) a control group. All groups were matched. Both patient groups showed worse cognitive performance relative to the control group. The operated LGG-patients demonstrated more severe cognitive decline than the LGG-patients without operation or biopsy. Talacchi and colleagues (2011) reported impairments in 76% of the patients after successful surgery on the single test level, and in 38% on the domain level. An improvement of cognitive functions only occurred in approximately 20% of the patients whereas a worsening was found in 38% (single test level). In contrast, Campanella and colleagues (2015) found a significant increase in cognitive deficiency rates only for LGG patients directly after the operation but no change in HGG patients. Table 3 summarizes all studies comparing cognitive functioning in patients with intracranial tumors before and after the operation using extensive neuropsychological test batteries. It remains an open question why cognitive functioning improves directly after surgery in some cases but declines in others.

In general, the patients' individual **physiological response to an intracranial operation** has to be taken into account (Talacchi et al., 2011). Some patients develop postoperative **edema** and **infarction** around the resection cavity, which can account for cognitive and sensory-

motor decline (Poeck & Hacke, 2006). On the other hand, reduction of the tumors' **mass effect** can improve the formerly existent impairments spontaneously (Tucha et al., 2003). In addition, the brain's ability to adapt to lesions before the operation (**neuroplasticity**) can differ between patients. For example, patients with higher preoperative adaption to the tumor (as often seen in LGG patients) tend to have fewer direct postoperative deficits despite removal of eloquent areas (Desmurget, Bonnetblanc, & Duffau, 2007).

Depending on the tumor type (LGG or HGG), the **changes in cognitive functionality across time** can differ significantly. As shown in Table 3, only few studies are available comparing cognitive functioning in the long-term follow-up with a comprehensive neuropsychological test battery. For instance, Santini and colleagues (2012) reported a rate of 45% of patients with a decline in cognitive functioning, whereas improvement is reported in 5% of the patients. Predominantly executive and language functions were affected. In approximately one third of the patients, no changes in the assessed cognitive functions were found. While 60% of LGG patients were able to return to work, this was only the case in 10-20% of HGG patients (Armstrong et al., 2016).

Table 3: Cognitive impairment in patients with brain tumors *after surgery* in comparison with preoperative results

study	cognitive domains		single neuropsychological tests	
	↓	↑	↓	↑
Talacchi et al., 2011: n = 29, gliomas, 3-7 days postoperatively	21%	24% memory	38% visuo-motor pace with alternation	24% memory
Habets et al., 2014: n= 36, high grade gliomas, 5 weeks after operation before any treatment	17% verbal memory, 15% attention, 15% psychomotor function (total 23%)	24% visuo- construction, 21 % verbal memory, 18% attention (total 49%)	/	/
Satoer et al., 2014: n = 45, gliomas in eloquent areas 93.3% left hemisphere, 1-2 months before operation and 3 months postoperatively	language	memory	categorical fluency	free verbal recall
Satoer et al., 2012: n = 28, gliomas in left hemisphere, 3-4 months after the operation	language, executive functions	/	39% word fluency, visuo-motor pace with alternation	21% free verbal recall
Santini, Talacchi, Squintani et al., 2012: n = 22, patients with glioma in the left hemisphere, scheduled for awake craniotomy, follow-up data obtained 3-6 months postoperatively (if possible)	45% executive functions, memory	5%	54% word fluency, attention, working memory, verbal memory, picture naming	18%

Note. ↓ = decreased functionality; ↑ = increased functionality; / = no data available

When evaluating the number of impaired patients, the following considerations have to be taken into account. First, there is no consensus on how to assess cognitive impairment in patients with intracranial tumors (van Loon et al., 2015). Following this, the information about the number of impaired patients depends, beside tumor characteristics, on the time

point of assessment (before/after the operation and course of the disease), different patient samples (first diagnosis, recurrence), different neuropsychological assessment methods (selection of tests, evaluation focus like test-specific or domain-specific analysis) and different criteria for impairment. In addition, reports of missing data or participation bias of subjects are often missing in the literature so far. Moreover, the different rates on postoperative cognitive improvement or decline can be explained by several factors, along with different methods for assessment and criteria of impairment classification. First, the postoperative **assessment time points** differ between studies and some included also patients with passed radio- and/or chemotherapy (for example Satoer et al., 2012). Second, the **tumor type** is crucial for the course of cognitive functioning. In case of tumors with no recurrence, like most meningiomas, postoperative cognitive impairment remains stable or can be increased by neuropsychological rehabilitation and therapy (Meskal, Gehring, Rutten, & Sitskoorn, 2016). In case of slow growing lesions like LGGs, time also allows rehabilitation of cognitive deficits but tumor growth will subsequently lead to deficits again. In case of malignant (primary) brain tumors only a short time period for recovery exist. Their fast progressive tumor growth makes additional treatment such as chemo- or radiotherapy necessary, which are known to negatively influence cognitive performance. Moreover, their recurrence leads to inevitable cognitive decline (Bosma et al., 2007; Correa et al., 2007; Correa et al., 2008; Klein et al., 2002). Third, the type of **surgical approach** (tumor extirpation under intubation narcosis or awake craniotomy) might have a significant influence, especially on functions like language and sensory-motor processing, because cognitive and physical functions can be protected under awake craniotomy (see chapter 1.3 Awake craniotomies and brain mapping).

1.5 Neuroplasticity

The **concept of neuroplasticity** describes the brain's ability to rearrange cerebral organization following injuries to restore functioning of neuronal networks (Desmurget et al., 2007). Neuroplasticity can also take place in healthy individuals due to learning of new abilities (Thomas & Baker, 2013). The underlying biological mechanisms at a microscopic and macroscopic scale, such as modulation of synaptic efficiency, neurogenesis or functional redundancies, are currently investigated in many studies (Duffau, 2011c). It is known that

some of these mechanisms allow changes of neuronal functioning within minutes to hours (**short-term remodeling**) while other types require several days to months before reaching a new functional state (**medium- or long-term remodeling**) (Duffau, 2011c). Based on fMRI studies, a **hierarchical model of reorganization** with three steps of functional redistribution in patients with intracranial tumors was suggested: In a first step remaining functional areas within the tumor are determined, in a second step, neuroplastic mechanisms redistribute eloquent areas around the tumor tissue and finally, if compensation is still insufficient, functional compensation by “remote areas within the lesioned hemisphere and/or contralateral homologs” is established (Desmurget et al., 2007).

Following the time course of a brain tumor disease, three intervals for possible compensation can be defined: i) preoperative functional compensation, ii) intraoperative functional reshaping and iii) postoperative functional compensation. For the **preoperative phase of compensation** the **temporal pattern** of the lesion (acute vs. slow-growing) was identified as a central factor for neuroplasticity (Desmurget et al., 2007). Functional compensation is higher in slow growing lesions such as LGGs over acute lesions caused by stroke. LGGs grow approximately 4 mm per year and within 8 years, most patients do not show any neurological or neuropsychological impairments due to neuronal adaption (Desmurget et al., 2007). Acute and slow growing lesion types seem to differ with respect to their pattern of reorganization: the recruitment of remote brain areas in the ipsi- and contra-lesional hemisphere is much more efficient in slow growing than in acute lesions (Desmurget et al., 2007). In addition to the previously described fMRI studies, **intraoperative** DCS studies confirmed the hierarchical model of reorganization and its postulated three steps of organization of eloquent areas especially for sensory-motor and language sites (Duffau, 2011c). Furthermore, the assumption of short-term remodeling and immediate **intra-surgical plasticity** triggered by the resection itself could be observed by DCS assessment for the first time (Desmurget et al., 2007). With the help of DCS, brain regions which cover similar functions can be identified (redundant sites). Subsequently, the site which is infiltrated by the glioma can be resected and the functional transfer to the second, intact site can be observed (Duffau, 2011c). **Postoperatively**, neuroplastic adaptations can be supported by specific rehabilitation (Duffau, 2011c; Zucchella, Capone et al., 2013).

The integration of the existing knowledge about neuroplasticity led to two main **therapeutic implications**. First, based on the results of a study by Ius and colleagues (2011), a **map of resectability** was generated for WHO grade II gliomas which indicates the probability of eloquent areas within tumor affected structures with the goal to preoperatively estimate the expected extent of the resection. A high probability of functional areas within the tumor mass was found in the primary motor and somatosensory cortex and emphasizes the importance of dedicated intraoperative diagnostic for sensory-motor functions (Ius et al., 2011). In a complementary approach, Duffau (2011c) proposed a list of cortical areas where surgical removal should induce only transient deficits and would allow full postoperative recovery. These areas included, among others, the supplementary motor area (SMA), the insula or primary somatosensory areas (Duffau, 2011c). Second, knowledge regarding the time course of neuroplasticity enables a **staged neurosurgical** approach (Talacchi, Santini, Casagrande et al., 2013; Talacchi, Santini, Casartelli et al., 2013). Factors like the resection itself, postsurgical rehabilitation and/or regrowth of the residual tumor could result in additional functional reshaping (Duffau, 2011c). If eloquent areas are found within the tumor, allowing only an incomplete glioma resection, modern neuro-oncology recommends a waiting period for further neuroplastic changes and a second surgery several months or years after the first. Animal studies confirmed a better outcome for such a staged neurosurgical approach relative to a single complete resection (Duffau, 2011c; Martino, Taillandier, Moritz-Gasser, Gatignol, & Duffau, 2009; Robles, Gatignol, Lehericy, & Duffau, 2008).

Because neuroplasticity is difficult to investigate, only sparse information about **predictors and limitations of the plastic potential** is accessible to date. One limiting factor seems to be the subcortical connectivity via white matter fibers. A minimum of connecting **white matter** tracts needs to be preserved to enable postoperative recovery (Ius et al., 2011). So far, there is only evidence for patterns of subcortical plasticity involving the altered use of preserved white matter tracts, but no evidence for building new tracts (“rewiring”) in humans (Duffau, 2009a). Neurosurgery could potentially harm necessary white matter connections and thereby lead to permanent neurological impairments. This again emphasizes the importance of awake craniotomies and suitable intraoperative diagnostic of functional areas as described in chapter 2.2.3.2 Intraoperative diagnostics.

2 METHODOLOGICAL BACKGROUND AND CONSIDERATIONS

2.1 Neuropsychological assessment in intracranial tumors

Neuropsychological approaches in intracranial tumors primarily focus on diagnostics with the goal to help optimizing medical treatment stages for the individual needs of patients (“**personalized therapeutic management**”) (Duffau, 2014). At the beginning of the inpatient stay and before the operation, the main concern regards the patient’s current cognitive status. Prior to treatment, the **goal** of the neuropsychological assessment is to establish a **cognitive profile** providing a first evaluation of the status of the most important cognitive and sensory-motor functions. In contrast to standard neurologic examinations, deficits are often diagnosed by in-depth neuropsychological assessment (Duffau, 2014). This profile provides the physicians with an overview of the patient’s ability to understand questions and instructions and cooperate. In addition, cognitive deficits can be seen as indicators of the functional-neuroanatomical relationship between the tumor and the surrounding brain tissue. Many patients benefit from neuropsychological education and explanation of their symptoms. This way, the compliance for the following treatments can be increased (Díaz et al., 2009). For clinical as well as research purposes, the initial baseline assessment is crucial for all conclusions drawn from the following assessment time points. Comprehensive intraoperative neuropsychological diagnostic supports the neurosurgeon’s decisions regarding the resection and therewith helps to maintain the patient’s cognitive and physical status as well as quality of life. Follow-up diagnostic enables planning of rehabilitation and assessment of rehabilitation achievements. In addition, reliable and valid diagnostic is necessary for outcome evaluation. This influences the impact of surgical techniques such as awake craniotomy compared to intubation narcosis and also the need for the evaluation of side effects of radio- or chemotherapy.

In the following sections, basic principles of neuropsychological assessment, methodological quality criteria and diagnostic requirements resulting from patient care in the context of neurosurgery are discussed.

2.1.1 Neuropsychological diagnostics

To describe complex cognitive performance, it is necessary to establish **theoretical assumptions** of the underlying cognitive constructs which are often not directly observable (Lezak, 2012). Well-established cognitive **constructs** are evidence based, and for example recommended by the guidelines for neuropsychological diagnostic of the German society of neuropsychology (Leitlinien zur neuropsychologischen Diagnostik der Gesellschaft für Neuropsychologie (GNP; Gauggel & Sturm, 2005) and can be found in the existing standard text books of clinical neuropsychology (Hartje & Poeck, 2006; Lezak, 2012; Sturm et al., 2007). Basic functions such as concentration, orientation to time and working memory as well as higher cognitive functions such as reasoning or planning are defined. Single functions for similar constructs can be grouped into **cognitive domains**. For instance the domain language is composed of reading, picture naming and understanding written and acoustic information (Satoer et al., 2012). Other common domains are attention, memory and executive functions (Lezak, 2012; Schnider, 2008; Taphoorn & Klein, 2004). There is no strict assignment of discrete cognitive functions to cognitive domains. This can be explained by the fact that particular functions often contribute to more than one domain (Lezak, 2012). In addition, "It is typically unclear, and in most cases impossible to demarcate a distinctive boundary where one function stops and the other begins." (Lezak, 2012, p. 25). Similar problems emerge when assigning neuropsychological tests to discrete functions since test performance often engages several cognitive functions. Consequently, assignment of **tests** is commonly carried out according to major functional areas of response. However, such assignment differs in complexity among different tests which strongly call upon several functions (Lezak, 2012). The Trail making test part B is an example for a complex assignment of a test (Tombaugh, 2004). The TMT-B aims to assess visuo-motor speed and divided attention, but captures also visual scanning, attention and cognitive speed (Tombaugh, 2004). Due to this, the TMT-B can be applied as a tool for assessment of different domains such as attention or visuo-motor functions. In summary, the absence of any consensus on the distinction of cognitive domains or assigned functions for neuropsychological diagnostics might hamper valid estimation of the prevalence of cognitive deficits in patients with brain lesions.

Compilations of neuropsychological tests, so called **test batteries**, aim to investigate, with at least one neuropsychological test, the most important domains of cognition such as

language, visuo-motor speed, visuo-perception, attention and memory (Satoer et al., 2014; Taphoorn & Klein, 2004). An average assessment time for a comprehensive neuropsychological test battery in patients with intracranial tumors is one hour or more (Bosma et al., 2007). The final result of this assessment is a **neuropsychological performance profile**, characterizing the patient's strengths and deficits (Taphoorn & Klein, 2004). Diagnostic **test instruments** of a battery are taken from other settings such as intelligence diagnostics (f. e. digit span from Wechsler batteries) as well as pools of tests explicitly dedicated to neuropsychological testing (f. e. the Five Point Test) (Lezak, 2012). For practical reasons, a selection of short single tests is usually preferred over one extended test. This allows for taking breaks without compromising test results. Suggestions of a gold standard for diagnostics in the setting of a neurosurgical emergency hospital can be found in the existing literature (Reijneveld et al., 2001; Taphoorn & Klein, 2004), some of which refer to tests being successfully applied in patients with intracranial tumors (Satoer et al., 2014). However, a major drawback is the lack of **validation** of many cognitive tests for the use in patients with brain tumors. Furthermore, a standardized implementation of diagnostic tests would be mandatory to guarantee sufficient validity. Chapter 2.1.2 of this thesis focuses on the description of evaluation criteria for the quality of diagnostic test instruments.

In some instances, particularly in research settings with low resources or patients with strong impairments, short **cognitive screening tools** might be more appropriate than comprehensive test batteries. With an average assessment period of approximately 10 minutes, they are very efficient. However, one drawback is the lack of a differentiated cognitive performance profile as cognitive screening tools often assess cognitive functions or constructs via a single item to generate a sum score for global cognitive functioning. This might significantly affect both the sensitivity and specificity of the assessment. Specifically, the use of screening tools always bears the risk of false negatives (i.e., erroneously classifying patients as unimpaired), which can be avoided by using a comprehensive test battery. Another percentage of patients is misclassified as impaired by screening tools but does not show cognitive impairment in a comprehensive test battery (i.e., false positives). Consequently, the aim of the first publication included in this thesis (Becker, Steinmann et al., 2016) focuses on the validity of different screening methods and their potential for clinical and research application.

The two most common cognitive screening tools in the field of intracranial tumor patients are the Mini Mental Status Exam (**MMSE**) (Folstein, Folstein, & McHugh, 1975; Kessler, Denzler, & Markowitsch, 1990) and the Montreal cognitive assessment (**MoCA**) (Nasreddine et al., 2005). The MMSE was designed to screen for patients with a high probability of Alzheimer's disease (AD). The MoCA represents a later, more sensitive advancement which aims at identifying patients with mild cognitive impairment as a first stage of AD, which might be missed by the MMSE. Consequently, the MMSE consists of easier items and is more prone to ceiling effects in the sum score in patient groups other than AD (Tombaugh & McIntyre, 1992). The **MMSE** includes tasks for orientation, attention/concentration, language functions, construction, verbal learning and recall (Malloy et al., 1997). It is not suitable for the assessment of cognitive deficits such as executive functions, abstract thinking, judgment, problem solving and visual perception (Malloy et al., 1997; Meyers & Brown, 2006; Meyers & Wefel, 2003; Nasreddine et al., 2005; Shibamoto et al., 2008; Smith, Gildeh, & Holmes, 2007). Thus, additional testing is recommended to cover executive functioning (Folstein, 1998). The **MoCA** evaluates visuospatial/executive functions, naming, verbal memory (immediate and delayed recall), verbal fluency, attention, abstraction, and orientation. It was previously validated in patients with intracranial tumors (Olson, Tyldesley et al., 2011). Although it was initially designed for patients with an early state of dementia, current studies show a clear advantage over the MMSE also in neuro-oncological patients (Bernstein, Lacritz, Barlow, Weiner, & DeFina, 2011; Olson et al.; Olson, Tyldesley et al., 2011; Olson, Chhanabhai, & McKenzie, 2008). To overcome the limitations of established tools in the field of (neuro-) psychology with respect to sensitivity and specificity, new tools are validated against established tools. A recently published screening tool is the Brief Cognitive Status Exam (**BCSE**), as part of the Wechsler Memory Scale – Fourth Edition (Petermann & Lepach, 2012). The first publication included in this thesis represents the first validation of the BCSE in patients with intracranial tumors and provides a differentiated analysis of its use for this patient group (see chapter 3.1).

2.1.2 Quality criteria for diagnostic tools

The test quality is usually defined by standard criteria, including test objectivity, reliability and validity (Moosbrugger & Kelava, 2012b). In addition, a psychological test instrument can

be evaluated in terms of its performance as a classifier for a certain function such as cognitive impairment (i. e. impaired vs. non-impaired). In psychological and medical contexts, metrics like sensitivity and specificity are preferred to assess the validity of a diagnostic instrument. The main criteria and selected methods for their quantification are described in more detail in the following section.

2.1.2.1 Objectivity

A test is considered as objective, if data is collected in an unbiased fashion and therefore independent of test *instructor, scorer and interpreter* (Moosbrugger & Kelava, 2012a). According to the different steps of a test procedure (administer test, score tested subject's performance, interpret results), objectivity can be differentiated into three sub aspects termed *implementation, evaluation and interpretation objectivity* (Amelang, Zielinski, Fydrich, & Moosbrugger, 2002). During each step of a test procedure the examiner might have an influence on the final test result/score of a tested subject (Amelang et al., 2002). To ensure independence of the final test result from the examiner, most test manuals provide specific and detailed instructions on how to administer, score and interpret the test (Strauss, Sherman, Slick, & Spreen, 2006). According to classical test theory, the final test result ("x") of a tested subject is thought to be the sum of a true score ("t") and an error ("e") expressed in the formula " $x = t + e$ " (Strauss et al., 2006). The Measurement error "e" can be defined as "fluctuation in scores that results from factors related to the measurement process that are irrelevant to what is being measured" (Urbina, 2004, p. 117). From this view, standardization of each step of a test procedure aims to minimize variance of the error in the final test result due to different examiners, scorers and test situations (Beauducel & Leue, 2014; Strauss et al., 2006).

In more detail, **implementation objectivity** refers to the grade of independence of the test results from systematic or unsystematic variations of behavior of the examiner during test implementation. Behavior of the examiner can lead to variations in the performance of a tested subject and in consequence to variations of the final test result (Lienert & Raatz, 1998). Implementation objectivity can be achieved by providing clear instructions on the conditions under which the test should be performed, such as (written) instruction for the tested subject, help f. e. by cuing or rules for termination in the handbook (Moosbrugger

& Kelava, 2012b). As a result of this standardization, the implementation conditions should not vary between assessments (Lienert & Raatz, 1998) and the tested person is assumed to be the only source of variance in the assessment situation (Moosbrugger & Kelava, 2012b).

Evaluation objectivity refers to the numerical or categorical evaluation of the recorded test performance of a tested subject according to dedicated rules (Lienert & Raatz, 1998). This can be achieved by providing the investigator with a standardized protocol and scoring sheet for each subject and consistent rules for scoring of test performance in the test manual (Lienert & Raatz, 1998). The final result of the scoring/evaluation procedure is the raw score of the tested subject (Lienert & Raatz, 1998). Evaluation objectivity is perfect in case of items with a clear “correct” or “wrong” answer (f. e. Wechsler Digit Symbol Test) (Lienert & Raatz, 1998; Sherman, Brooks, Iverson, Slick, & Strauss, 2011). Lower evaluation objectivity is obtained for tests with a subjective component during scoring (f. e. Rey-Osterrieth Complex Figure, Aachener Aphasia Test or verbal fluency tasks) (Sherman et al., 2011). Most handbooks provide examples with clearly assigned scoring, however, regularly there is test performance which is not covered by such examples and in consequence, scoring is not possible without ambivalence (Lienert & Raatz, 1998).

Interpretation objectivity refers to the grade of independence of the interpretation of raw scores of a test from the interpreting person, which must not be necessarily the examiner or scorer of the test (Lienert & Raatz, 1998). Most handbooks provide clear rules for interpretation of raw scores to achieve interpretation objectivity (Moosbrugger & Kelava, 2012a). Absolute interpretation objectivity is given where norm charts or criteria for definition of aberrations are available (f. e. raw scores are assigned to percentile ranks or classified by a cutoff score) (Lienert & Raatz, 1998; Moosbrugger & Kelava, 2012a). In this case, identical raw scores of different test subjects will result in the same interpretation result. Lower interpretation objectivity is found in “clinical approaches” where test material needs interpretation of the examiner (f. e. projective tests) (Amelang et al., 2002).

Objectivity, reliability and validity are strongly related factors, where objectivity is a basic requirement for the others (Beauducel & Leue, 2014). Quantification of implementation, evaluation and interpretation objectivity is possible by assessing the degree of concordance between two or more investigators and is referred to as **interrater reliability** (Margraf, Maier, & Pschyrembel, 2012). Due to the substantial overlap of the concepts of objectivity

and reliability (see also Amelang et al., 2002) some authors outline statistical quantification of objectivity in the section/chapter on objectivity and do not introduce the term interrater reliability (f. e. Amelang et al., 2002; Lienert & Raatz, 1998; Moosbrugger & Kelava, 2012a). Contrariwise, other authors introduce interrater reliability in the section on reliability and do not address the topic objectivity in detail (Sherman et al., 2011; Strauss et al., 2006).

For this work, we followed a suggestion of Amelang and colleagues (2002) classifying the above outlined aspects of implementation, evaluation and interpretation objectivity qualitatively as “present” or “absent” after review of a tests handbook. Statistical quantification of objectivity in the form of interrater reliability will be assigned to the section “reliability” according to Sherman and colleagues (2011) (see also Margraf et al., 2012; Strauss et al., 2006).

2.1.2.2 Reliability

Reliability refers to “the overall consistency of a measure and can be defined in several ways, including consistency within itself (internal consistency reliability), consistency over time (test-retest reliability), consistency across alternate forms (alternate form reliability), and consistency across raters (interrater reliability)” (Strauss et al., 2006, p. 10). The aforementioned aspects of reliability “contribute to an overall assessment of a particular test’s reliability, which is simply an estimate of the degree to which a test is free from measurement error” (Sherman et al., 2011, p.874). The term measurement error refers to “e” introduced in section 2.1.2.1. Objectivity. “Reliability coefficients are influenced by test characteristics (e. g., length, item type, item homogeneity), sample characteristics (e.g., sample size, range or variability)” and a tests “clarity” (Strauss et al., 2006, p.10), which refers to aspects of objectivity in implementation and evaluation as outlined above.

Most important for the present work are the **test-retest reliability** (comparison of test scores of the same subject during two assessment times) and the **interrater reliability** (assessing the degree of agreement between two or more raters). A statistical method for quantification of test-retest reliability is the correlational analysis of test raw scores between the two time points of assessment (Sherman et al., 2011). The resulting correlation is referred to as retest reliability coefficient (Sherman et al., 2011). Statistical methods for quantification of interrater reliability include for instance correlational analysis (Amelang et

al., 2002; Lienert & Raatz, 1998; Sherman et al., 2011), Kendall's coefficient of concordance (Moosbrugger & Kelava, 2012a), percent of agreement and kappa (Sherman et al., 2011).

2.1.2.3 Validity

Validity can be defined as the degree of accordance between the attribute measured by the test and the attribute it claims to test for (Lezak, 2012; Sherman et al., 2011). Factors that can affect validity in an individual assessment are for instance “deviations from standard administration, unusual testing environments, and variable or poor examinee cooperation” (Sherman et al., 2011, p. 886). There are several aspects of validity by which test scores can be classified (Urbina, 2004). The most common model of validity is the “tripartite model” whereby validity is divided into three core components (content-related, criterion-related and construct validity) (Sherman et al., 2011). Two components of validity are of particular interest for this work. The **construct validity** can be estimated by addressing convergent and divergent validity (Moosbrugger & Kelava, 2012b). Convergent validity indicates the degree of accordance between the test and the results from other tests for similar constructs. Contrariwise, divergent validity aims to investigate whether a test measures one specific, distinguishable trait. Therefore, for instance low correlations are expected with tests that measure other constructs.

Criterion validity is given, if successful conclusions on a criterion outside the test situation can be drawn from the behavior of the subject during the test situation (Sherman et al., 2011). This can be operationalized by **concurrent validity** (the relationship between test result and a criterion at the same time point) and **predictive validity** (prognosis of a future value of the construct) (Lezak, 2012; Moosbrugger & Kelava, 2012a). Quantification of both is generally carried out by correlational analysis (Moosbrugger & Kelava, 2012a). In addition, classification accuracy statistics such as positive and negative predictive values (predicting the presence or absence of specific diagnoses based on test scores) are also used to determine the validity of test scores (Sherman et al., 2011). These are described in detail in section 2.1.2.4 Measures of test performance.

Ecological validity is of particular importance for neuropsychological diagnostics. It refers to the ability of a neuropsychological test to predict behavior in everyday life such as returning to work, benefit from rehabilitation, independent living, or managing finances (Lezak, 2012).

Ecological validity is especially important for essential functions determining quality of life such as communication abilities or mobility. Achievement of high ecological validity is often limited by the test procedure itself because test situation and requirements do not completely match daily demands (Chaytor & Schmitter-Edgecombe, 2003). For instance, a quiet environment for the test might allow good performance, but a high noise level at work or home environment might still prevent sufficient participation in everyday situations (Lezak, 2012).

Factors limiting validity

Validity of test results will vary upon the field of application of a test (spectrum of usage and population) (Lezak, 2012; Sherman et al., 2011). An example for this is the use of a screening instrument explicitly designed to discriminate patients with Alzheimer's disease from elderly depressed persons. The predictive validity may be lower when it's used for the purpose of identifying young traumatic brain injury patients who are likely to benefit from rehabilitation (Lezak, 2012). Similarly critical can be seen the use of the MMSE in clinical study trials: the test was explicitly designed for diagnosis of Alzheimer's disease but is frequently used for determination of side effects in clinical trials (for further discussion see publication one of this thesis).

As outlined above (see section "Neuropsychological diagnostics"), one test can address several cognitive constructs. In consequence, a test can vary with respect to validity for the measurement of different constructs (Lezak, 2012). Validity measures/ results will be lower when assessing psychological constructs that highly fluctuate, such as executive functioning (Strauss et al., 2006). Lower validity results are also expected for populations that show a high response variability, such as patients with brain disorders (Strauss et al., 2006).

2.1.2.4 Measures of test performance: Sensitivity and Specificity

Many neuropsychological tests, particularly screening instruments, provide the investigator with a binary classification of the tested person for a distinct attribute (condition of interest (Strauss et al., 2006). Regarding cognitive function, this refers to the classification of being cognitively impaired or unimpaired. To attest the quality of a new instrument, well

established tests for similar purposes can be used as external classifiers (so called gold standard) (Strauss et al., 2006).

Sensitivity and specificity are statistical measures for the performance of a binary classification test (Moosbrugger & Kelava, 2012a). **Sensitivity** refers to the proportion of subjects with the condition of interest determined by the gold standard who are correctly classified as such by a test (true positive rate, see Table 4) (Strauss et al., 2006). **Specificity** refers to the proportion of subjects without the condition of interest determined by the gold standard who are correctly identified as condition negative by the new test (true negative rate) (Strauss et al., 2006).

Sensitivity and specificity have a negative relationship making independent optimization of both at the same time impossible (Lezak, 2012). A highly sensitive test (liberal diagnosis) will classify almost all impaired persons as impaired, but will also classify many healthy persons as impaired (low specificity) (Lezak, 2012). In contrast, a very highly specific test (conservative diagnosis) will inevitably miss a considerable rate of impaired subjects (low sensitivity). The relationship between sensitivity, specificity and their corresponding classification errors (i.e. false positives or negatives) is exemplified in Table 4. It depends on the concrete context of a test's application how conservative or liberal a diagnosis should be assigned. Accordingly, false negative results can be preferred over false positive results and vice versa. For cognitive diagnostic purposes in the clinical context, a false positive classification can lead to more expensive, unnecessary and perhaps exhausting treatment for the patient. In case of awake craniotomy, a false positive test result would indicate the tested site as functionally necessary. In consequence, this site would be spared at the cost of optimizing the resection of tumor tissue. A false negative classification can result in a missed chance for rehabilitation or the removal of functionally necessary brain sites in awake craniotomy.

The respective probability that a subject with a positive or negative classification result (by the test) has the true condition is expressed as positive or negative predictive value (PPV and NPV) (Fawcett, 2006), by Strauss and colleagues (2006) referred to as positive and negative predictive power. **PPV** refers to the probability that an individual with a positive test result has the condition of interest (Strauss et al., 2006). **PPN** refers to the probability that an

individual with a negative test result does not have the condition of interest (Strauss et al., 2006).

Table 4: Cross-table of classification results of a binary test and selected measures of test quality

		True condition (as determined by gold standard)		
		condition positive	condition negative	
Condition predicted by test	test outcome positive	true positive	false positive (Type I error)	positive predictive value (PPV) = true positive / test outcome positive
	test outcome negative	false negative (Type II error)	true negative	negative predictive value (NPV) = false negative / test outcome negative
		true positive rate (Sensitivity) = true positive / condition positive	true negative rate (Specificity) = true negative / condition negative	Accuracy = true positive + true negative / total population

An effective method for evaluation of the performance of a diagnostic test is the calculation of receiver operating characteristics (ROC) and their visualization by **ROC-curves** (Park, Goo, & Jo, 2004). For each cutoff score sensitivity and specificity are calculated. The corresponding values of sensitivity and 1-specificity (false positive rate, FPR) are displayed in the ROC-curve (for an example see Figure 2). Each discrete point on the graph is called operating point (Park et al., 2004). ROC-curves can be used to determine an optimal cutoff score. To set a cutoff score for classification in a ROC-analysis, a cutoff score with an optimal balance between sensitivity and specificity is desirable (Moosbrugger & Kelava, 2012b). This point, at which the sum of sensitivity and specificity is at its peak, can be calculated (Youden-Index, Youden, 1950). In case of severe consequences following a false negative classification over a false positive classification, it might be useful to lower the cutoff score relative to the original Youden-Index. However, a verification of the classification is necessary in any case.

In addition, ROC-curves allow to assess the performance of a test independently of the cutoff score (Park et al., 2004). The most popular indicator for this purpose is the area under the ROC curve (AUC). The AUC can be interpreted as average value of sensitivity for all possible values of specificity. It ranges between 1 (perfect accurate test) and 0.5 (test results are pure chance as illustrated by the diagonal D in Figure 2 on the right side) (Park et al., 2004).

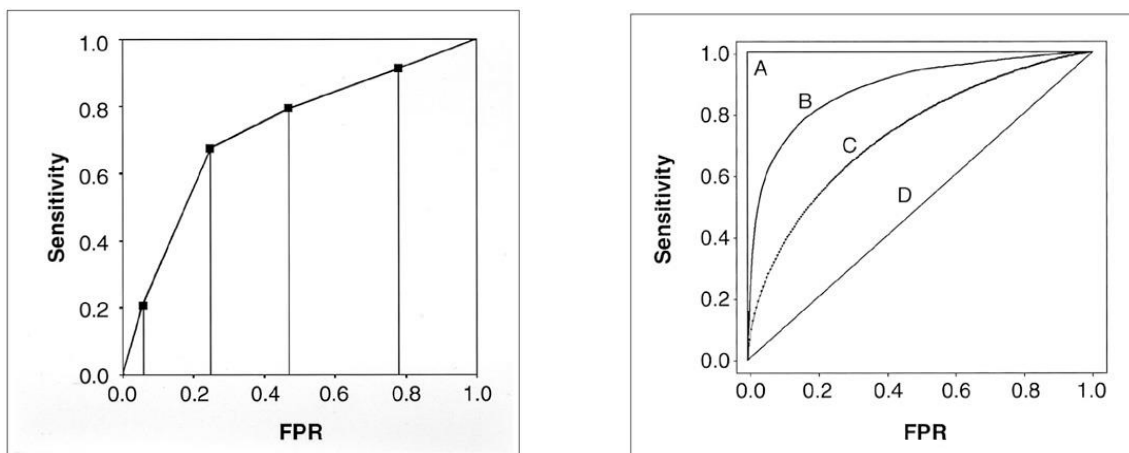


Figure 2: Exemplary Receiver operating characteristic curves (ROC). **Left:** Empirical ROC curve with discrete points (dots) in a plot of test sensitivity (y-axis) versus its false positive rate (FPR; x-axis) obtained at each cutoff level. Estimation of AUC (area under curve) by nonparametric approaches is possible. **Right:** Fitted or smooth ROC curves that are estimated with the assumption of binormal distribution, parametric estimation of AUC is possible. Curve A represents a perfect test (AUC = 1) and curve D a test with diagnostic performance of chance (AUC = .5). Test B has a higher AUC and a better overall diagnostic performance than C (taken with kind permission from Park et al., 2004).

2.2 Requirements for neuropsychological diagnostics in the neurosurgical emergency hospital

To illustrate the special requirements for neuropsychological diagnostics in the neurosurgical setting, the course of a glioma disease in an exemplary case patient is described in the following sections.

2.2.1 The patients

Patient A was at work when a sudden epileptic seizure let him fall unconsciously from his chair and injured his facial bones on the right side. After a few minutes, he slowly gained

consciousness, but felt disoriented and was unable to speak or properly understand the accident that injured his face. He was brought to the emergency hospital by an ambulance immediately.

In the vast majority of cases, the inpatient stay at the hospital starts unexpected. Many patients are brought to the emergency clinics since they complain about neurological and neuropsychological symptoms or experience an unexpected seizure like patient A. The medical routine diagnostic consists of a neurological examination, computer tomography (CT) and/or magnet resonance imaging (MRI). If a tumor is detected, a contemporary surgery is recommended in most cases to reduce further tumor growth, prevent seizures and initiate following treatment such as radio- and/or chemotherapy.

Factors such as the unexpectedness of the seizures, unfamiliar medical diagnostics and the diagnosis of a brain tumor can be perceived as highly threatening by the patient and may lead to subjective loss of control (Adelbratt & Strang, 2000; Perks, Chakravarti, & Manninen, 2009). In addition, the suggested treatment of an operation on the open skull, can be frightening and highly stressful for the patient (Goebel, Streng, & Mehdorn, 2012; Perks et al., 2009). Consequently, it is crucial to preserve physical and mental functions beyond the surgery to the best possible degree since their impairment can strongly decrease subjective quality of life (Shields & Choucair, 2014). Diaz and colleagues (2009) identified proper information sharing during the initial inpatient stay as a key factor to decrease anxiety levels of glioma patients. However, cognitive deficits induced by the brain tumor often hamper correct application of neuropsychological diagnostic tools and hinder communication about the diagnostic procedure and its goals. In addition, patients with intracranial tumors are often easily exhausted, which prevents extensive information sharing and assessment over several hours.

In summary, neuropsychological diagnostic in the setting of the neurosurgical hospital needs to be adapted to the needs of highly stressed and emotionally vulnerable patients (Habets et al., 2014). In addition, most patients show motor and language impairments combined with a reduced general state of health making additional adaptations of a test battery necessary.

2.2.2 The setting

Patient A was administered to the intensive care unit. He underwent CT and MRI scans and was finally diagnosed with a tumor in his left temporal lobe, one day after the initial epileptic seizure. He felt uncomfortable with the medial equipment attached to him. Lacking any medical background, it was hard for him to understand the information given by the physicians. He was worried about ignoring possible early signs of the tumor. The physicians recommended an operation on his brain within two days. However, the surgery bore the risk of severe persisting language deficits rendering speaking and understanding impossible.

In the setting of an emergency hospital, time is critical. Due to the early operation time point only a few days after hospital admission, neuropsychological diagnostic competes with several other time consuming diagnostics and educational appointments. In addition, the requirement of a trained neuropsychologist renders an extensive neuropsychological expensive. Consequently, many hospitals cannot afford to assess all patients with a comprehensive neuropsychological test battery. Therefore, they use cognitive screening instruments to identify patients in need for further assessment. This holds also for research trials on new medications for the treatment of intracranial tumors.

In summary, the amount of neuropsychological diagnostic is often restricted by low resources such as budgeted and diagnostic time, which contradicts the overall high diagnostic demand.

2.2.3 Examination purposes and approaches

The specific disease and its treatment in the emergency hospital account for particular questions, which need to be addressed by the neuropsychological diagnostic. The diagnostic course can be considered along the different treatment stages of preoperative, intraoperative and postoperative diagnostic. In the following, the different diagnostic steps are outlined.

2.2.3.1 Preoperative diagnostics

2.2.3.1.1 Cognitive status diagnostic

Patient A was registered for a preoperative neuropsychological status diagnostic. This has to be carried out at the intensive care unit since he was not allowed to leave the bed and health monitoring devices, due to his injuries and high risk of additional seizures.

Assessment of a patient's cognitive status aims at providing a cognitive profile for the most important functions such as language, executive functions, visuo-perception, visuo-motor speed and memory and should include a screening of the current emotional state (Goebel, Kaup, Wiesner, & Mehdorn, 2013). Additionally, basic data about a patient's socio-professional life such as employment, hobbies and activities should be assessed, because functionality in these areas are predictors for a patient's subjective quality of life (Giovagnoli, 2005). This information can be used to adjust a treatment strategy to a patient's individual needs (Duffau, 2014; Goebel et al., 2013). Comprehensive patient education about further treatment options and possible risks for impairment can rely on the cognitive assessment. In addition, the cognitive status before any treatment serves as baseline for further evaluation of treatment impact (Duffau, 2013). In most cases, the preoperative status diagnostic can be performed with a comprehensive neuropsychological **test battery** as described in chapter 2.1.1 Neuropsychological diagnostics. The test compilation can be tailored to the physical impairments of a patient: For instance, in case of a hemiparesis, this can be achieved by excluding tests that require intact motor ability of the dominant hand. **Screening tools** (see above) represent an alternative to a comprehensive neuropsychological test battery in significantly impaired or exhausted patients. Most screening tools provide a sum score for global cognitive functioning and allow a global classification into "impaired" vs. "non-impaired". However, they cannot provide valid information on the performance of distinct cognitive domains due to their brief extent.

Neuropsychological assessment of Patient A was successfully performed on the intensive care unit. However, the neuropsychological test battery had to be reduced. Tests which relied on fast drawing were not used, as the patient had to stay in bed. The assessment revealed impaired verbal memory, semantic word fluency and verbal comprehension as well as increased anxiousness. An additional functional MRI located the patient's language functions in direct vicinity to the tumor. This raised the question whether the operation

should be performed under local anesthesia or intubation narcosis. An evaluation of his eligibility for an awake craniotomy was requested.

For patients with intracranial tumors within eloquent areas, an additional neuropsychological appointment is necessary to assess their **eligibility** for an operation under **local anesthesia (awake craniotomies)**. An awake craniotomy can represent a highly stressful and potentially traumatic procedure for the patient and therefore makes a careful preoperative patient selection mandatory (Nossek et al., 2013). Especially in the context of awake craniotomy, a cognitive profile of deficits and resources is helpful to estimate a patient's intraoperative resilience and compliance. In addition, the cognitive baseline profile provides information on tasks which should be assessed during awake craniotomy to prevent further impairment (for details see chapter 2.2.3.2 Intraoperative diagnostics) (Duffau, 2013). If awake surgery is done in functional areas for sensory-motor function, the cognitive baseline profile is complemented by a sensory-motor baseline assessment as explained in publication two included in this thesis (Becker, Jehna, Steinmann et al., 2016).

2.2.3.1.2 Patients' eligibility for an awake craniotomy

The **initial selection** criterion for patients to undergo awake craniotomy is a medical decision based on structural MR-images. If functional cortical areas or white matter tracts are assumed to be located close to the tumor, an awake craniotomy should be considered (Nabavi et al., 2009). Functional MRI (fMRI) can be used to verify the location of eloquent areas relative to the tumor and provides additional information on the functional-neuroanatomic relationship between the tumor and surrounding brain structures (Nabavi et al., 2009). Unfortunately, fMRI based functional maps are prone to errors due to altered brain perfusion near the tumor and cannot replace intraoperative DCS mapping (Duffau, 2011a, 2011c). For concrete surgery planning, diffusion tensor imaging (**DTI**) and computer based virtual reconstruction of white matter fiber tracts (**tractography**) is frequently used (Bello et al., 2011). This method was introduced by Catani and colleagues (2002) as "*in vivo* dissection" and allows a preoperative clear visualizations of the white matter structures near the tumor (Bello et al., 2011; Catani et al., 2002; Catani & Thiebaut de Schotten, 2008). Figure 3 displays examples for this visualization method, showing tumors growing in the frontal lobe near the pyramidal tracts. DTI uses diffusion characteristics of water molecules,

which differ in grey and white matter. Water molecules will diffuse more rapidly in the direction aligned with the internal structure and slower perpendicular to the preferred direction. This causes a preferential direction of diffusion along the direction of white matter fibers. Diffusion preference can be measured, reconstructed and color coded for the whole brain by special analysis software. Further steps of analysis calculate probabilities for the course of the tracts and finally allow visual reconstruction of the most likely pathway of white matter tracts (probabilistic tractography; Behrens et al., 2003). Deterministic approaches rely on the concrete measured main direction of diffusion inside of a voxel and stop when certain cancellation criteria are reached (Pierpaoli, Jezzard, Basser, Barnett, & Di Chiro, 1996). Both methods strongly depend on the applied analysis methods/models and software, which can result in different visualizations of the same white matter tracts in the same patient (Bürgel et al., 2009). In addition, the computed visualizations may significantly deviate from the in vivo arrangement (Bello et al., 2011).

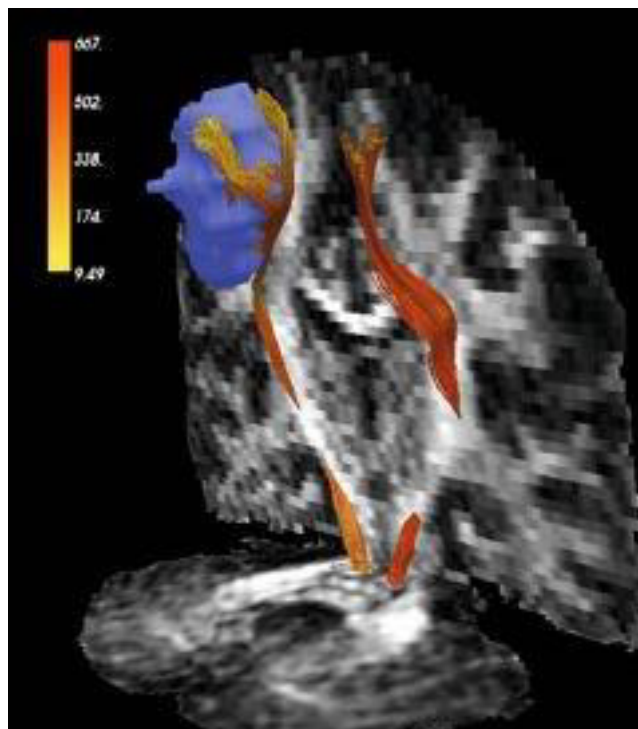


Figure 3: Tractography of the corticospinal tracts (red). In the left hemisphere, the pyramidal tract is running in close proximity to a tumor (in light blue) in the peri-rolandic area. The two corticospinal tracts are overlaid on coronal and axial maps of fractional anisotropy (anisotropy: preference for molecules to diffuse in an direction dependent manner, opposed to isotropic i. e. identical diffusion in all directions) (with kind permission taken from Duffau, 2011b, p. 68).

A detailed overview of large white matter tracts and their (cognitive) functions was provided by Catani and colleagues (2008) in the so called “DTI tractography atlas”. In the individual patient, a visualization of white matter tracts by DTI based tractography can help to clarify the operating strategy and facilitate an estimation of functional impairment caused by surgery. Despite major improvements of the technique in the last decade, these visualizations are still estimations of individual white matter arrangement in a patients’ actual brain. DTI tractography exhibits measurement errors caused by visualization algorithms and/or by tumor specific factors such as impeded measurement of diffusion due to peritumoral edema. Thus, DTI tractography cannot replace but rather complement intraoperative DCS (Duffau, 2011b).

After initial MRI- and DTI-based selection the rationale of an awake craniotomy is discussed with the patient and if necessary, additional baseline assessment for mapping purposes is performed during a special **preparation appointment**. Nossek and colleagues (2013) evaluated failed awake craniotomies. They identified the role of patient preparation during the preoperative phase as crucial factor for the patient’s cooperation and avoidance of intraoperative complications (Nossek et al., 2013). From the neuropsychological perspective, the aim of the preparation appointment is an estimation of the patient’s functional and psychological eligibility for awake craniotomy. In addition, tasks for intraoperative diagnostics are practiced during the preparation appointment (Talacchi, Santini, Casagrande et al., 2013).

2.2.3.1.2.1 Functional eligibility

Functional eligibility refers to a patient’s cognitive *and* physical state of health and the requirements on this functionality for an awake craniotomy. Both aspects of functionality are mandatory for successful awake craniotomy.

Prior to the preparation appointment, the neuropsychological status diagnostic provides data on the patient’s **cognitive functionality** such as the ability to speak, understand, concentrate and execute commands necessary for successful realization of an awake craniotomy. Specifically, the patient’s language has to be fluent enough to express himself in a reliable manner. Further, he must be able to communicate alterations in cognitive and

physical functions, dizziness, pain and other discomfort during the operation. Verbal comprehension is highly important as the patient needs to understand instructions, reassurance attempts and questions correctly. Memory functions are mandatory to ensure correct recall of information and advice given prior to surgery. Attention is important to understand and follow all the necessary tasks. Intact visual functions are mandatory if pictures need to be named intraoperatively.

Explicit **exclusion criteria** for awake craniotomy regarding cognitive functionality do not exist to date. However, Picht and colleagues (2006) as well as Nabavi and colleagues (2009) give a first orientation: Patients scoring below 23 points in the MMSE and a failure rate above 50% in standardized language tasks were excluded in their studies. Apart from that, they emphasize inhibited, apathic and disorganized behavior patterns as predictors for intraoperative noncompliant behavior and therewith exclusion criteria for an awake craniotomy. In a study by Santini and colleagues (2012), patients with 30% or more errors in a standardized picture naming task, were excluded from awake surgery. Other authors excluded patients at a 10% or >25% error cutoff (Santini, Talacchi, Squintani et al., 2012; Talacchi, Santini, Casagrande et al., 2013). A high failure rate in picture naming is assumed to interfere with a reliable interpretation of intraoperative test results. This is due to the fact that speech disturbances after DCS cannot be traced back to the exclusive effect of DCS. Alternatively, the naming disorder caused by the initial aphasia itself may have caused the effect. This might result in an increase of the false positive rate during cortical stimulation.

Beside cognitive functionality, **physical functionality** is the other essential category for preoperative evaluation. Since the procedure will often last for several hours and is exhausting, a moderate to good general health status is necessary to face an awake craniotomy (Talacchi, Santini, Casagrande et al., 2013). Santini and colleagues (2012) defined a Karnofsky performance scale of >70% as a possible inclusion criteria. Moreover, if sensory-motor functions are mapped during the awake surgery, a sufficient functionality in these categories is mandatory. Severe motor and sensory impairments hinder differentiated evaluation during the operation and represent exclusion criteria for awake operations in these cases.

Preservation of sensory-motor and language functions are the most frequent reasons to undergo an awake craniotomy (Duffau, 2011d). Despite this fact, a standardized and reliable

assessment of sensory-motor functions in awake craniotomy is not established to date. As a consequence, no standardized guidelines for exclusion criteria are available. The second study of this thesis (Becker, Jehna, Steinmann et al., 2016) describes an approach to design an efficient and feasible assessment tool for this context in detail.

If sensory-motor function is a focus of awake craniotomy, a detailed sensory-motor baseline is assessed to supplement the cognitive baseline profile. Similar to cognitive assessment, sensory-motor baseline testing serves as the reference point for further appraisal of a patient's functions i) in the operating room for mapping purposes, ii) after the surgery for evaluation of outcome and iii) later on for follow-up after rehabilitation. In patients with language impairments, the sensory-motor baseline assessment represents a valuable opportunity to assess the ability to understand the commands *and* carry out the tasks accordingly. In addition, the risk of impairments in sensory-motor function during and after the surgery should be discussed with the patient. The individual social and professional life defines subjective limits for impairments. For instance, loss of fine motor skills bears a high risk for reduction of subjective quality of life for a passionate musician while other patients might tolerate such impairments (Duffau, 2009b). Figure 3 shows an example of a patient with a high risk of functional impairment, requiring detailed preoperative information. The pyramidal tracts, necessary for motor functions, are running in direct neighborhood to the tumor. In this case, the patient needs to be prepared for possible motor impairment during and after the operation. This ensures clear agreement on tolerable impairments and reduces the risk of unexpected intraoperative deficits.

A detailed description of sensory-motor tasks for awake craniotomy is presented in the second publication included in this thesis (Becker, Jehna, Steinmann et al., 2016). The use of other tasks is explained in section 2.2.3.2 Intraoperative diagnostics.

2.2.3.1.2.2 Psychological eligibility

Awake craniotomy is highly demanding for a patient's psychological stability and coping mechanisms. Talacchi and colleagues (2013) summarized the importance of a good eligibility evaluation as follows: "Although awake craniotomy is generally considered to be well tolerated, complications such as emotional distress and agitation are reported and lead to

loss of control, the need for more sedation, and failure of the mapping project. Once the patient has been given a detailed description of the procedure and provided his fully informed consent, the decision to operate will depend on whether he can be reasonably expected to be cooperative. Failure rates due to agitation vary from 2 to 8%, but are not systematically reported (Sahjpaul, 2000).” (p. 212). First suggestions for criteria regarding **psychological eligibility** in awake craniotomy were provided by Santini and colleagues (2012). Anxiety, the attitude to pain, depression and capacity for self-control were assessed in their pilot study. Fear of pain and anxiety were found to be possible warning signs for a failure of the awake craniotomy due to patient’s incompliance. To date, there are no other clinical articles available addressing the psychological eligibility of patients scheduled for awake craniotomy. Due to the absence of empirical data, the appraisal of psychological eligibility is mainly based on the clinical experience of the neuropsychologist. During inpatient stay, there are several opportunities to collect data for this rating. First, behavioral monitoring during cognitive assessment provides valuable information on a patient’s ability to tolerate frustration and remain compliant under stressful situations. Second, a preparation appointment provides further opportunity for behavioral monitoring and evaluation. During a detailed discussion of the operating procedure and risks, the patient is confronted with highly emotional topics that can be used to test psychological coping abilities. Third, explicit discussion of anticipation and fear provides additional valuable information on psychological eligibility for the procedure. A patient’s emotional stability and functionality can be considered sufficient, if one can assume that he is able to undergo awake craniotomy with high compliance and reasonable emotional distress.

Patient A underwent evaluation for physical and psychological eligibility for awake craniotomy. He fulfilled basic criteria of language and sensory-motor function and was expected to undergo the procedure with high compliance.

He understood the rationale for an awake craniotomy and agreed on the procedure. However, he felt nervous about being conscious during the drilling of his skull and resection of the tumor. His motivation for an awake surgery was to preserve his ability to speak and understand to the best possible degree. The baseline assessment of his sensory-motor and language functions showed a high performance, enabling a good differentiation between

baseline and new impairments during the operation. His general state of health assessed with the Karnofsky Performance Status was rated 70-80%. The operation was scheduled for the next day.

2.2.3.2 Intraoperative diagnostics

The key functions of a neuropsychologist during intraoperative diagnostics can be summarized as follows: i) performing the neuropsychological testing, i.e., requesting the patient to perform tasks under DCS and ii) accurate interpretation of the various disturbances induced by DCS (Duffau, 2011a).

Representative tasks to map **motor functions** involve the request to move facial muscles, arms, hands, fingers or legs. Sensory assessment is commonly performed by touching the patient's extremities and recording his feedback. The elaborate work of Chacko and colleagues (2013) provides a summary of possible events under awake craniotomy that need to be taken into account by the neuropsychologist. This includes for instance deceleration of movement, weakness and delayed response (Chacko et al., 2013). Their findings emphasize the value of a distinction between elicitation of a function and its inhibition in response to DCS (Mandonnet, 2011). In case of evocative stimulation, the patient might for instance report muscle twitches or sensations. In case of inhibition, changes in movement' quality during motor task performance can be observed (Mandonnet, 2011).

To date, there is no literature available on the comparison of different motor tasks for intraoperative diagnostic. This holds also true for intraoperative alterations of cognitive and motor functionality and their ability to predict a postoperative long-term outcome. The reviewed literature revealed a large variety of methods used for intraoperative mapping of sensory-motor functions across different institutions (Duffau, Capelle, Denvil, Sichez, Gatignol, Taillandier et al., 2003; Whittle, Borthwick, & Haq, 2003). In addition, the applied methods covered mainly semi-standardized or unstandardized tasks and rating systems. Even more critical, in most cases baseline and postoperative assessment differed from intraoperative assessment methods (Duffau, Capelle, Denvil, Sichez, Gatignol, Taillandier et al., 2003; Whittle et al., 2003). Thus, comparison of results between institutions is hampered and valid conclusions on the advantages of awake craniotomy relative to intubation narcosis

are difficult to draw (Talacchi, Santini, Casagrande et al., 2013). This topic was addressed in the second publication of this thesis (Becker, Jehna, Steinmann et al., 2016).

In case of **language mapping**, tasks are presented simultaneously with DCS. Naming of objects presented on a screen is one of the most common tasks that was already used by Whitaker and Ojemann (Talacchi, Santini, Casagrande et al., 2013; Whitaker & Ojemann, 1977). Figure 4 illustrates an example of a presentation slide for awake cortical mapping. The patient is requested to read a sentence (“This is a...”) and subsequently name the presented target object. A picture is usually presented for 4 seconds and the patient’s response is recorded (Talacchi, Santini, Casagrande et al., 2013). The electrical impulse is usually applied to the brain’s surface with picture onset (Talacchi, Santini, Casagrande et al., 2013).

This is a...

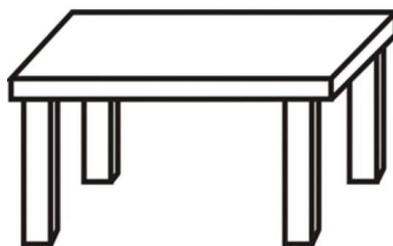


Figure 4: Example picture from a picture naming task for awake craniotomy.

Language impairments during DCS range from naming disturbances to complete speech arrest (Talacchi, Santini, Casartelli et al., 2013). A systematical evaluation of the characteristics and distribution of naming errors during cortical mapping with DCS was presented in 2010 by Corina and colleagues (2010). They differentiate six common types of errors and were able to provide neurosurgeons with a preoperative map of possible errors at different locations of resection (Corina et al., 2010). Beside object naming, other language tasks such as word generation (verbal fluency), speech comprehension and reading are used for intraoperative diagnostics (Giussani et al., 2010).

Although mapping of language functions is already performed since four decades, the standardization of intraoperative tasks other than naming, is still in its infancy (Rofes, Aguiar,

& Miceli, 2015). Recently, several publications addressed this issue and made first proposals for intraoperative selection and combination of language tasks by taking the tumor location and the presumed language deficits into account (Coello et al., 2013; De Witte, Satoer, Colle et al., 2015; De Witte, Satoer, Robert et al., 2015, De Witte & Mariën, 2013, 2013; Rofes et al., 2015; Rofes & Miceli, 2014). Future studies on the predictive validity of different types of errors might provide information about the likelihood of permanent language dysfunction after resection of a critical site and its impact on the patient's life. For instance, Moritz-Gasser and colleagues (2012) found a significant positive correlation between the speed of lexical access and later return to professional life.

Beside language and sensory-motor functions, **other (cognitive) functions** might also be located in the vicinity of the tumor. Within the last years, the research interest on higher order cognitive functions has substantially grown and valuable information about their functional-neuroanatomic location in the human brain was gained (Duffau, 2011b). Furthermore, case reports and small cohort studies report promising approaches for intraoperative evaluation of calculation, visual perception, spatial cognition, memory, executive functions and singing (Duffau et al., 2002; Duffau, 2010, 2011d; Wager et al., 2013). However, methods for intraoperative diagnostic of these functions are still in the experimental stage.

Independent of the intraoperative tasks, awake craniotomy aims to preserve functional tissue around or in the tumor. There is evidence that functional tissue can be subdivided into compensable and essential areas (Desmurget et al., 2007). **Compensable areas** support (cognitive) function. After resection, only transient disturbances are induced. Contrariwise, essential areas are primarily *necessary* for a particular function and cannot be resected without permanent deficits (Desmurget et al., 2007). Resection of essential areas should therefore be avoided. According to the gold standard, a cortical site is considered as essential when functional disturbances can be elicited three times by DCS (Duffau, 2011a). At first glance, it seems intuitive to distinct between essential and compensable brain areas and to follow the rationale of sparing essential areas. However, the relation between DCS induced disturbances and postoperative functionality is not linear. For instance, DCS of the posterior part of the SMA, elicits positive motor responses and its resection leads to immediate postoperative deficits such as hemiparesis, akinesia and mutism (Rutten &

Ramsey, 2011). These symptoms typically resolve within several months, during which a functional transfer to the contralateral SMA takes place (Rutten & Ramsey, 2011). This example emphasizes the importance of future integrative research on resectability of areas and their neuroplastic adaption for successful awake craniotomy, with the general aim to maximize resection while minimizing the risk of permanent deficits.

In summary, intraoperative decisions with respect to the resection of an area rely on i) valid and sensitive intraoperative diagnostic with appropriate tasks, ii) a valid decision strategy (three positive responses to DCS) and iii) the integration of knowledge about neuroplasticity. Specifically, phenomena such as a delayed manifestation of a deficit, fast recovery of initially inhibited functions by dynamical short-term plasticity and late recovery due to biological long-term plasticity complicate intraoperative decisions for resection (Mandonnet, 2011). Future research on the predictive validity of intraoperative responses to DCS during specific tasks is urgently required.

Patient A underwent awake craniotomy with mapping and monitoring of language and sensory-motor functions. Due to intraoperative language disturbances, functional areas that were infiltrated by the tumor were preserved to avoid permanent functional loss.

2.2.3.3 Postoperative diagnostics

Patient A recovered quickly from the awake craniotomy. During the first days after the surgery, he showed medium impairments of language comprehension and word fluency, but symptoms improved until discharge. A specialized rehabilitation institution for language therapy was suggested according to his cognitive status diagnostic (with the focus on language) five days after the operation. Further improvement of language functions was determined in the follow-up neuropsychological assessment two months after the surgery. Ambulant neuropsychological therapy was initiated and stepwise vocational reintegration followed.

Directly after the operation, the diagnostic of language deficits is highly important. Early detection of language disturbances allows the early start of language rehabilitation which

significantly improves the outcome (Frommelt, 2010). If applicable, a second status diagnostic could quantify the immediate operative outcome and might help to find a suitable rehabilitation clinic (Duffau, 2013). Targeted rehabilitation of sensory-motor functions in patients with intracranial tumors is also initiated early after surgery, but needs to be well balanced to avoid adverse side effects due to overuse (Xerri, 2011).

During the time course of the disease, repeated neuropsychological diagnostic helps to quantify multiple outcomes (operative long-term outcome, effects of radio- and/or chemotherapy and rehabilitation) and provides a data set for further planning of therapeutical support. For most patients, return to normal social life and work are most important goals. With the help of personalized therapeutic strategies over years, these goals are achievable, particularly for LGG patients (Duffau, 2013). Finally, there is evidence that cognitive decline precedes visual signs of tumor recurrence on MR-images (Klein et al. 2012; Meyers et al. 2000), further underlying the importance of a comprehensive follow-up diagnostic.

From a **scientific perspective**, regular neuropsychological follow-up assessments provide information on the brain's adaption to a lesion and its potential for neuroplasticity. Simultaneously acquired MRI-data can provide insight into structural correlates of functional alterations. The acquired data should include information about the patient's sensory-motor and cognitive functionality as well as quality of life in addition to the overall survival time. This integrative and patient- oriented approach allows valid comparison for example between surgical procedures (awake vs. asleep craniotomies) or evaluation of the impact of intraoperative methods such as MRI, ultrasound or neuro-navigation. In addition, clinical studies investigating novel treatment options such as chemotherapeutic drugs use repeated cognitive follow-up assessments to determine side effects on wellbeing and cognition. Unfortunately, they often use screening tools instead of comprehensive test batteries (Folstein et al., 1975; Meyers & Brown, 2006; Meyers & Wefel, 2003; Patel & Mehta, 2007).

2.3 Research questions and study aims

The above discussed literature revealed substantial gaps in the clinical diagnostic process for glioma patients. The overall aim of the studies included in the present thesis was to improve

pre-, intra- and postoperative neuropsychological diagnostics. To this end the following research questions and specific aims were addressed:

I. The setting of emergency hospitals and the available resources in clinical research do often not allow for a comprehensive neuropsychological evaluation of cognitive functions. Therefore, the first main question was whether an excellent cognitive screening instrument might be able to substitute a comprehensive neuropsychological test battery, especially in the context of preoperative cognitive assessment. Consequently, the first publication (Becker, Steinmann et al., 2016) investigated whether the recently published screening tool BCSE has overcome the limitations of the MMSE and MoCA and represents a valid tool for patients with intracranial tumors.

II. In the context of awake craniotomy, expert consultation as well as a review of the existing literature revealed the lack of a feasible and standardized tool for pre-, intra- and postoperative assessment of sensory-motor function. The second publication (Becker, Jehna, Steinmann et al., 2016) therefore sought to develop a standardized diagnostic tool for such a setting and evaluate its feasibility in glioma patients eligible for awake craniotomy.

III. As previously described, the evaluation of postoperative outcome provides valuable information on the consequences of the resection. Research on neuroplasticity based on large cohort studies or randomized trials is difficult or impossible to conduct. Consequently, case reports on patients with a unique disease constellation provide valuable information. Therefore, the third publication (Becker, Jehna, Larsen, Synowitz, & Hartwigsen, 2016) investigated pre- and postoperative basic cognitive and language function in a patient with a congenitally absent left hemisphere and a HGG to elucidate plastic changes in the reorganized brain

3 EMPIRICAL STUDIES

3.1 Publication I - Cognitive screening in patients with intracranial tumors: Validation of the BCSE

This section presents the first publication (Becker, Steinmann et al., 2016). Here we investigated whether the recently published screening tool BCSE has overcome the limitations of the MMSE and MoCA and represents a valid tool for patients with intracranial tumors.

Cognitive screening in patients with intracranial tumors: validation of the BCSE

Juliane Becker¹ · Elisabeth Steinmann¹ · Maria Könemann¹ ·
Sonja Gabske¹ · Hubertus Maximilian Mehdorn¹ ·
Michael Synowitz¹ · Gesa Hartwigsen^{2,3} · Simone Goebel¹

Received: 16 September 2015 / Accepted: 22 January 2016
© Springer Science+Business Media New York 2016

Abstract This study presents the first validation of the Brief Cognitive Status Exam (BCSE) against two other screening tools for cognitive impairment in patients with intracranial tumors. 58 patients and 22 matched healthy controls completed the BCSE, the Mini Mental State Examination (MMSE) and the Montreal Cognitive Assessment (MoCA). Patients were additionally tested with a comprehensive neuropsychological battery. Based on this assessment, they were classified as cognitively impaired or unimpaired on five cognitive domains. Analyses revealed a comparable feasibility of the BCSE relative to the MoCA and the MMSE, but a smaller range of assessed functions (e.g., no correlation with the domain visual-spatial functions). The ability to separate patients and healthy controls was extremely poor for BCSE and MMSE (sensitivity of 38.6 % and less), but moderate for MoCA (sensitivity 68.97 %). Detection of cognitive impairment in patients was worst with BCSE (sensitivity 37 %; MoCA 92.9 %, MMSE 44.4 %) as compared to neuropsychological testing. Moreover, prediction of cognitive outcome was also worst for the BCSE (AUC = .713, NPV = 50 %). An optimal cut-off of 50.5 increased the

results slightly. In summary, the BCSE showed good feasibility but no sufficient results in separating healthy individuals from patients or detecting cognitive impairment in patients. Consequently, as a screening measure, we would recommend the MoCA instead of the BCSE. However, since even the MoCA failed to detect cognitive impairment, our study supports the view that reliable results could only be obtained with a comprehensive neuropsychological battery.

Keywords Screening instrument · Neuropsychological diagnostic · Intracranial tumor

Introduction

Intracranial tumors refer to any solid neoplasm inside the bony skull. Their growth can alter normal brain function and cause symptoms like increased intracranial pressure, neurological deficits, epileptic seizures and (neuro-) psychological changes. Common treatment for intracranial tumors includes neurosurgical operations, chemotherapy and/or radiotherapy. These treatments, as well as the growth of the intracranial tumor mass and possible infiltration of brain tissue are likely to account for the frequently reported reduced cognitive abilities in this patient group [1–8].

Cognitive performance relies on intact sensory and motor abilities and several discrete functions. They are typically assessed during neuropsychological examinations that consider multiple domains representative for both hemispheres, including memory, attention, orientation, speech and executive functions [8]. Precise identification of (even minor) cognitive impairments is on one hand important for clinical patient management since it

Electronic supplementary material The online version of this article (doi:10.1007/s11060-016-2064-6) contains supplementary material, which is available to authorized users.

✉ Juliane Becker
juliane.becker@uksh.de

¹ Department of Neurosurgery, University Hospital Schleswig-Holstein, Arnold-Heller-Straße 3, 24105 Kiel, Germany

² Department of Psychology, University of Kiel, Kiel, Germany

³ Department of Neuropsychology, Max Planck Institute for Human Cognitive and Brain Sciences, Leipzig, Germany

determines further treatment options like cognitive and social rehabilitation. Moreover, cognitive impairment is a predictor of recurrence and survival [3, 9] and is associated with an overall decrease in quality of life and execution of activities of daily living [10, 11]. On the other hand, identification of cognitive impairment is particularly important for research studies that include cognitive status as an outcome measure, for example in evaluation of treatment effects and side effects [8, 9, 11, 12]. The current gold standard recommends a comprehensive neuropsychological test battery with a duration of at least one hour for assessment of cognitive domains [13]. However, comprehensive testing is very costly as it necessitates trained personal, test rooms, testing materials and time. Therefore, many clinical trials rely on short screening tools like the MMSE [12, 14–16]. However, it is questionable whether cognitive screening instruments represent valid alternatives to comprehensive neuropsychological test batteries in some settings and patients [12, 15, 17]. As one of the few studies considering a comparison of screening tools against the gold standard of a comprehensive neuropsychological test battery, Olson and colleagues [18] compared the screening tools MMSE and MoCA [19] in patients with intracranial tumors ($n = 58$). They reported a sensitivity of only 61.9 % for the MoCA and 19 % for the MMSE and a specificity of 94.4 % for the MMSE (MoCA 55.6 %) relative to a 3–4 h neuropsychological assessment battery. Further analysis failed to reveal any cut-off score where satisfying detection of cognitive impairment in this population was possible and further investigations of the MoCA in this collective were recommended. Hence, valid alternative screening tools for detection of cognitive decline are desirable. The need for studies involving new, alternative screening tools was further stressed by the results of a previous study in acute stroke patients that demonstrated an underestimation of cognitive impairment for the MoCA compared to a neuropsychological assessment [20].

The novel screening instrument BCSE [21] might represent a promising tool for this purpose. However, to the best of our knowledge, this test has not been compared to the gold standard of a test battery to date. Consequently, the validity and diagnostic properties of the BCSE to identify cognitive impairment in patients with intracranial tumors remain to be determined.

The primary goal of this study was to explore whether the BCSE is a superior alternative for neuropsychological screening as compared with the MoCA and MMSE in patients with intracranial tumors. A validation of this novel tool was mandatory since this test has not been used in patients with intracranial tumors so far. Therefore, our first aim was to examine the feasibility and convergent validity of the BCSE in comparison to the established screening instruments MoCA and MMSE.

Secondly, we aimed at providing a comprehensive comparison of the sensitivity and specificity and other diagnostic properties of the BCSE relative to MoCA and MMSE. Particularly, we examined whether the BCSE would be more reliable than the older screenings in (i) detecting patients with intracranial tumors versus healthy subjects and (ii) detecting cognitive impaired subjects in a patient cohort asserted by the gold standard of a comprehensive neuropsychological test battery covering several cognitive domains.

The neuropsychological test battery in our study was conceptualized as a German version of the cognitive domains suggested by Olson and colleagues [18] but was considerably shorter in terms of assessment time. This was mandatory to reduce the influences of exhaustion, selection bias and split assessment that was reported previously [18]. Thereby, we aimed to reduce the dropout rate and gain complete neuropsychological profiles for each patient.

Methods

Screening-instruments

The *BCSE*, as part of the Wechsler Memory Scale—Fourth Edition [21], is a screening tool to assesses basic cognitive functions: orientation to time, incidental recall, mental control, planning/visual perceptual processing, inhibitory control, and verbal productivity. The necessary assessment time ranges between 7 and 11 min. To the best of our knowledge, only one previous study evaluated the BCSE [22] by comparing it with the MMSE in patients with mild cognitive impairment (MCI) or dementia and healthy controls. The BCSE provided a better sensitivity in patients with Alzheimer's dementia. However, it was less specific in correctly distinguishing older adults with MCI from healthy controls. The present study should thus represent the first validation of the diagnostic properties of the BCSE in patients with intracranial tumors.

The *MoCA* evaluates cognitive functions in about 10 min [19]. Current studies show a clear advantage over the MMSE also in neuro-oncological patients [6, 23, 24]. The MoCA provides a relatively higher sensitivity compared to the MMSE [19, 24–26] and is less affected by ceiling effects [27] as it includes more demanding tasks [19]. However, specificity was lower than in MMSE [19, 23, 25, 26]. It was previously validated in patients with intracranial tumors [24].

The *MMSE* [14, 28] assesses cognitive functions also in about 10 min. The MMSE is often used in patients with intracranial tumors [2, 29, 30], although it has not been systematically validated in these patients to date [16, 29]. Moreover, application in patient groups other than

dementia has been criticized [30] as it demonstrated a relatively low validity [12, 16, 19, 26, 31].

Feasibility analysis

We assessed admission time and subjective perceived tolerability and strain for each screening instrument. For the latter, we modified the ranges of a visual analogue scale (VAS) [32] from “not at all tolerable” (0) to “very tolerable” (10) and respectively from “not at all exhausting” (0) to “very exhausting” (10). In addition, patients had to state which screening tool they would prefer. For subjective validity, they were asked which of the screening tools was best in measuring their perceived changes due to the disease.

Cognitive domains

Table 1 displays the applied test battery, which was based on two previous studies (see Online Resource 1 for procedure of assessment) [7, 10]. Both used comprehensive neuropsychological test batteries and assigned tests to particular domains. In the study by Satoer and colleagues [7], lexical word fluency was assigned to the domain language. In contrast, semantic word fluency was assigned to the domain “memory” in the present study since areas involved in executive and verbal functions seem to support semantic word fluency, but contribute less to this task than temporal (i.e., memory related) regions [33]. Indeed, neuroimaging studies revealed stronger activation in the left hippocampal areas than in the dorsolateral pre-frontal cortex for semantic word fluency [34].

Subjects

All eligible patients scheduled for routine neuropsychological examination between April 2013 and July 2014 were pre-screened for study participation. The control group was recruited among relatives and matched to the patient group in terms of age, years of education and gender (for detailed information see Online Resource 1).

Statistical analysis

The data analyses were carried out with the statistical package for social sciences (SPSS) Version 21...0 and MedCalc V.12.2.1.0. For a detailed description of the statistical analysis concerning the preliminary analysis including feasibility and validity see Online Resource 1.

We referred to the cut-off scores reported in the respective manuals for group definition of cognitive status variables in the screening tools. All subjects reaching lower scores were labeled as “cognitively impaired.” In case of

the MMSE, we used <26 as cut-off [14]. For the MoCA and the BCSE, we used the standard cut-off scores of <27 or the percentile rank of <15 , respectively [19, 21].

In the test battery, cognitive impairment was assumed when at least one domain was indicative of impairment [1, 43]. For each domain, we obtained a z-score following the procedure outlined by two previous studies, for details see Online Resource 1 [1, 44].

In a first step, we calculated sensitivity, specificity, positive predictive value (PPV), negative predictive value (NPV) and diagnostic accuracy (DA) in detecting patients with intracranial tumors among healthy controls for the BCSE, MoCA and MMSE. Secondly, we tested these screening tools against a neuropsychological test battery. In each case, receiver operating characteristic (ROC) curves were constructed. The area under the curve (AUC) was calculated for each ROC curve as a measure of test accuracy. Statistical significances of the differences between AUCs were assessed with a non-parametric approach [45]. Optimal cut-off values were derived at ROC coordinate points where both sensitivity and specificity were optimized using the Youden Index [46]. In addition, we again calculated sensitivity, specificity, PPV, NPV and DA for the three screenings at these optimal cut-off scores.

Results

Subjects

In this prospective study trial, 58 patients participated before or after ($n = 5$) their neurosurgical operation (for details see Online Resource 2: Flowchart of the recruitment process). Sample characteristic are shown in Table 2. 58 patients (50 % female) aged 27–80 ($M = 58.03$; $SD = 13.94$) completed the whole assessment in 75–115 min; two of them completed only the screening instruments due to fatigue and exhaustion (1 of them only MoCA). Results regarding the prevalence of cognitive impairment are displayed in Online Resource 2.

The healthy, matched control subjects ($n = 22$) did not reveal any differences in age, gender or education (for details see Online Resource 2). Overall, the control group had significantly higher scores on each screening tool than the patient cohort.

Preliminary analysis

Analysis of feasibility

Assessment time for all three tools varied between 2 and 21 min (BCSE: $Md = 8$, range 4–15; MMSE: $Md = 5$, range 2–15, MoCA: $Md = 10$, range 3–21). The perceived

Table 1 Neuropsychological test battery

Domain/test	Cognitive abilities	Description
Language		
Subtests of the Aachen Aphasia Test (AAT, [35])		
Token test	Verbal comprehension	Pointing to and manipulating geometric forms on verbal command
Naming	Word finding	Naming Objects, colors and complex activities
Written language	Verbal academic skills	Writing to dictation and reading aloud
Language comprehension	Auditory and reading comprehension	Finding the object/scene out of three distracting stimuli
Lexical word fluency [36]	Phonological fluency	Producing words beginning with a given letter within 2 min
Attention and visuo- motor speed		
Digit Span [37]	Attention and working memory	Immediate repetition of digits forward and in reverse order
Trail-making test part A (TMT-A, [38])	Visuo-motor speed	Connecting 25 encircled numbers
Memory		
Memo-test [39]	Immediate and delayed verbal memory	Learning 10-item wordlist within five repetitions, recall after 15 min
Rey-Complex-Figure-Test (CFT, [40]) delayed recall	Implicit visual-spatial memory	Reproduction of the copied figure from memory
Semantic word fluency [36]	Semantic memory	Naming animals within two minutes
Executive functions		
Five-point test (FPT, [41]) sub score productivity	Figural fluency	Production of patterns by connecting dots within rectangles within three minutes
Trail-making test part B (TMT-B, [38])	Cognitive flexibility, visuo-motor speed	Connecting 25 encircled numbers and letters in alternating order
Semantic alternating categorical word fluency [36]	Flexibility of verbal fluency	Naming sports and fruits alternating within two minutes
Visuo-spatial functions		
Visual Object and Space Perception battery (VOSP, [42])		
Object decision	Object perception	Detecting silhouettes of a real object among fantasy drawings
CFT [40] copy	Visual-spatial processing	Copying a complex figure

AAT Aachen aphasia test; CFT Rey-complex-figure-test; FPT Five-point test; TMT-A Trail-making test part A; TMT-B Trail-making test part B; VOSP Visual object and space perception battery

strain of the BCSE (Md = 3, range 0–9) differed significantly from the MMSE (Md = 1, range 0–9; $z = -3.817$, $p = 0.000$). The subjective tolerability was significantly higher for the BCSE (Md = 9.5, range 5–10) than the MoCA (Md = 9, range 0.5–10; $z = -2.053$, $p = 0.038$). The screening tools were judged as equally appropriate by the patients ($X^2_{(2)} = 0.304$, $p = 0.899$), but the MoCA was significantly more often rated as the screening tool which can “detect actual problems” (32.8 %, $n = 19$), the MMSE was preferred by 5.2 % ($n = 3$), the BCSE by 17.2 % ($n = 10$) ($X^2_{(2)} = 12.063$, $p = 0.003$).

Analysis of validity

The BCSE correlated with the MMSE ($r = 0.475$, $p = 0.000$) and the MoCA ($r = 0.485$, $p = 0.000$). It showed significant correlations with the domains speech ($r = 0.388$, $p = 0.000$), attention and visuo-motor speed

($r = 0.302$, $p = 0.002$), memory ($r = 0.378$, $p = .000$) and executive functions ($r = 0.351$, $p = 0.000$), but no correlation with visual-spatial functions ($r = 0.070$, $p = 0.473$). Detailed results for MoCA and MMSE are displayed in Online Resource 2.

Main analysis: diagnostic properties of BCSE

Distinguishing patients from healthy controls

The MoCA revealed the highest sensitivity, while specificity was higher for MMSE and MoCA. Both tools classified 100 % of the control group as cognitively unimpaired, as compared with 81.8 % according to the BCSE. Best PPV was shown for MMSE and MoCA, best NPV and best diagnostic accuracy (DA) for the MoCA (Table 3). The AUC was highest for MoCA (0.848), but significant differences were only found between MoCA and BCSE.

Table 2 Sample characteristics patient cohort (N = 58)

Variable	n	%
Mean age in years	M = 58.03 (SD = 13.94) range = 27–80	
Sex		
Female	29	50
Male	29	50
Education (highest level)		
Elementary school	26	44.8
Junior high school	17	29.3
University entrance diploma	11	19.0
University degree	3	5.2
No graduation	1	1.7
Current employment status		
Currently employed/in education	37	64.0
Retired	17	29.3
Housekeeper/unemployed	4	6.9
Pre-morbid intellectual level/IQ ^a	M = 110.25 (SD = 10.80) range = 82–137	
Karnofsky Performance Status 0-100 (n = 47)	M = 87.13 (SD = 13.54) range = 50–100	
Previous neurosurgical treatment		
None	47	58.8
First recurrence after initial operation	10	12.5
Second recurrence	1	1.3
WHO grading		
WHO I	15	29.9
WHO II	9	15.5
WHO III	7	12.1
WHO IV	20	34.5
No WHO grading		
Malignant tumor (Metastases)	4	6.9
Benign tumor (Schwannoma)	1	1.7
No histopathological report ^b	2	3.4
Tumor-histological diagnosis		
Meningioma	15	25.9
Astrocytoma	10	17.2
Glioblastoma multiforme	20	34.5
Other	11	19.0
No histopathological report	2	3.4
Tumor-lateralization		
Right	23	39.7
Left	24	41.4
Other (e.g. multiple or medial)	11	19.0
Main tumor-localization		
Frontal	20	34.5
Temporal	11	19.0
Parietal	11	19.0
Occipital	2	3.4
Multiple	8	14.0

Table 2 continued

Variable	n	%
Basal ganglia, cerebellum and adjacent structures	6	10.3

M arithmetic mean; *SD* standard deviation; *WHO* World health organization

^a Estimated via the socio-demographic equation [47, 48]

^b One patient suffered from a meningioma of the falx cerebri (radiological report), but died under the surgery. One patient declined a surgery and was diagnosed with gliomatosis cerebri (radiological report)

Table 3 Diagnostic properties distinguishing patients from healthy controls (manual cut-off)

	AUC	SD	P	Sensitivity	Specificity	PPV	NPV	DA
BCSE	0.699	0.0638	0.0018	38.6	81.82	84.6	34.0	50.6
MoCA	0.848	0.0409	<0.0001	68.97	100	100	55.3	77.5
MMSE	0.826	0.0463	<0.0001	28.07	100	100	33.9	47.4
Comparison of AUC ^o		<i>z</i>	<i>p</i>					
MoCA-BCSE	1.966	.0493*						
MMSE-BCSE	1.611	0.1072						
MMSE-MoCA	-0.356	0.7218						

AUC area under the curve; *BCSE* Brief Cognitive Status Exam; *DA* diagnostic accuracy; *MMSE* Mini Mental State examination; *MoCA* Montreal cognitive assessment; *NPV* negative predictive value; *P* probability; *PPV* positive predictive value; *SD* standard deviation; ^o test statistic: *z* value; * significant with *P* < .05

Distinguishing patients with cognitive decline from unimpaired patients

The full protocol could not be applied to all patients: Priority was given to tests that were most relevant to the preparation and evaluation of the operative procedure, which accounts for fluctuating number of patients per domain (see [1]). 48.1 % (n = 26) of the patients were classified as unimpaired and 51.9 % (n = 28) as impaired in at least one domain (see Online Resource 2).

MoCA showed better sensitivity than MMSE at the respective cut-off scores, indicating higher specificity (Table 4). At the optimal cut-off score, sensitivity was highest for MoCA and specificity was highest for MMSE. Regarding cognitive impairment in the neuropsychological test battery, the AUC for MoCA was highest. A significant difference between two ROC curves was found for MoCA and BCSE.

Discussion

This is the first study comparing the BCSE with the MoCA and the MMSE in terms of feasibility and diagnostic properties in patients with intracranial tumors. With respect to the feasibility of the BCSE in patients with intracranial tumors, we experienced that assessment time of the BCSE was similar to the estimated time provided in the manual and lay between MMSE and MoCA. All screening tools were perceived as hardly straining, highly tolerable and

equally appropriate. The significantly higher strain of BCSE and MoCA in comparison with MMSE probably reflects higher demands on executive functions and memory in both tests. Additionally, the BCSE was rated as more tolerable than the MoCA, which might explain why the MoCA, as the subjectively most difficult tool, was significantly more often judged as the screening tool that could “detect the actual problems”.

As expected, we found medium but significant correlations between the BCSE and the two other screening tools (r = 0.475–0.485). While the BCSE was the only screening that failed to show a significant relationship with visuo-spatial functions, this test showed low significant correlations with all other domains. This can be explained by the lack of the BCSE in assessing visuo-spatial functions. As this is the first study investigating the BCSE in the population of patients with intracranial tumors, our results remain to be replicated in future studies. A detailed discussion of the results of MoCA and MMSE can be found in Online Resource 3.

Distinguishing patients and healthy controls

One of our main goals was to examine the BCSE’s ability to correctly distinguish patients with an intracranial tumor from healthy individuals. It should be kept in mind, however, that the screening tools were not constructed to address this specific issue.

Regarding the specificity of the tools, it should be noted that the control group was correctly classified as

Table 4 Diagnostic properties of cognitive impairment according to neuropsychological test battery

	AUC	SD	P	Manuals cut-off	J	sens	spec	PPV	NPV	DA
BCSE	0.713	0.0747	0.003	PR 15 %		37.0	65.4	52.6	50.0	50.9
MoCA	0.895	0.0412	<0.000	<26	0.503	92.9	61.5	72.2	88.9	77.8
MMSE	0.845	0.0547	<0.000	<26	0.516	44.4	92.3	85.7	61.5	67.9
Comparison of AUC ^o		z	p							
MoCA-BCSE		2.133	0.033*							
MMSE-BCSE		1.426	0.154							
MMSE-MoCA		-0.730	0.47							
				Optimal cut-off						
BCSE				<51/50.5	0.439	59.3	84.6	80.0	66.7	72.7
MoCA				<24/23.5	0.632	78.6	84.6	84.6	78.5	81.5
MMSE				<28/27.5	0.625	74.1	88.5	87.0	76.7	81.1

AUC area under the curve; BCSE Brief Cognitive Status Exam; DA diagnostic accuracy; J Youden's J; MMSE Mini Mental State examination; MoCA Montreal cognitive assessment; NPV negative predictive value; p probability; PPV positive predictive value; PR percentile rank; SD standard deviation; sens sensitivity; spec specificity; ^o test statistic: z value; * significant with $p < .05$

unimpaired with 100 % by MMSE and MoCA. Surprisingly, the BCSE considered four of them as impaired. With respect to the very low specificity in detecting cognitive impairment (see below), we assume that this outcome is a false positive classification. The ability to correctly identify those individuals who have been classified as tumor patients (i.e., the sensitivity) was extremely poor for BCSE (38.6 %), but also for the MMSE with even less sensitivity. The best, but still moderate sensitivity was achieved for the MoCA (68.97 %). Better results were obtained for the probability that the tested person was a patient (i.e., impaired) based upon a positive score (PPV), which was considerably higher for all screenings (BCSE 84.6 %, MoCA 100 %, MMSE 100 %). In contrast, the NPV probability of a valid negative test result (i.e., unimpaired) was very low (≤ 55.3 %). Overall, diagnostic accuracy favored the MoCA. ROC-analysis revealed low AUC for BCSE, while AUCs for MMSE and MoCA were good (0.826 and 0.848). Although no significant differences (only in tendency) were found between the AUCs of MoCA and MMSE, our results suggest that the MoCA seems to be the best alternative in clinical screening situations because it demonstrated the highest sensitivity. However, it should be noted that it still misses one third of ill patients, indicating that it should not serve as the sole criterion for assuming a brain disease and initiating further diagnostic.

Detecting cognitively impaired patients

Our second main goal was to examine the ability of the BCSE to correctly identify those patients who have been classified as cognitively impaired according to the current gold standard of a comprehensive neuropsychological test

battery. When the cut-offs provided by the manuals were used, the BCSE showed extremely low abilities to detect impaired individuals (37 %). The best alternative screening tool was the MoCA (92.9 %). Considering the specificity, the BCSE's ability to detect cognitively unimpaired individuals among patients with an intracranial tumor was moderate but similar to the results of the MoCA (MoCA 61.5 %; BCSE 65.4 %). The best alternative screening for this purpose was the MMSE (92.3 %). Converging results were reported by other authors comparing MMSE and MoCA in different and similar patient populations [18, 19, 26, 49]. For the BCSE, the poor results need to be further explored in future studies.

Finally, prediction of cognitive outcome was worst for the BCSE (AUC = 0.713) compared to the other screening tools. Hence, with respect to the negative predictive value (NPV), results from BCSE were in poor agreement with the neuropsychological test battery as patients with a BCSE score above PR 15 were likely to meet neuropsychological criteria for cognitive impairment after comprehensive evaluation (NPV = 50 %). Conversely, patients classified as impaired by the BCSE (score < PR15) had a probability of 52.6 % to be diagnosed as impaired by the test battery. The best alternative screening tool here again was the MoCA with clearly superior results (NPV = 88.9; PPV = 72.2).

Importantly, examination of different cut-off scores lead to the conclusion that only in case of the BCSE the use of an optimal cut-off increased both sensitivity and specificity, indicating that the use of the stratified norms leads to substantial misclassification of patients with intracranial tumors. Despite this improvement, the values remained far below the diagnostic ability of MMSE and MoCA.

In summary, the BCSE is as feasible as the MoCA or the MMSE in patients with intracranial tumors, but seems to

lack the assessment of visuo-spatial functions. In addition, compared to MoCA and MMSE, it showed the lowest diagnostic qualities in several areas and therefore cannot be recommended as a screening tool for cognitive status in these patients. This also holds true for clinical trials, as our results identified the MoCA as the screening tool with best PPV and NPV and again did not favor the BCSE. Nevertheless, for clinical as well as research settings it should be kept in mind that screening tools usually underestimate the amount of cognitive deficits and the effect of treatment on cognition in comparison with a comprehensive neuropsychological test battery.

Acknowledgments We would like to thank the Familie Mehdorn Stiftung for funding this study. We thank Rajka Matthiesen and Lea Schmitz for the excellent assistance in data acquisition, and Yumiko Nakai for her helpful comments on the manuscript. This manuscript or parts of it have not been published previously and have not been submitted simultaneously for publication in another source.

Funding Juliane Becker and Elisabeth Steinmann were receiving a grant from the Familie Mehdorn Stiftung. None of the other authors received any financial or material support.

Compliance with ethical standards

Disclosure of potential conflicts of interest The authors declare that they have no conflict of interest.

Ethical approval All procedures performed in this study involving human participants were in accordance with the ethical standards of the institutional research committee and with the 1964 Helsinki declaration and its later amendments.

Informed consent Informed consent was obtained from all individual participants included in the study.

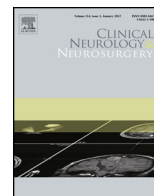
References

1. Talacchi A, Santini B, Savazzi S et al (2011) Cognitive effects of tumour and surgical treatment in glioma patients. *J Neurooncol* 103(3):541–549. doi:10.1007/s11060-010-0417-0
2. Murray KJ, Scott C, Zachariah B et al (2000) Importance of the Mini-Mental Status Examination in the treatment of patients with brain metastases: a report from the radiation therapy oncology group protocol 91-04. *J Radiat Oncol Biol Phys* 48:59–64
3. Meyers CA, Hess KR, Yung WKA et al (2000) Cognitive function as a predictor of survival in patients with recurrent malignant glioma. *J Clin Oncol* 18:646–650
4. Klein M, Heimans JJ, Aaronson NK et al (2002) Effect of radiotherapy and other treatment-related factors on mid-term to long-term cognitive sequelae in low-grade gliomas: a comparative study. *Lancet* 360(9343):1361–1368. doi:10.1016/S0140-6736(02)11398-5
5. Santini B, Talacchi A, Squintani G et al (2012) Cognitive outcome after awake surgery for tumors in language areas. *J Neurooncol* 108(2):319–326. doi:10.1007/s11060-012-0817-4
6. Olson RA, Chhanabhai T, McKenzie M (2008) Feasibility study of the Montreal Cognitive Assessment (MoCA) in patients with brain metastases. *Support Care Cancer* 16(11):1273–1278. doi:10.1007/s00520-008-0431-3
7. Satoer D, Vork J, Visch-Brink E et al (2012) Cognitive functioning early after surgery of gliomas in eloquent areas. *J Neurosurg* 117:831–838
8. Taphoorn MJB, Klein M (2004) Cognitive deficits in adult patients with brain tumours. *Lancet Neurol* 3(3):159–168. doi:10.1016/S1474-4422(04)00680-5
9. Meyers CA, Rock EP, Fine HA (2012) Refining endpoints in brain tumor clinical trials. *J Neurooncol* 108(2):227–230. doi:10.1007/s11060-012-0813-8
10. Zucchella C, Bartolo M, Di Lorenzo C et al (2013) Cognitive impairment in primary brain tumors outpatients: a prospective cross-sectional survey. *J Neurooncol* 112(3):455–460. doi:10.1007/s11060-013-1076-8
11. Bunevicius A, Tamasauskas S, Deltuva V et al (2014) Predictors of health-related quality of life in neurosurgical brain tumor patients: focus on patient-centered perspective. *Acta Neurochir (Wien)* 156(2):367–374. doi:10.1007/s00701-013-1930-7
12. Meyers CA, Brown PD (2006) Role and relevance of neurocognitive assessment in clinical trials of patients with CNS tumors. *J Clin Oncol* 24(8):1305–1309. doi:10.1200/JCO.2005.04.6086
13. Papagno C, Casarotti A, Comi A et al (2012) Measuring clinical outcomes in neuro-oncology. A battery to evaluate low-grade gliomas (LGG). *J Neurooncol* 108(2):269–275. doi:10.1007/s11060-012-0824-5
14. Folstein MF, Folstein SE, McHugh PR (1975) “Mini-Mental State” A practical method for grading the cognitive state of patients for the clinician. *J Psychiatr Res* 12(3):189–198. doi:10.1016/0022-3956(75)90026-6
15. Patel RR, Mehta MP (2007) Targeted therapy for brain metastases: improving the therapeutic ratio. *Clin Cancer Res* 13(6):1675–1683. doi:10.1158/1078-0432.CCR-06-2489
16. Meyers CA, Wefel JS (2003) The use of the Mini-Mental State Examination to assess cognitive functioning in cancer trials: no ifs, ands, buts, or sensitivity. *J Clin Oncol* 21(19):3557–3558
17. Vardy J, Wong K, Yi Q et al (2006) Assessing cognitive function in cancer patients. *Support Care Cancer* 14(11):1111–1118. doi:10.1007/s00520-006-0037-6
18. Olson RA, Iverson GL, Carolan H et al (2011) Prospective comparison of two cognitive screening tests: diagnostic accuracy and correlation with community integration and quality of life. *J Neurooncol* 105:337–344
19. Nasreddine ZS, Phillips NA, Bedirian V et al (2005) The Montreal Cognitive Assessment, MoCA: a brief screening tool for mild cognitive impairment. *J Am Geriatr Soc* 53(4):695–699
20. Chan E, Khan S, Oliver R et al (2014) Underestimation of cognitive impairments by the Montreal Cognitive Assessment (MoCA) in an acute stroke unit population. *J Neurol Sci* 343(1–2):176–179. doi:10.1016/j.jns.2014.05.005
21. Petermann F, Lepach AC (eds) (2012) Wechsler Memory Scale-Fourth Edition (WMS-IV). Manual zur Durchführung und Auswertung. Always learning, 4th edn. Pearson, Frankfurt
22. Bouman Z, Hendriks, Marc PH, Aldenkamp AP et al. (2014) Clinical validation of the WMS-IV-NL brief cognitive status exam (BCSE) in older adults with MCI or dementia. *Int Psychogeriatr*, 1–9, doi: 10.1017/S1041610214001471
23. Olson RA, Iverson GL, Parkinson M, Carolan H, Ellwood A, McKenzie M (2009) Investigation of cognitive screening measures in patients with brain tumors: Diagnostic accuracy and correlation with quality of life.: Meeting Abstract e13000. *J Clin Oncol*, 27
24. Olson RA, Tyldesley S, Carolan H et al (2011) Prospective comparison of the prognostic utility of the Mini Mental State Examination and the Montreal Cognitive Assessment in patients

- with brain metastases. *Support Care Cancer* 19(11):1849–1855. doi:[10.1007/s00520-010-1028-1](https://doi.org/10.1007/s00520-010-1028-1)
25. Gauthier S, Reisberg B, Zaudig M et al (2006) Mild cognitive impairment. *Lancet* 367:1262–1270
 26. Smith T, Gildeh N, Holmes C (2007) The Montreal Cognitive Assessment: validity and utility in a memory clinic setting. *Can J Psychiatry* 52:329–332
 27. Wong GKC, Lam S, Ngai K et al (2012) Evaluation of cognitive impairment by the Montreal Cognitive Assessment in patients with aneurysmal subarachnoid haemorrhage: prevalence, risk factors and correlations with 3 month outcomes. *J Neurol Neurosurg Psychiatry* 83(11):1112–1117. doi:[10.1136/jnnp-2012-302217](https://doi.org/10.1136/jnnp-2012-302217)
 28. Kessler J, Denzler P, Markowitsch HJ (1990) Der mini-mental-status-test. Beltz, Weinheim
 29. Brown PD, Buckner JC, O'Fallon JR et al (2003) Effects of radiotherapy on cognitive function in patients with low-grade glioma measured by the folstein mini-mental state examination. *J Clin Oncol* 21(13):2519–2524. doi:[10.1200/JCO.2003.04.172](https://doi.org/10.1200/JCO.2003.04.172)
 30. Malloy PF, Cummings JL, Coffey CE et al (1997) Cognitive screening instruments in neuropsychiatry: a report of the Committee on Research of the American Neuropsychiatric Association. *J Neuropsychiat Clin Neurosci* 9(2):189–197
 31. Shibamoto Y, Baba F, Oda K et al (2008) Incidence of brain atrophy and decline in Mini-Mental State Examination score after whole-brain radiotherapy in patients with brain metastases: a prospective study. *Int J Radiat Oncol Biol Phys* 72(4):1168–1173
 32. NCCN (2003) Distress management Clinical practice guidelines. *J Natl Compr Cancer Netw* 1(3):344–374
 33. Baldo JV, Schwartz S, Wilkins D et al (2006) Role of frontal versus temporal cortex in verbal fluency as revealed by voxel-based lesion symptom mapping. *J Int Neuropsychol Soc* 12(6):896–900. doi:[10.1017/S1355617706061078](https://doi.org/10.1017/S1355617706061078)
 34. Pihlajamäki M, Tanila H, Hänninen T et al (2000) Verbal fluency activates the left medial temporal lobe: a functional magnetic resonance imaging study. *Ann Neurol* 47(4):470–476. doi:[10.1002/1531-8249\(200004\)47:4<470::AID-ANA10>3.0.CO;2-M](https://doi.org/10.1002/1531-8249(200004)47:4<470::AID-ANA10>3.0.CO;2-M)
 35. Huber W, Poeck K, Weniger D, Willmes K (1983) Aachener Aphasie Test (AAT). Hogrefe, Göttingen
 36. Aschenbrenner A, Tucha O, Lange K (2000) Regensburger Wortflüssigkeits-Test (RWT), Handanweisung. Hogrefe, Göttingen
 37. von Aster M, Neubauer A, Horn R (2006) Wechsler-Intelligenztest für Erwachsene WIE. Manual. Übersetzung und Adaption der WAIS-III von David Wechsler. Hartcourt Test Services, Frankfurt am Main
 38. Tombaugh T (2004) Trail making test A and B: normative data stratified by age and education. *Arch Clin Neuropsychol* 19(2):203–214. doi:[10.1016/S0887-6177\(03\)00039-8](https://doi.org/10.1016/S0887-6177(03)00039-8)
 39. Schaaf A, Kessler J, Grond M, Fink GR (1992) Memo-test manual. Beltz Testgesellschaft, Weinheim
 40. Rey A, Osterrieth PA (1998) Rey-Complex Figur Test (CFT). In: Spreen O, Strauss E (eds) A compendium of neuropsychological tests: administration, norms, and commentary, 2nd edn. Oxford University Press, New York, pp 341–363
 41. Goebel S, Fischer R, Ferstl R et al (2009) Normative data and psychometric properties for qualitative and quantitative scoring criteria of the Five-point Test. *Clin Neuropsychol* 23(4):675–690. doi:[10.1080/13854040802389185](https://doi.org/10.1080/13854040802389185)
 42. Warrington EK, James M. (1992) Testbatterie für visuelle Objekt- und Raumwahrnehmung (VOSP). Burry St Edmunds, Thames Valley Test Company
 43. Vardy J, Tannock I (2007) Cognitive function after chemotherapy in adults with solid tumours. *Crit Rev Oncol/Hematol* 63(3):183–202. doi:[10.1016/j.critrevonc.2007.06.001](https://doi.org/10.1016/j.critrevonc.2007.06.001)
 44. Correa DD, Shi W, Thaler HT et al (2008) Longitudinal cognitive follow-up in low grade gliomas. *J Neurooncol* 86(3):321–327. doi:[10.1007/s11060-007-9474-4](https://doi.org/10.1007/s11060-007-9474-4)
 45. DeLong ER, DeLong DM, Clarke-Pearson DL (1988) Comparing the areas under two or more correlated receiver operating characteristic curves: a nonparametric approach. *Biometrics* 44(3):837. doi:[10.2307/2531595](https://doi.org/10.2307/2531595)
 46. Youden WJ (1950) Index for rating diagnostic tests. *Cancer* 3(1):32–35
 47. Leplow B, Friege L (1998) Eine Sozialformel zur Schätzung der prä-morbiden Intelligenz. *Zeitschrift für Klinische Psychologie* 27: 1–8
 48. Jahn T, Beitlich D, Hepp S et al (2013) Drei Sozialformeln zur Schätzung der (prä-morbiden) Intelligenzquotienten nach Wechsler. *Zeitschrift für Neuropsychologie* 24(1):7–24. doi:[10.1024/1016-264X/a000084](https://doi.org/10.1024/1016-264X/a000084)
 49. Le Rhun E, Delbeuck X, Devos P et al (2009) Troubles cognitifs dans les gliomes de grade II et III de l'adulte: À propos d'une série de 15 patients (Cognitive disorders and adult grade II and III gliomas: analysis of a series of 15 patients). *Neurochirurgie* 55(3):303–308. doi:[10.1016/j.neuchi.2008.08.111](https://doi.org/10.1016/j.neuchi.2008.08.111)

3.2 Publication II - The sensory-motor profile awake - A new tool for pre-, intra-, and postoperative assessment of sensory-motor function

This section presents the second publication (Becker, Jehna, Steinmann et al., 2016). In this publication we sought to develop a standardized diagnostic tool for awake craniotomy and evaluate its feasibility in glioma patients.



The sensory-motor profile awake—A new tool for pre-, intra-, and postoperative assessment of sensory-motor function



Juliane Becker^{a,*}, Margit Jehna^b, Elisabeth Steinmann^a, Hubertus M. Mehdorn^a, Michael Synowitz^a, Gesa Hartwigsen^c

^a Department of Neurosurgery, University Hospital Schleswig–Holstein, Kiel, Schleswig–Holstein, Germany

^b Division of Neuroradiology, Vascular and Interventional Radiology, Department of Radiology, Medical University of Graz, Austria

^c Department of Neuropsychology, Max Planck Institute for Human Cognitive and Brain Sciences, Leipzig, Germany

ARTICLE INFO

Article history:

Received 28 January 2016

Received in revised form 17 May 2016

Accepted 22 May 2016

Available online 24 May 2016

Keywords:

Awake craniotomy

Neuropsychological monitoring

Sensory-motor function

Brain tumor

Non-language mapping

Direct cortical stimulation

ABSTRACT

Objectives: Awake craniotomy is a well-established procedure in surgery of intracranial tumors in eloquent areas. However, sufficiently standardized instruments for the assessment of sensory-motor function before, during and after the operation are currently lacking, despite their importance for evaluation of operative outcome.

Patients and methods: To address this issue, we designed a standardized assessment tool (the “sensory-motor profile awake scale”; SMP-a). The final scale consists of three motor sections (face, arm and leg) assessing both gross and fine motor skills and one sensory section. It differentiates between six grades of impairment and its tasks are applicable for intraoperative continuous monitoring of sensory-motor functions and supporting processes. We analyzed the data of 17 patients with intracranial tumors eligible for awake craniotomy who were preoperatively assessed with the SMP-a. In addition, we present an exemplary case.

Results: Our data support the assumption that the SMP-a is feasible in patients eligible for awake craniotomy, even in patients with symptoms of mild aphasia or more severe sensory-motor deficits caused by tumor recurrence. The exemplary case demonstrates the feasibility of repeated measures with the SMP-a in a tumor patient, including the adaption of tasks to the individual requirements of an intraoperative setting.

Conclusion: This exploratory study suggests that the SMP-a might be a feasible rating scale in patients with intracranial tumors. The flexibility of the scale enables individual adaption, but preserves the standardized scoring system to allow comparison between assessment dates, patients and, hopefully in the future, institutions. However, future studies are mandatory to provide data on the instrument’s diagnostic properties with respect to feasibility, objectivity, validity and reliability.

© 2016 Elsevier B.V. All rights reserved.

1. Introduction

Awake craniotomies are usually considered in patients with intracranial tumors located in or near motor areas to prevent cortical and/or subcortical damage which might lead to permanent neurologic deficits [1–5]. Direct cortical stimulation (DCS)

and mapping supports the surgeon with real-time intraoperative information and this way accounts for individual variability of cortical organization and neuroplastic changes [2,6]. The neurosurgeon must be aware of a wide range of possible intraoperative changes (e.g. slowing of movements, weakness, dysarthria or delayed response) since they guide the decision for resection [7]. A suitable tool for intraoperative monitoring should account for all these changes and support the neurosurgeon with valid and standardized that is, easy-to-interpret information during the operation.

So far, the available literature on awake craniotomy in motor eloquent areas provides either no information on the methods used to monitor endangered functions, or is restricted to the assessment of somatosensory and motor evoked potentials or unstandard-

* Corresponding author at: Department of Neurosurgery, University Hospital Schleswig–Holstein, Arnold–Heller–Straße 3, D–24105 Kiel, Germany.

E-mail addresses: juliane.becker@uksh.de (J. Becker), margit.jehna@medunigraz.at (M. Jehna), elisabeth.steinmann@uksh.de (E. Steinmann), Maximilian.Mehdorn@uksh.de (H.M. Mehdorn), Michael.Synowitz@uksh.de (M. Synowitz), hartwigsen@cbs.mpg.de (G. Hartwigsen).

Table 1
Rating scale for the assessment of complex sensory-motor functions in brain tumor patients undergoing awake craniotomy (sensory-motor profile awake; SMP-a).

SMP-a	□ preoperative □ intraoperative □ postoperative						notes
	severe impairment		medium impairment		no/slight impairment		
face	0	1	2	3	4	5	
frown forehead	0	1	2	3	4	5	
blink eyes	0	1	2	3	4	5	
wrinkle nose	0	1	2	3	4	5	
kissing lips	0	1	2	3	4	5	
laughing mouth	0	1	2	3	4	5	
mouthwash	0	1	2	3	4	5	
poke tongue out	0	1	2	3	4	5	
hand and arm							
hand:							
rock	0	1	2	3	4	5	
fine	0	1	2	3	4	5	
motor	0	1	2	3	4	5	
skills	0	1	2	3	4	5	
paper	0	1	2	3	4	5	
well	0	1	2	3	4	5	
finger tapping (oscillating)	0	1	2	3	4	5	
strength: shake hands	0	1	2	3	4	5	
rotate wrist	0	1	2	3	4	5	
flex elbow	0	1	2	3	4	5	
lift shoulder	0	1	2	3	4	5	
leg							
lift knee slightly	0	1	2	3	4	5	
adduct and abduct foot	0	1	2	3	4	5	
move toes	0	1	2	3	4	5	
strength: press foot against hand (io)	0	1	2	3	4	5	
sensory							
face	0	1	2	3	4	5	
fingers	0	1	2	3	4	5	
arm	0	1	2	3	4	5	
leg	0	1	2	3	4	5	
toes	0	1	2	3	4	5	

(io): first baseline in the operating room.

ized behavioral monitoring [1,8–16]. **Evoked potentials** provide only limited reliability and impairments of non-monitored muscles could not be avoided in previous studies [2,13,17–19]. Another limitation of this technique is that evoked potentials provide no information on the direct effects of the DCS as reflected in continuous voluntary movement during awake craniotomy [2]. The above-cited limitations probably partly result from the fact that sensory-motor function is a complex and integrated process, comprising mobilization itself and several adaptation processes [20–24]. This might explain why registration of simple muscle contractions alone is insufficient for obtaining optimal evaluation [18,25,26]. **Behavioral monitoring** as alternative assessment strategy during DCS might increase the reliability and validity of sensory-motor assessment [25,27–30]. However, previous studies solely applied non-standardized or semi-standardized approaches of instructing their patients. Moreover, it remains unclear, if and how baseline assessment of the patients' functions was done and how the surgery-induced alterations were rated and reported. Therefore, inter-study comparability is hardly existent. In addition, for evaluation of the surgical outcome, previous approaches often assessed very different functions on variable scales compared to the monitored and this way protected functions under surgery [29,30]. Consequently, a valid conclusion on the value of awake craniotomy appears to be difficult at this time.

Hence, a standardization of the monitoring procedure would be mandatory to improve intraoperative assessment of sensory-motor function and provide reliable postsurgical evaluation. However, to the best of our knowledge, no attempts have been made to adapt the existing neurological scales for the application in awake craniotomy so far.

To bridge this gap, we designed a rating scale suitable for this purpose. By this, we aimed at combining the advantages of existing neurological scales used for preoperative and postoperative evalu-

ation in this setting (i.e., the Modified Rankin Scale (mRS) [31], the British Medical Council Research Scale (MCRS) [32,33], the Canadian neurological scale (CNS) [34] and the Graded neurologic scale [35]). Furthermore we tried to overcome the following limitations of the previous scales: (a) *lack of practicability*: mRS, CNS and Graded neurologic scale provide rating sections not suitable for intraoperative setting (e.g., flexion of thighs toward trunk with knees flexed at 90°; activities of daily living: gait), (b) *lack of highly relevant functions*: missing fine motor skills and/or sensory functions in all four scales, (c) *lack of precision in item phrasing or scoring system*: i. e. mixing motor and sensory functions (mRS), vague phrasings in scoring system like “moderate disability, requiring some help” (mRS) or limitation to strength (MCRS) and no qualitative assessment of deceleration or imprecise movements (CNS).

2. Material and methods

The result of our efforts is the “sensory-motor profile awake scale” (SMP-a) as displayed in Table 1. Whenever possible, we adopted suitable items and scoring schedules from existing scales and adapted them for intraoperative settings.

Somatosensory function can be assessed with the SMP-a by touching the face and extremities and recording the respective description of the sensation by the patient. The same holds true for cortical stimulation-elicited dysesthesia reported by the patient (see also 11,19,30). Our standardized scoring system (including an explanation of the grades) is shown in Table 2. It consists of six points covering three steps of impairment. For assessment of strength and sensory function, the numbers follow a continuum similar to the MCRS.

Table 2
Scoring system for assessment of complex sensory-motor functions with the SPM-a.

Grade of functionality	Classification of impairment					
	severe		moderate		slight/no	
	grade 0	grade 1	grade 2	grade 3	grade 4	grade 5
Motor functions	no contraction or muscle movement	trace of contraction visible or palpable, but no movement at the joint	hint towards a purposeful movement visible	uncoordinated execution of a purposeful movement visible	purposeful movement visible, but deceleration or imprecise execution	no deficit, purposeful movement visible, normal strength
Sensory functions	numbness, no sensory function	isolated dysesthesia, but rest numb	more severe dysesthesia, transposed assignment of fingers	dysesthesia	slight dysesthesia	no deficit, normal sensory function

2.1. Recommendation for patient preparation and intraoperative monitoring

In accordance with other authors [36,37], we recommend an **in-depth preparation** of the patient to enhance her/his intraoperative compliance. Special attention should be paid to functions that are highly important for the patient's professional and social life [38]. The total number of tasks during surgery might be decreased if deficits are tolerated or specific functions are not endangered. For a precise baseline assessment, the patient executes the demanded movements after a verbal command with and without visual control and if necessary by imitation (f. e. aphasic patients or non-native speakers). In addition, the patient's report of any changes during the operation is explicitly encouraged [39–41]. In our experience, one should keep in mind that some tasks might be not feasible due to restrictions in the operating theater. For instance, "frown forehead" is often hindered by the Mayfield head holder and local anesthesia and "lift shoulder" might be impossible due to the positioning of the patient. A well-trained examiner can do the whole preparation within 20 min.

Intraoperatively, the baseline-profile or the last noted profile changes enable a fast judgment of any alterations at one glance. The SMP-a is used in our clinic in a surgery mode following the DCS protocol introduced by Duffau et al. for stimulation of cortical as well as subcortical areas without additional measurement of somatosensory or motor evoked potentials (SSEP/MEP) [42]. For mapping purposes the cortical stimulation is done simultaneously with the execution of one task at a time. The intraoperative selection of the tasks for each stimulated site strongly depends on the patient's individual neuroanatomical structure and the tumors relationship to functional areas. For example, during the mapping of areas with specified functions like motor areas of the hand, the assessment can focus only on finger tapping. For areas with negative DCS results, resection can be initiated and a selection of tasks can be performed repeatedly until impairments emerge. Then, again, the monitoring may focus on the altered functions. In accordance with other authors, we prefer a continuous monitoring of the selected tasks during mapping and resection [7,25,27,28,30,43]. To date, intraoperative data acquisition is performed in two ways. The first part of data acquisition focuses on several time points of interest, including pre-stimulation assessment, measurement after change of resection site, before an intraoperative MRI or at the end of the resection. This data can be recorded with different colors or symbols on the SMP-a sheet. As extensive mapping as well as continuous monitoring may generate a lot of information beyond the time points of interest mentioned above, this additional data is currently noted on an extra sheet with exact test time and results. This extra data can be condensed in a postoperative neuropsychological operation report.

Postoperatively, the tasks of the SMP-a can be assessed at different follow-up dates.

2.2. Subjects

We retrospectively analyzed the data of patients eligible for undergoing an awake craniotomy (from 2012 to 2015) at the University Hospital, Kiel. We included patients whose preoperative assessments took place within one to five days before surgery by a neuropsychologist (J. B. and E. S.) with the assessment scale introduced here. Additional data on language ability and medical information was taken from the records. Permission for study participation was routinely obtained from all patients during inpatient stay.

3. Results

3.1. Group analysis

Table 3 displays the subjects' characteristics (n = 17, 9 female). 29.4% of the assessed patients had language impairments: all of these had difficulties in comprehension, four of them in naming objects. 47.1% of our patients underwent an operation due to tumor recurrence. All patients were able to complete the baseline assessment of the SMP-a sufficiently. The results on the preoperative SMP-a baseline are displayed in **Fig. 1**. Preoperatively sensory-motor functions showed no or only slight impairments except for finger tapping with a medium functional impairment.

3.2. Exemplary case

The 40 year old patient was hospitalized with a recurrence of an oligodendroglioma WHO °II in the left central region (see **Fig. 2** part B). A former partial resection under general anesthesia two years earlier had induced a spastic hemiparesis of her right body side that was treated with intensive rehabilitation training.

She was prepared for an awake craniotomy with the SMP-a as displayed in **Fig. 2** on the left side. The assessment revealed considerable deficits in the gross and fine motor functions of the right arm and leg. Additionally, corresponding to functional-anatomical location of the lesions, the patient experienced impairments in sensory functions and reported a lack of "feeling the extremities in the deep". The same assessment without visual control (closed eyes) showed a strong deceleration of the motor functions of the right hand.

Table 3
Sample characteristics (N = 17).

Variable	n	%
Mean age in years	M = 50.7 (SD = 10.87) range = 32–68	
Karnofsky Performance Status 0–100 [52]	M = 76.8 (SD = 10.9) range = 40–100	
Operation due to tumor recurrence		
No	9	52.9
Yes	8	47.1
Tumor-lateralization		
Right	5	29.4
Left	12	70.6
Main tumor-localization		
Frontal lobe	7	41.2
Central sulcus	2	11.8
Temporal lobe	1	5.9
Parietal lobe	6	35.3
Insula	1	5.9
Tumor-histological diagnosis		
Anaplastic Astrocytoma	3	17.6
Glioblastoma	8	47.1
Oligodendroglioma	2	11.8
Diffuse fibrillary Astrocytoma	1	5.9
Anaplastic Oligoastrocytoma	1	5.9
Oligoastrocytoma	1	5.9
Metastases	1	5.9
WHO classification (n = 16)[53]		
Grade 2	4	23.5
Grade 3	4	23.5
Grade 4	8	47.1
Language ability ^a		
Impaired	5	29.4
Naming impaired	4	23.5
Comprehension impaired	5	29.4

^a assessed with the Aachener Aphasia Test (AAT; [54]).

4. Discussion

The existing literature on awake craniotomy provides either no information on the methods used to monitor endangered functions during the operation, or is restricted to the assessment of somatosensory and motor evoked potentials or unstandardized behavioral monitoring [1,8–16]. While mRS, MCSR, CNS and Graded neurological scale were used for evaluation of motor functions before and/or after the operation [17,18,25,27–30,39–41,44–46] none of them seem to be generally suitable for intraoperative assessment. These instruments were originally designed for other clinical cohorts and include impractical tasks like gait. Moreover, they lack important tasks like fine motor skills, mix functional sections and do not provide a sufficient scoring system for qualitative changes in motor functions. With the SMP- a, we aimed to overcome these limitations and combine their benefits like valuable items and a template for the scoring system. To the best of our knowledge, our study represents the first attempt to adapt the existing formal neurological scales for awake craniotomies.

The strengths of the SMP-a are its standardization of the intraoperative tasks and its use in the preoperative phase with an in depth-preparation of the patient and a detailed baseline assessment. This enhances the patient’s intraoperative compliance and ensures valid data to compare intraoperative and postoperative changes. Previous studies frequently reported that tumor-induced impairment of proprioception and/or fine motor skills often allows normal movements under visual control but reveals deficits with closed eyes [47]. Such differences can be assessed with the SMP-a baseline by comparing task performance with and without visual control. Thereby, the possibility of missing preoperative impair-

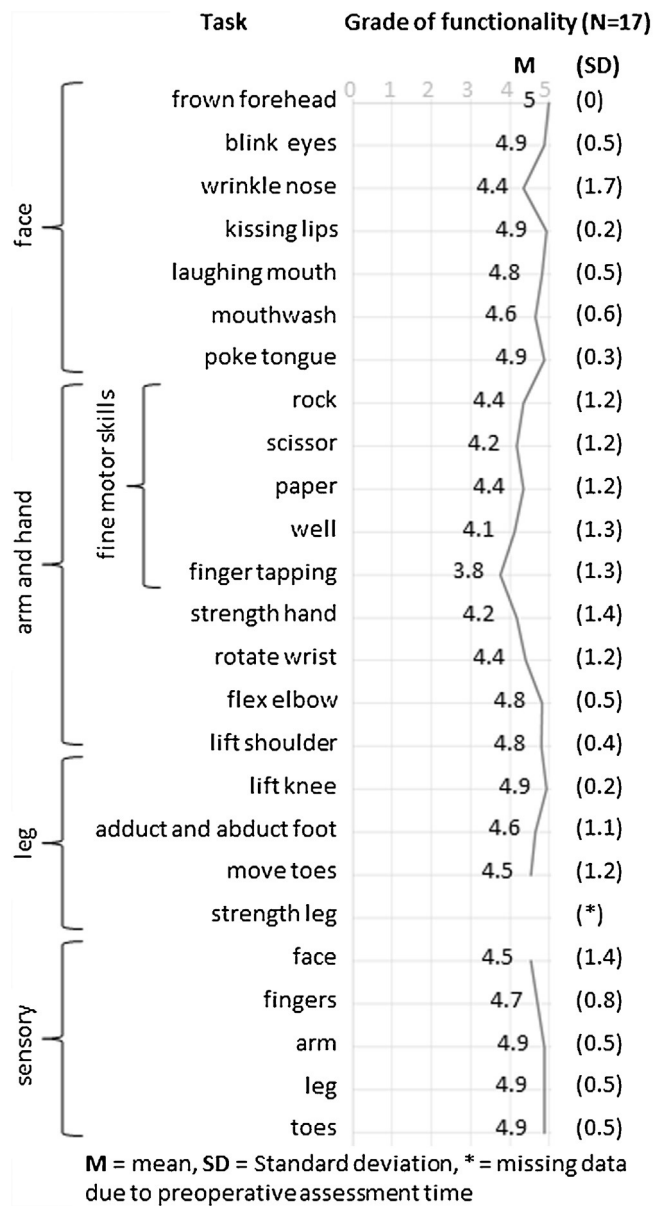


Fig. 1. Grade of functionality measured on the SMP-a for patients eligible for awake craniotomy (0/1 = severe impairment, 2/3 = medium impairment, 4/5 = slight/no impairment; data obtained from 17 patients).

ments might be substantially reduced, which could otherwise easily be mistaken for operation outcomes. Since the SMP-a enables rating of separate functions instead of providing summary scores, it is possible to reduce the intraoperatively used tasks to the individually requirements of the patient’s social and professional life, while still preserving a standardized rating (see also [38,48]). In addition, the tasks are doable with minimum effort and therefore are repeatedly performable. The simple profile character of the data and repetition of the same task during the operation (continuous monitoring) allows to notice any changes like positive and negative effects of DCS as well as short term plasticity [49]. Given that the SMP-a includes all motor tasks reported in the main literature on awake craniotomy [7,25,27,28,30] the neurosurgeon can be confident to probe all functions located along the “human homunculus” of one hemisphere [47,50]. Specific intraoperative events like deceleration or imprecise execution of the motor tasks [7] are represented in the rating scale of the SMP-a. The repeated measure of the same tasks after the operation allows

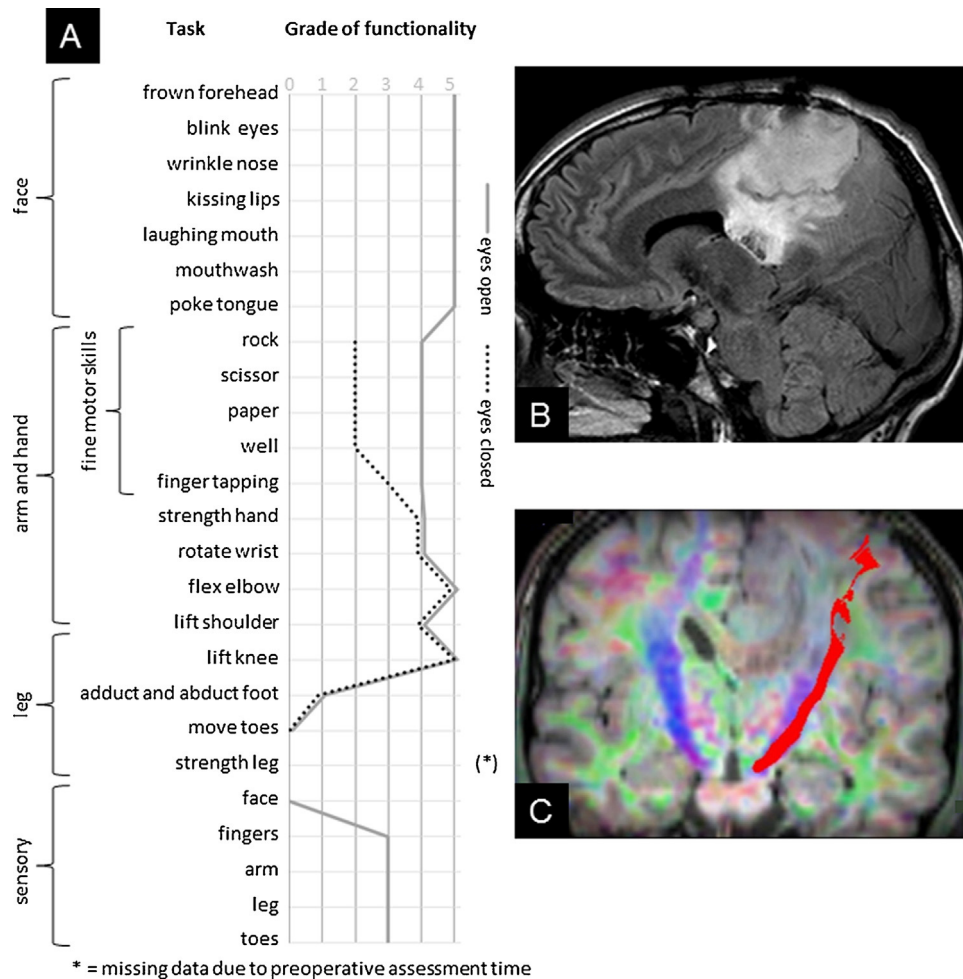


Fig. 2. Exemplary case. (A) Grade of functionality measured on the SMP-a with and without visual control. The assessment revealed a considerable latency for movements requiring an opening of the hand, despite visual control. Additionally, the patient reported numbness of the right side of the forehead as well as a strongly disturbed proprioception of the right sided extremities. Assessment with closed eyes (dotted line) revealed a strong increase in deceleration of fine motor skills (0/1 = severe impairment, 2/3 = medium impairment, 4/5 = slight/no impairment). (B) Preoperative sagittal T2-weighted MRI showing a tumor recurrence in the (post-) central region. (C) Preoperative fiber tracking of the pyramidal tract running in close vicinity to the tumor.

drawing a differentiated picture of the recovery of the intraoperatively monitored functions. By this, a survey of the intraoperative resection decisions and a comparison across patients and institutions becomes possible for the first time.

Our preliminary feasibility analysis shows the successful use of the SMP-a in 17 patients, 8 of them were operated due to tumor recurrence and 5 showed aphasic symptoms. Aphasic symptoms seem to be tolerable for the assessment of motor functions with the SMP-a, as it allows imitation of the tasks in case of comprehension deficits. For sensory functions, these impairments might have greater impact as for rating of these functions a reliable self-disclosure of the patient is necessary. Future studies should evaluate the influence of aphasic symptoms on the SMP-a.

Our preliminary data shows more severe impairments in fine motor tasks especially finger tapping than in facial motor functions or sensory functions in a cohort of patients eligible for awake craniotomy. These exploratory findings need to be reassessed in future studies. The presented exemplary case provides an illustration of the successful implementation of the SMP-a assessment during the inpatient stay in a patient with preoperative impairments. Compared to the neurological examination, the SMP-a baseline assessment revealed additional information useful for the awake craniotomy, i.e., the impact of visual control and proprioception on motor functions." In addition, it shows the applicability of the

SMP-a in a patient with a tumor recurrence and thus more severe impairments as compared to the average awake patient. Future studies should address observations like a possible dissociation of motor function with or without visual control as well as the subjective feeling of weight before hemiparesis becomes apparent [39] as potentially useful information for awake craniotomy.

Although our proposed scale is more structured and comprehensive than the available ones, its ease of use during DCS needs to be evaluated beyond our subjective experience. A first hint that the SMP-a might be suitable for continuous monitoring without causing high exhaustion mimicking paresis is provided by the study of Goebel et al. [51] where monitoring was performed with the tasks of the SMP-a. In addition, a feasibility study carried out by an institution not familiar with this scale would be of great value and might help to improve the SMP-a significantly. Since a very limited number of patients is available for awake craniotomies, we were not able to provide data on objectivity (inter-rater reliability), validity (comparison with other neurological scales) or stability (test-retest reliability) to date. Additionally, the registration of the intraoperative monitoring data beyond specific time points via a pc and its collection in a database would enable further data analysis on relationships between standardized behavioral monitoring and different intraoperative variables like stimulation method (e.g., dif-

ferent electrode arrangements, frequency and amplitude), changes in blood pressure or other assessment methods like SSEP and MEP.

We hope that this preliminary study might encourage other centers to use this scale and provide data for a multi-center evaluation of its quality criteria. Because of the benefits of the SMP-a mentioned above, we are confident that the SMP-a represents a significant improvement as compared to previous techniques used in clinical settings so far. Nevertheless, further studies are necessary to evaluate the clinical relevance of a comprehensive tool like the SMP-a. These studies should test whether the SMP-a could serve the ultimately goal to evaluate outcome in awake craniotomy and compare data between institutions.

Conflicts of interest

None

Acknowledgements

The authors would like to thank an anonymous reviewer for helpful suggestions on the manuscript. We also thank Gesa Cohr, MD, for her support in picture editing. We thank Rauha Laurus, MA, PhD, for her feedback on an earlier version of this manuscript and we thank Christian Panke, PhD, for helpful discussions on this manuscript.

References

- [1] Y.N. Yordanova, S. Moritz-Gasser, H. Duffau, Awake surgery for WHO Grade II gliomas within noneloquent areas in the left dominant hemisphere: toward a supratentorial resection. *Clinical article, J. Neurosurg.* 115 (2011) 232–239.
- [2] H. Duffau, Lessons from brain mapping in surgery for low-grade glioma: insights into associations between tumour and brain plasticity, *Lancet Neurol.* 4 (2005) 476–486.
- [3] A. Talacchi, B. Santini, F. Casagrande, F. Alessandrini, G. Zoccatelli, G.M. Squitani, Awake surgery between art and science. Part I: clinical and operative settings, *Funct. Neurol.* 28 (2013) 205–221.
- [4] K.R. Bulsara, J. Johnson, A.T. Villavicencio, Improvements in brain tumor surgery: the modern history of awake craniotomies, *Neurosurg. Focus* 18 (2005) e5.
- [5] J.G. Ojemann, J.W. Miller, D.L. Silbergeld, Preserved function in brain invaded by tumor, *Neurosurgery* 39 (1996) 253–258 (discussion 258–9).
- [6] N. Sanai, M.S. Berger, Operative techniques for gliomas and the value of extent of resection, *Neurotherapeutics* 6 (2009) 478–486.
- [7] A.G. Chacko, S.G. Thomas, K.S. Babu, R.T. Daniel, G. Chacko, K. Prabhu, V. Cherian, G. Korula, Awake craniotomy and electrophysiological mapping for eloquent area tumours, *Clin. Neurol. Neurosurg.* 115 (2013) 329–334.
- [8] D. Serletis, M. Bernstein, Prospective study of awake craniotomy used routinely and nonselectively for supratentorial tumors, *J. Neurosurg.* 107 (2007) 1–6.
- [9] N. Shinoura, A. Midorikawa, R. Yamada, T. Hana, A. Saito, K. Hiromitsu, C. Itoi, S. Saito, K. Yagi, Awake craniotomy for brain lesions within and near the primary motor area: a retrospective analysis of factors associated with worsened paresis in 102 consecutive patients, *Surg. Neurol. Int.* 4 (2013) 149.
- [10] T. Saito, Y. Muragaki, T. Maruyama, M. Tamura, M. Nitta, Y. Okada, Intraoperative functional mapping and monitoring during glioma surgery, *Neurol. Med. Chirurgical* 55 (2015) 1–13.
- [11] R.A. Danks, L.S. Aglio, L.D. Gugino, P.M. Black, Craniotomy under local anesthesia and monitored conscious sedation for the resection of tumors involving eloquent cortex, *J. Neurooncol.* 49 (2000) 131–139.
- [12] H. Ebel, M. Ebel, G. Schillinger, M. Klimek, J. Sobesky, N. Klug, Surgery of intrinsic cerebral neoplasms in eloquent areas under local anesthesia, *Minim. Invasive Neurosurg.* 43 (2000) 192–196.
- [13] K. Suzuki, T. Mikami, T. Sugino, M. Wanibuchi, S. Miyamoto, N. Hashimoto, N. Mikuni, Discrepancy between voluntary movement and motor-evoked potentials in evaluation of motor function during clipping of anterior circulation aneurysms, *World Neurosurg.* 82 (2014) e739–45.
- [14] M. Attari, S. Salimi, Awake craniotomy for tumor resection, *Adv. Biomed. Res.* 2 (2013) 63.
- [15] D.K. Gupta, P.S. Chandra, B.K. Ojha, B.S. Sharma, A.K. Mahapatra, V.S. Mehta, Awake craniotomy versus surgery under general anesthesia for resection of intrinsic lesions of eloquent cortex—a prospective randomised study, *Clin. Neurol. Neurosurg.* 109 (2007) 335–343.
- [16] P.M. Black, S.F. Ronner, Cortical mapping for defining the limits of tumor resection, *Neurosurgery* 20 (1987) 914–919.
- [17] J. Romstöck, R. Fahlbusch, O. Ganslandt, C. Nimsky, C. Strauss, Localisation of the sensorimotor cortex during surgery for brain tumours: feasibility and waveform patterns of somatosensory evoked potentials, *J. Neurol. Neurosurg. Psychiatr.* 72 (2002) 221–229.
- [18] F.B. Meyer, L.M. Bates, S.J. Goerss, J.A. Friedman, W.L. Windschitl, J.R. Duffy, W.J. Perkins, B.P. O'Neill, Awake craniotomy for aggressive resection of primary gliomas located in eloquent brain, *Mayo Clin. Proc.* 76 (2001) 677–687.
- [19] H. Duffau, New concepts in surgery of WHO grade II gliomas: functional brain mapping, connectionism and plasticity—a review, *J. Neurooncol.* 79 (2006) 77–115.
- [20] H. Duffau, Awake surgery for nonlanguage mapping, *Neurosurgery* 66 (2010) 523–529.
- [21] M. Trepel, *Neuroanatomie: Struktur Und Funktion*, 5th ed., Urban & Fischer in Elsevier, München, 2012.
- [22] G. Lafargue, H. Duffau, Awareness of intending to act following parietal cortex resection, *Neuropsychologia* 46 (2008) 2662–2667.
- [23] H.-J. Freund, The parietal lobe as a sensorimotor interface: a perspective from clinical and neuroimaging data, *Neuroimage* 14 (2001) S142.
- [24] M. Desmurget, A. Sirigu, Conscious motor intention emerges in the inferior parietal lobule, *Curr. Opin. Neurobiol.* 22 (2012) 1004–1011.
- [25] N. Shinoura, R. Yamada, T. Kodama, Y. Suzuki, M. Takahashi, K. Yagi, Preoperative fMRI, tractography and continuous task during awake surgery for maintenance of motor function following surgical resection of metastatic tumor spread to the primary motor area, *Minim. Invasive Neurosurg.* 48 (2005) 85–90.
- [26] N. Shinoura, M. Yoshida, R. Yamada, Y. Tabei, K. Saito, Y. Suzuki, Y. Takayama, K. Yagi, Awake surgery with continuous motor testing for resection of brain tumors in the primary motor area, *J. Clin. Neurosci.* 16 (2009) 188–194.
- [27] M.O. Pinsker, A. Nabavi, H.M. Mehdorn, Neuronavigation and resection of lesions located in eloquent brain areas under local anesthesia and neuropsychological-neurophysiological monitoring, *Minim. Invasive Neurosurg.* 50 (2007) 281–284.
- [28] D. Low, I. Ng, W.-H. Ng, Awake craniotomy under local anaesthesia and monitored conscious sedation for resection of brain tumours in eloquent cortex—outcomes in 20 patients, *Ann. Acad. Med. Singap.* 36 (2007) 326–331.
- [29] H. Duffau, L. Capelle, D. Denvil, N. Sichez, P. Gatignol, L. Taillandier, M. Lopes, M.-C. Mitchell, S. Roche, J.-C. Muller, A. Bitar, J.-P. Sichez, R. van Effenterre, Usefulness of intraoperative electrical subcortical mapping during surgery for low-grade gliomas located within eloquent brain regions: functional results in a consecutive series of 103 patients, *J. Neurosurg.* 98 (2003) 764–778.
- [30] I.R. Whittle, S. Borthwick, N. Haq, Brain dysfunction following 'awake' craniotomy, brain mapping and resection of glioma, *Br. J. Neurosurg.* 17 (2003) 130–137.
- [31] R. Bonita, R. Beaglehole, Recovery of motor function after stroke, *Stroke* 19 (1988) 1497–1500.
- [32] T. Paternostro-Sluga, M. Grim-Stieger, M. Posch, O. Schuhfried, G. Vacariu, C. Mittermaier, C. Bittner, V. Fialka-Moser, Reliability and validity of the Medical Research Council (MRC) scale and a modified scale for testing muscle strength in patients with radial palsy, *J. Rehabil. Med.* 40 (2008) 665–671.
- [33] L.C.M. Pereira, K.M. Oliveira, G.L. L' Abbate, R. Sugai, J.A. Ferreira, L.A. Motta, Outcome of fully awake craniotomy for lesions near the eloquent cortex: analysis of a prospective surgical series of 79 supratentorial primary brain tumors with long follow-up, *Acta Neurochir.* 151 (2009) 1215–1230.
- [34] R. Côté, R.N. Battista, C. Wolfson, J. Boucher, J. Adam, V. Hachinski, The Canadian neurological scale: validation and reliability assessment, *Neurology* 39 (1989) 638–643.
- [35] R.J. Adams, K.J. Meador, K.D. Sethi, J.C. Grotta, D.S. Thomson, Graded neurologic scale for use in acute hemispheric stroke treatment protocols, *Stroke* 18 (1987) 665–669.
- [36] J.-W. Potters, M. Klimek, Awake craniotomy: improving the patient's experience, *Curr. Opin. Anaesthesiol.* (2015).
- [37] A.L. Benabid, Futile circuits in functional neurosurgery, in: H. Duffau (Ed.), *Brain Mapping: From Neural Basis of Cognition to Surgical Applications*, Springer WienNewYork, Vienna, New York, 2011, pp. 389–392.
- [38] A. Fernández Coello, S. Moritz-Gasser, J. Martino, M. Martinoni, R. Matsuda, H. Duffau, Selection of intraoperative tasks for awake mapping based on relationships between tumor location and functional networks, *J. Neurosurg.* 119 (2013) 1380–1394.
- [39] A. Szelényi, L. Bello, H. Duffau, E. Fava, G.C. Feigl, M. Galanda, G. Neuloh, F. Signorelli, F. Sala, Intraoperative electrical stimulation in awake craniotomy: methodological aspects of current practice, *Neurosurg. Focus* 28 (2010) E7.
- [40] M.D. Taylor, M. Bernstein, Awake craniotomy with brain mapping as the routine surgical approach to treating patients with supratentorial intraaxial tumors: a prospective trial of 200 cases, *J. Neurosurg.* 90 (1999) 35–41.
- [41] H.J. Reulen, U.D. Schmid, J. Ilmberger, W. Eisner, K. Bise, Tumorchirurgie im Sprachkortex in Lokalanästhesie. Neuropsychologisches und neurophysiologisches Monitoring während Operationen in der dominanten Hirnhälfte, *Nervenarzt* 68 (1997) 813–824.
- [42] H. Duffau, Awake mapping and tumor surgery, in: H. Duffau (Ed.), *Brain Mapping: From Neural Basis of Cognition to Surgical Applications*, Springer WienNewYork, Vienna, New York, 2011, pp. 305–318.
- [43] H. Duffau, *Brain Mapping: From Neural Basis of Cognition to Surgical Applications*, Springer WienNewYork, Vienna, New York, 2011.

- [44] K. Roessler, M. Donat, R. Lanzenberger, K. Novak, A. Geissler, A. Gartus, A.R. Tahamtan, D. Milakara, T. Czech, M. Barth, E. Knosp, R. Beisteiner, Evaluation of preoperative high magnetic field motor functional MRI (3 Tesla) in glioma patients by navigated electrocortical stimulation and postoperative outcome, *J. Neurol.* 76 (2005) 1152–1157.
- [45] G.E. Keles, D.A. Lundin, K.R. Lamborn, E.F. Chang, G. Ojemann, M.S. Berger, Intraoperative subcortical stimulation mapping for hemispherical periorolandic gliomas located within or adjacent to the descending motor pathways: evaluation of morbidity and assessment of functional outcome in 294 patients, *J. Neurosurg.* 100 (2004) 369–375.
- [46] M.O. Ulu, N. Tanriöver, F. Ozlen, G.Z. Sanus, T. Tanriverdi, C. Ozkara, M. Uzan, Surgical treatment of lesions involving the supplementary motor area: clinical results of 12 patients, *Turk Neurosurg.* 18 (2008) 286–293.
- [47] M.R. Longo, P. Haggard, An implicit body representation underlying human position sense, *Proc. Natl. Acad. Sci. U. S. A.* 107 (2010) 11727–11732.
- [48] A. Talacchi, B. Santini, M. Casartelli, A. Monti, R. Capasso, G. Miceli, Awake surgery between art and science. Part II: language and cognitive mapping, *Funct. Neurol.* 28 (2013) 223–229.
- [49] E. Mandonnet, Intraoperative electrical mapping: advances, limitations and perspectives, in: H. Duffau (Ed.), *Brain Mapping: From Neural Basis of Cognition to Surgical Applications*, Springer WienNewYork, Vienna, New York, 2011, pp. 101–108.
- [50] R.F. Becker, *The cerebral cortex of man*. by wilder penfield and theodore rasmussen. the macmillan company, New York N.Y. 1950. 248 pp, *Am. J. Phys. Anthropol.* 11 (1953) 441–444.
- [51] S. Goebel, A. Nabavi, S. Schubert, H.M. Mehdorn, Patient perception of combined awake brain tumor surgery and intraoperative 1.5-T magnetic resonance imaging, *Neurosurgery* 67 (2010) 594–600.
- [52] V. Crooks, S. Waller, T. Smith, T.J. Hahn, The use of the Karnofsky Performance Scale in determining outcomes and risk in geriatric outpatients, *J. Gerontol.* 46 (1991) M139–44.
- [53] D.N. Louis (Ed.), *WHO Classification of Tumours of the Central Nervous System*, 4th ed., Distributed by WHO Press, World Health Organization Geneva Switzerland, 2007.
- [54] *Aachener aphasia Test (AAT): handanweisung*, Verl. für Psychologie Hogrefe, Göttingen, 1983.

3.3 Publication III - Glioblastoma in Hemihydranencephaly: pre- and postoperative language ability of the right hemisphere

The third publication of this thesis (Becker, Jehna, Larsen et al., 2016) investigated pre- and postoperative basic cognitive and language function in a patient with a congenitally absent left hemisphere and a HGG with the aim to elucidate plastic changes in the reorganized brain

Glioblastoma in hemihydranencephaly: preoperative and postoperative language ability of the right hemisphere

Juliane Becker¹ · Margit Jehna² · Naomi Larsen³ ·
Michael Synowitz¹ · Gesa Hartwigsen⁴

Received: 29 February 2016 / Accepted: 25 April 2016
© Springer-Verlag Wien 2016

Abstract We present the first case report describing a craniotomy for a glioblastoma in a patient with hemihydranencephaly (HHE). Ten years ago our patient had average cognitive and language functions, indicating very good adaption of his single right hemisphere. Due to the tumour he developed a deceleration, deficits in language functions and mild impairments of basic cognitive functions. Further neuroplastic reorganisations of his right hemisphere in response to the tumour growth are discussed. The favourable postoperative outcome supported the decision for careful tumour resection in this patient with HHE.

Keywords Neuropsychological diagnostic · Hemihydranencephaly · Neurosurgery · Brain tumour · Hemisphere agenesis

Electronic supplementary material The online version of this article (doi:10.1007/s00701-016-2825-1) contains supplementary material, which is available to authorised users.

✉ Juliane Becker
juliane.becker@uksh.de

¹ Department of Neurosurgery, University Hospital Schleswig-Holstein, Arnold-Heller-Straße 3, 24105 Kiel, Germany

² Division of Neuroradiology, vascular and interventional Radiology, Department of Radiology, Medical University of Graz, Graz, Austria

³ Department of Radiology and Neuroradiology, University Hospital Schleswig-Holstein, Kiel, Germany

⁴ Department of Neuropsychology, Max Planck Institute for Human Cognitive and Brain Sciences, Leipzig, Germany

Introduction

Hemihydranencephaly (HHE) describes the condition of one brain hemisphere being absent due to prenatal vascular complications. So far, only nine cases have been reported in the literature [10]. The space of the missing hemisphere is filled with a cyst containing cerebrospinal fluid, minimal residual neurons, glial tissue and remaining blood vessels [7]. Central nervous structures fed by the vertebra-basilar blood system like the basal ganglia, pons, medulla, cerebellum, meninges and falx are not affected [10]. Glioblastoma multiforme (GBM) represents a malignant primary brain tumour affecting only about 3 of 100,000 adults per year [3]. The growth of a GBM causes multiple physical and cognitive symptoms and its treatment with surgery is the first line therapy [2]. The case we report is the first illustration of a treatment of a GBM in HHE so far and a follow-up on the probably oldest patient alive with HHE [12].

Case report

The 48-year-old patient with a known history of HHE [12] was diagnosed with a GBM in the right frontal lobe (Fig. 1). The tumour size was about 5.2 × 6.1 cm with cystic and solid portions and surrounded by oedema in the apical direction to the tumour. Despite a considerable deceleration, the patient was awake, oriented and compliant in the neurological examination. He only presented the formerly diagnosed spastic hemiparesis of the right side. The patient complained about a loss of physical strength within the last 4 weeks, but no recent alteration of the hemiparesis. He had to wear varifocal glasses for about

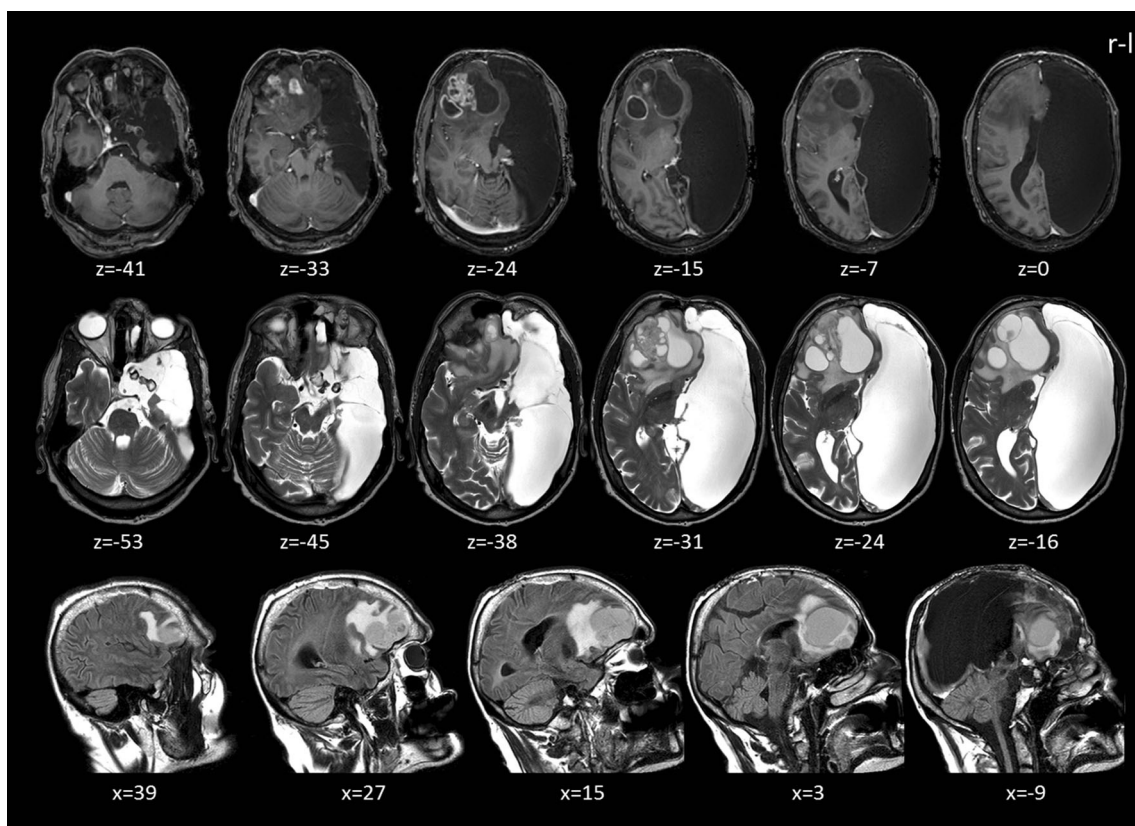


Fig. 1 Preoperative magnetic resonance imaging (MRI) scans in transverse and sagittal views showing the defect of the left hemisphere and the GBM in the right frontal lobe surrounded by oedema (frontal midline shift about 1.7 cm). *Top row:* T1-weighted images (voxel size, $1 \times 1 \times 2$ mm; TR = 7.37 ms; TE = 3.576 ms; field of

view = 224×224 mm², flip angle, 8). *Middle row:* T2-weighted images (voxel size, $0.43 \times 0.43 \times 2.60$ mm; TR = 5,501 ms; TE = 80 ms; field of view = 512×512 mm², flip angle, 90). *Bottom row:* T2-weighted FLAIR images (voxel size, $0.45 \times 0.45 \times 3$ mm; TR = 12,000 ms; TE = 160 ms; field of view = 512×512 mm², flip angle, 90)

4 years. A semi-structured interview for eyesight revealed new impairments of basic and spatial visual functions after approximately 2 years [9].

Functional magnetic resonance imaging (fMRI) of the left foot showed BOLD-signal alterations in areas similar to that observed in healthy subjects (Fig. 2) [11]. However, abnormal activation for foot movement was found near the hand knob in the precentral gyrus. A deterministic tractography reconstructed the pyramidal tracts in distance to the tumour-induced oedema (Fig. 2 middle and bottom rows). The fMRI of language could not be interpreted due to the patient's deceleration.

Preoperative cognitive and language ability

The patient complained of perceived personality changes in the last 7 weeks. Additionally, he reported a decline in memory functions and recently occurring problems in pronunciation for the last 3 months. His pre-morbid cognitive functional level was estimated to be 90 IQ points [6]. A cognitive screening tool, the Montreal Cognitive Assessment (MoCA) [8], revealed an overall result of 17 out of 30 points, indicating

mild cognitive impairment (for details, see Table 1). In summary, the patient showed preoperative impairments in tasks involving executive functions, attention, verbal fluency, abstraction and memory.

In contrast to a previous assessment 10 years previously [12], the standardised diagnostic of aphasia [5] revealed clear symptoms of an aphasic disorder and signs of dysarthria (see Table 2). His spontaneous speech was repeatedly slurred, but showed no neologisms, semantic or phonematic paraphasic errors or repeated speech. In summary, the patient had mild impairments of receptive, expressive and academic verbal skills.

Surgical procedure

The strategy for microsurgical removal of the mass was to minimise frontal lobe alteration and associated risk of neurological deterioration. Therefore, a right-sided supra-orbital approach was chosen. Insufficient compliance of the patient prevented an awake craniotomy. After opening the dura the tumour appeared clearly distinct from the

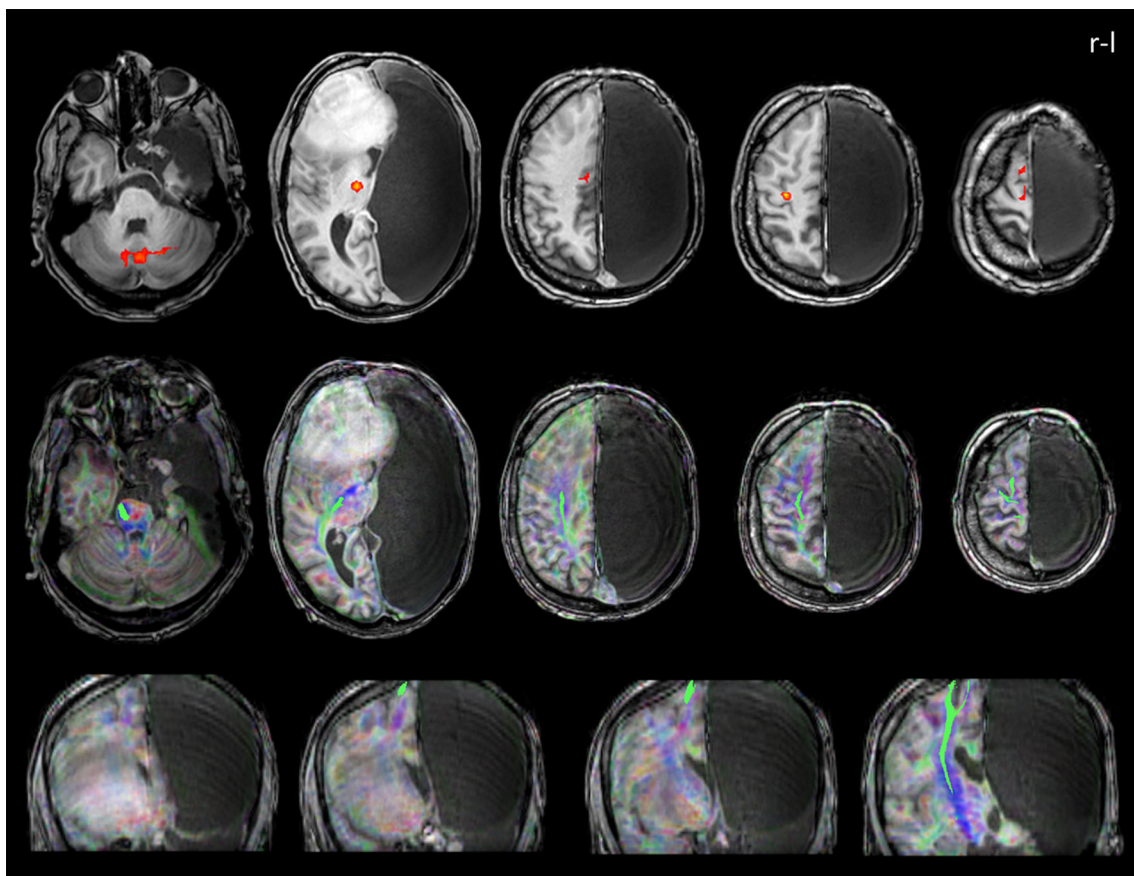


Fig. 2 *Top row:* Functional MRI for movement of the left foot (*t*-test, MC) showing BOLD-signal alterations (*red*) in the cerebellum (bilateral), right thalamus, right anterior cingulate cortex, right precentral gyrus, and the right supplementary motor cortex (block design with six active and six passive conditions, 96 volumes; voxel size, $3.3 \times 3.3 \times 3$ mm; TR = 2,500 ms; TE = 33 ms; field of view = 224×224 mm²; flip angle, 90). *Middle and bottom rows:* Deterministic tractography results from

diffusion-weighted images for the pyramidal tracts (*green*; seed: inferior cerebellar peduncle) in transverse and coronal views (FA-colour-coded MRI registered onto a T1-TFE scan with TR/TE: 7/3.4, $1 \times 1 \times 1$ mm³ voxel size covering 104 slices (field of view, 224×224 ; 32 directions; *b* value = 1,000 s/mm²; 52 slices; voxel size, $2 \times 2 \times 2$ mm, no gap; TR = 5,234 ms; TE = 69 ms; field of view = 512×512 mm²; flip angle, 90)

brain tissue in a grey-bluish (livid) discoloration. The tumour resection proceeded without complications: solid masses were resected completely and all cystic structures were opened. No resection beyond the tumour borders was performed to avoid the high risk of permanent neurological impairment in this patient. There were no intra-operative pictures available.

Postoperative surgical outcome


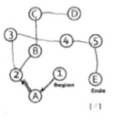


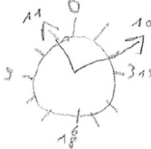

MRI with contrast agent revealed minor contrast enhancements at the margin dorso-laterally to the resection cavity and a bold ring-like enhancement at the right frontal base indicating small residual tumour parts (Fig. 3). Postoperative diffusion tensor imaging (DTI) showed that the pyramidal tracts were passing the rear corona radiate (Fig. 4). The capsula interna as well as the cingulum were visually intact on MRI. The right hemispheric arcuate fasciculus and the

inferior fronto-occipital fasciculus (IFOF) could not be followed to their origin in anterior direction due to oedema. Our Supplementary Material (ESM 1) displays additional probabilistic tractography results of main fibre tracts. Aside from slight subjectively reported postoperative physical weakness (circulatory disturbances, balance), the neurological exam revealed no novel postoperative sensory-motor deficits. The patient reported no alteration of the hemiparesis in comparison to the preoperative impairment and no changes in hearing and vision [9]. In addition, there were no more signs of deceleration.

Postoperative cognitive and language ability

Six days after the resection, the patient no longer reported problems in memory or pronunciation. It also negated changes in the patient's ability to concentrate. With 19

Table 1 Preoperative and postoperative assessment results for basic cognitive functioning with the MoCA [7]

Items	preoperative raw score	postoperative raw score	Δ	max.
Visual-spatial and executive functions				
alternating Trail Making	 0	 0	=	1
visuo-construction (rectangle)	 1	 0	↓	1
clock drawing test	 2	 3	↑	3
Naming	3	2	↓	3
Attention				
digit span	2	2	=	2
vigilance	0	1	↑	1
serial 7s	2	2	=	3
Language				
sentence repetition	0	0	=	2
verbal fluency	0	0	=	1
Abstraction	0	2	↑	2
Memory: Delayed recall				
free recall	0	1	↑	5
cued recall ^a	(0)	(2)		
multiple choice ^a	(1)	(2)		
Orientation	5	5	=	6
wrong item	exact date	day of the week		
Sum Score +1 for education fewer than 12 years	17	19		30

Δ pre-post comparison; max. (achievable) maximum score; ^a not relevant for final sum score

of 30 points, the postoperative MoCA (alternative version 2) [8] still indicated mild cognitive impairment (Table 1). In contrast to the preoperative assessment, the patient was

not able to solve the visual-constructive item. On the contrary, the clock-drawing-task was easily carried out this time. One error was made in the naming task

Table 2 Preoperative and postoperative language functions assessed with the Aachen Aphasia Test (AAT [5])

Subtest of AAT	Preoperative		Postoperative		Δ	max.
	Raw score	Classification ^a	Raw score	Classification ^a		
Token test	35	Impaired	48	Unimpaired	↑	50
Reading	27	Marginal	29	Unimpaired	↑	30
Writing to dictation	28	Unimpaired	30	Unimpaired	↑	30
Naming	106	Impaired	114	Unimpaired	↑	120
Auditory comprehension	43	Impaired	41	Impaired	↓	60
Reading comprehension	49	Impaired	47	Impaired	↓	60

Δ pre-post comparison, max. (achievable) maximum score

^a In comparison to other aphasic patients according to the manual of the AAT

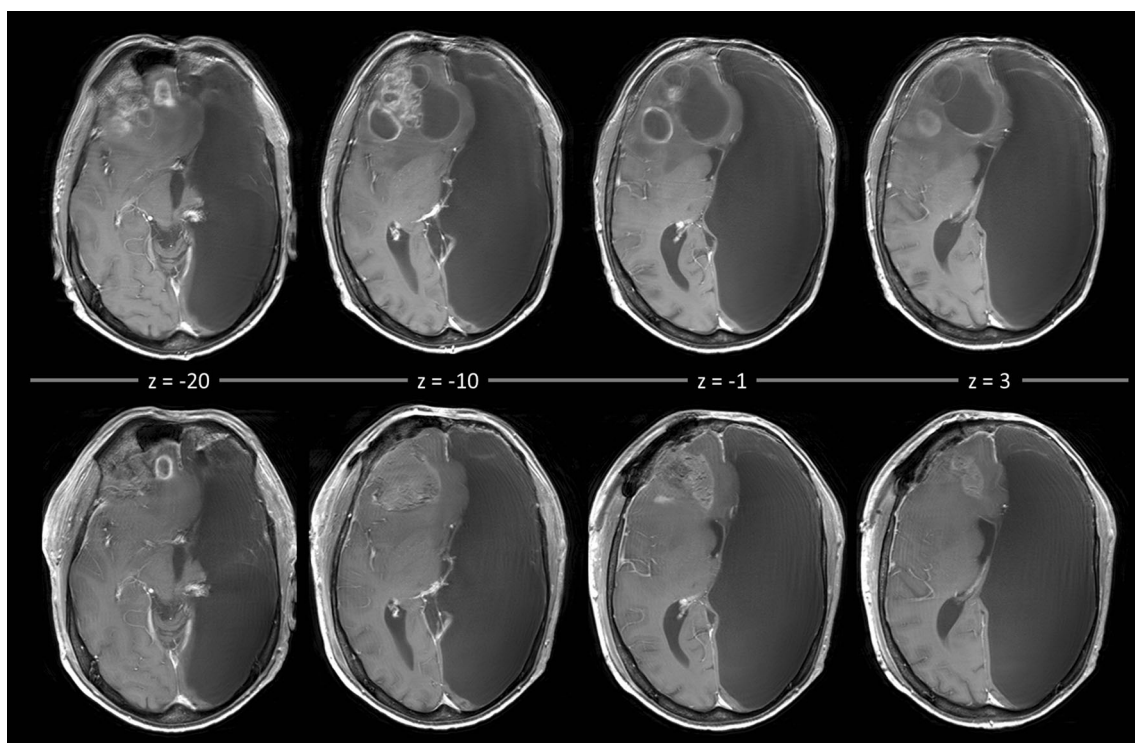


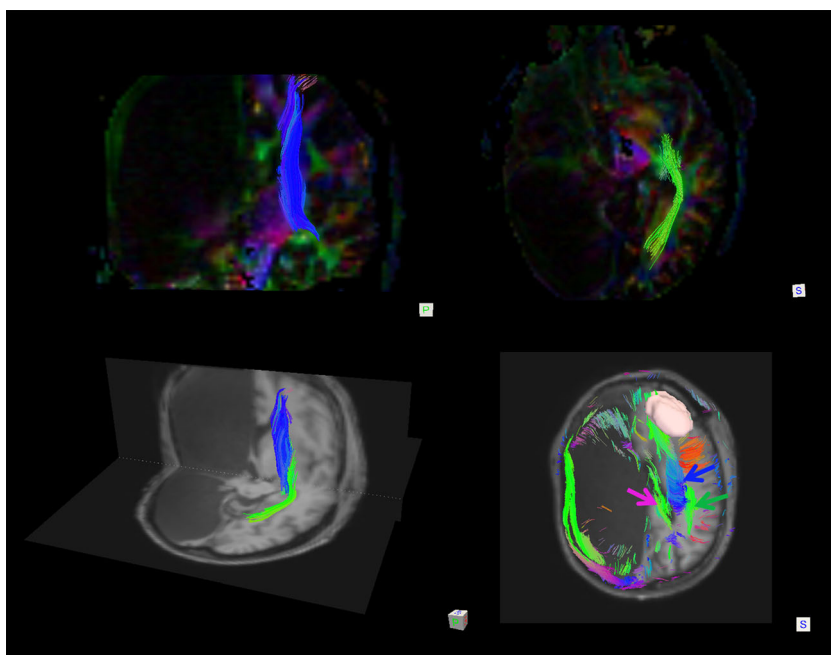
Fig. 3 Comparison of preoperative and postoperative MRI scans *Top row*: Preoperative T1-weighted MRI with contrast agents (voxel size, $0.43 \times 0.43 \times 5$). *Bottom row*: Postoperative T1-weighted MRI with contrast agents (voxel size, $0.43 \times 0.43 \times 5$) 1 day after the operation

displaying the slightly regressive midline shift. The resection cavity exhibited hemorrhagic areas, was partially filled with fluid and showed slight infarctions at the cavity margins (not displayed here)

postoperatively. In contrast to the preoperative results, the patient was able to solve the vigilance item correctly, indicating clear improvement of the deceleration. In addition, he showed better performance on the assessment of abstraction and memory. Moreover, the patient exhibited

no more symptoms of dysarthria (spontaneous speech was no longer slurred and no new aphasic symptoms occurred). Improvements in expressive and academic verbal skills occurred. Mild impairments of receptive language were still present (Table 2).

Fig. 4 Postoperative deterministic tractography. *Top row*: Pyramidal tract (blue, coronal view) and inferior fronto-occipital fasciculus (IFOF) (green, transverse view) displayed on the background of the colour-coded FA map and selected by slice filtering. *Bottom row, left*: Display of pyramidal tracts (blue) and IFOF (green) (selected by slice filtering) in coronal and transverse view from posterior view from posterior overlaid on a T1-weighted MRI scan registered to the DTI native space. *Bottom row, right*: Reconstruction of the tumour volume (rosy), the cingulum (pink), pyramidal tracts (blue) and the right hemispheric arcuate fasciculus (green). The tracts were selected by slice filtering and are marked by arrows



Immediately after the patient's release, radio-chemotherapy according to the Stupp regimen was started [11]. The treatment is not yet completed, but to date well tolerated by the patient without major changes in cognitive or physical status.

Discussion

Here, we present the first report of a craniotomy of a right frontal GBM in a patient with HHE. Despite the high risk of causing permanent neurological deficits during an intracranial tumour resection in HHE, this case documents an almost complete tumour resection with a good outcome regarding language and basic cognitive functions. In contrast to the patient's normal cognitive functionality 10 years earlier [12], he presented preoperatively with a severe deceleration, mild impairments in basic cognitive functions (memory, attention, executive functions) and mild impairments in receptive, expressive and academic verbal skills. One might speculate that these new symptoms were tumour induced. The deceleration vanished after tumour resection and some basic cognitive functions including language functions improved. No severe cognitive deficits emerged postoperatively.

Cognitive performance in HHE is generally judged as relatively normal, independent of which hemisphere is affected [1, 10]. This is explained by the fact that already in utero, no corresponding hemisphere is present for a longer time period and the full "functional potential of a single cerebral hemisphere" might be able to develop [4, 10]. HHE can be considered as the earliest time point for a cerebral lesion inducing neuroplastic changes, which likely differ from the observed reorganisations in patients with hemispherectomy [10] or patients with intracranial tumours. To date, however, it remains unclear whether patients with HHE show further plastic changes after additional lesions and how much adaptation can be achieved by one hemisphere. It may be speculated for the reported case that after prenatal insult, formerly left hemispheric functions were successfully organised in the intact right hemisphere, which might explain his relatively normal cognitive ability 10 years ago. This is supported by the respective fMRI and tractography results of our case, indicating nearly normal functional areas and courses of assessed tracts in comparison to healthy subjects. The later tumour growth might have induced additional neuronal reorganisation in this patient. The formerly good adaptation to the missing hemisphere could have provided capacity for additional plasticity. This might explain the relatively mild cognitive and language impairments before and after the operation. The divergent BOLD signal for the fMRI of the left leg near the hand knob might be regarded as one indication for a divergent functional-neuroanatomical proportion.

In general, in case of a missing hemisphere, it can be speculated that this reduces the brain's ability to compensate for tumour and treatment-induced cognitive deficits compared to patients without HHE. In addition, we might observe unique functional-anatomical relationships which have been formed during early development and were modulated later by additional occurrence of a GBM. This draws special attention to a good balance between a conservative resection and maximal tumour resection. The operative outcome of our case suggests that even if only one hemisphere is functioning, a careful tumour resection can be performed.

Conclusions

Although neurosurgical extirpation of an intracranial tumour in a patient with HHE has a high risk for permanent neurological impairments, this case report documents an almost complete tumour resection (frontal lobe) with a good outcome regarding language and basic cognitive functions. The results of our case study support the assumption of a strong potential for adaptive plasticity in the human brain. Specifically, our results suggest that even in the absence of the entire left hemisphere, the right hemisphere was able to develop language functions and reorganise them after occurrence of a GBM.

Acknowledgments We would like to thank Thomas Lindner, MSc, for his help in data acquisition and Christian Panke, PhD, for his helpful comments on the draft of this manuscript.

Compliance with ethical standards All procedures performed in this study were in accordance with the ethical standards of the institutional and/or national research committee and with the 1964 Helsinki declaration and its later amendments or comparable ethical standards.

Conflicts of interest The authors declare that they have no conflicts of interest.

Patient consent The patient gave written informed consent for publication of his data.

Funding No funding was received for this research.

References

1. Altschuler EL, Matsumura B, Capoor J, Weinschelbaum K, Ghuznavi H (2005) Left-hemispheric hydranencephaly with less favorable findings. *Pediatrics* 116(6):1603–1604, author reply 1604
2. Duffau H (2011) Brain mapping. From neural basis of cognition to surgical applications. Springer, Vienna
3. Gallego O (2015) Nonsurgical treatment of recurrent glioblastoma. *Curr Oncol* 22(4):e273–e281 (Toronto, Ont)

4. Hassanein SMA, Abbas YA, Monib AM, Alfay E, Mohsen S (2011) Hemihydranencephaly syndrome: case report and review. *Dev Neurorehabil* 14(5):323–329
5. Huber W, Poeck K, Weniger D, Willmes K (1983) Aachener Aphasie Test (AAT). Hogrefe, Göttingen
6. Jahn T, Beitlich D, Hepp S, Knecht R, Köhler K, Ortner C, Sperger E, Kerkhoff G (2013) Drei Sozialformeln zur Schätzung der (prä-morbiden) Intelligenzquotienten nach Wechsler. *Z Neuropsychol* 24(1):7–24
7. Mori K (1985) Anomalies of the central nervous system. *Neuroradiology and neurosurgery. Neuroradiological atlases.* Thieme-Stratton, New York
8. Nasreddine ZS, Phillips N, Chertkow H, Rossetti H, Lacritz L, Cullum M, Weiner M (2012) Normative data for the Montreal cognitive assessment (MoCA) in a population-based sample. *Neurology* 78(10):765–766
9. Niedeggen M, Jörgens S (2005) Visuelle Wahrnehmungsstörungen. *Fortschritte der Neuropsychologie*, Bd. 5. Hogrefe, Göttingen
10. Pavone P, Nigro F, Falsaperla R, Greco F, Ruggieri M, Rizzo R, Praticò AD, Pavone L (2013) Hemihydranencephaly: living with half brain dysfunction. *Ital J Pediatr* 39:3
11. Schneider F, Fink GR (2007) Funktionelle MRT in psychiatrie und neurologie. Springer, Heidelberg
12. Ulmer S, Moeller F, Brockmann MA, Kuhtz-Buschbeck JP, Stephani U, Jansen O (2005) Living a normal life with the nondominant hemisphere: magnetic resonance imaging findings and clinical outcome for a patient with left-hemispheric hydranencephaly. *Pediatrics* 116(1):242–245

4 GENERAL DISCUSSION AND CONCLUSIONS

4.1 Cognitive screening in patients with intracranial tumors: A vote for a comprehensive neuropsychological assessment

Many neurosurgical acute hospitals cannot afford a comprehensive neuropsychological diagnostic for all their patients with intracranial tumors. The same is true for clinical research trials which utilize cognitive status as an outcome measure for treatment or side effects (Bunevicius et al., 2014; Meyers & Brown, 2006; Meyers, Rock, & Fine, 2012; Taphoorn & Klein, 2004). Therefore, cognitive status diagnostic is performed by screening tools such as MMSE and MoCA. However, one major drawback is their lack of sensitivity for cognitive domains often impaired in patients with brain tumors. This particularly concerns executive functions in case of the MMSE and a low overall specificity in case of the MoCA. Most important, both tests have a tendency to miss 10-20% of impaired patients (Olson, Tyldesley et al., 2011). Despite their limitations, they are frequently used since alternatives are lacking to date.

The goal of the first study (Becker, Steinmann et al., 2016) was to test whether the novel screening tool BCSE is a valid and diagnostically more accurate alternative compared to the established instruments MoCA and MMSE in patients with intracranial tumors. Despite comparable feasibility of the BCSE and the MoCA or MMSE and a sufficient convergent validity, we had to conclude that BCSE was no alternative for the established screening tools. We assessed the patient's cognitive status with the three screening tools in a mixed group of healthy subjects and patients with intracranial tumors verified by MRI. Our results clearly document the lack of the BCSE to distinguish between healthy and ill subjects. We also compared the results of the cognitive screening tools with the results of a comprehensive test battery in the patient group. Among the three screening tools the BCSE showed the lowest concordance with the results of the test battery. Specifically, our results showed that the MoCA was the most suitable screening tool for clinical diagnostic in our population of patients with intracranial tumors compared to MMSE and BCSE. However, a comprehensive test battery is still superior in terms of sensitivity and specificity.

Sensitivity is influenced by the characteristics of the test population (Kraemer, 1992). One could argue that the BCSE was not designed for the application in tumor patients and therefore only reached a low sensitivity in our study. However, such limitations are not

specified in the test manual by the authors. It should be noted that some of the healthy subjects were classified as impaired by the BCSE in our sample, which is particularly critical. This misclassification might have resulted from a particularly high sensitivity to detect cognitive impairment. However, this explanation is not congruent with the results from the comparison to the test batterie in our patients. Here, the BCSE generally failed to accurately detect cognitive impairment, in particular those related to visuo-spatial functions. It thus remains unclear why the BCSE showed such low categorization accuracy in healthy participants. In neuro-oncology, sufficient sensitivity to detect minor cognitive deteriorations, which often occur in follow-up test situations, is important (Giovagnoli, 2012). Additional comparative studies are necessary to verify our findings and further investigate the BCSE's diagnostic characteristic also in different patient populations.

For clinical purposes, high **sensitivity and specificity** in a screening tool would be preferable. Unfortunately **optimizing both** at the same time is impossible. A false positive (i.e. impaired cognitive status) classification would lead to unnecessary rehabilitative treatment or comprehensive testing that might reveal the false classification. In contrast, a false negative (i.e. unimpaired cognitive status) classification would lead to a missed chance of rehabilitation. Both types of errors are not favorable within the clinical context. Cognitive and physical functioning are valid predictors of quality of life (Bunevicius et al., 2014; Zucchella, Bartolo, Di Lorenzo, Villani, & Pace, 2013). Furthermore, reintegration in everyday life can palliate the already high burden of the disease and prevent depression (Bunevicius et al., 2014; Ford, Catt, Chalmers, & Fallowfield, 2012; Zucchella, Bartolo et al., 2013). Thus, at first place, the main goal in (awake) craniotomy is preservation of cerebral functions and at second place the subsequent rehabilitation (Duffau, 2010; Habets et al., 2014; Satoer, Visch-Brink, Dirven, & Vincent, 2016). Therefore, our results are congruent with the recommendation to use a comprehensive test battery whenever possible (Klein et al., 2001, 2001; Olson, Iverson et al., 2011).

A further disadvantage of screening tools is their lack to **address the relevant diagnostic questions** in detail. This concerns in particular preoperative diagnostic in awake surgery. An elaborate behavioral observation provides valuable information to estimate the patient's intraoperative compliance. Additionally, on basis of the cognitive profile, intraoperative tasks are selected and **medical decisions** such as eligibility for awake surgery or further

rehabilitation are made. All these decision steps are of high importance for the patient and should be based on valid diagnostic, which can be achieved only to a limited degree when screening tools are applied. The above outlined consequences following a cognitive status diagnostic underline the **importance** of a high **diagnostic quality**. One important conclusion from our results is that a high quality in terms of validity, sensitivity and specificity can only be achieved with a test battery so far. The exclusive use of a screening tool can only be justified in patients who show exhaustion, severe deceleration or decline the participation in a comprehensive test battery. Here, the use of an established screening tool such as the MoCA is recommended.

In **research trials** the MMSE is often used for repeated cognitive measurements of treatment or side effects. The results of our study demonstrated a substantial lack in detecting cognitive decline in patients with intracranial tumors by the MMSE, which is in line with other studies (Le Rhun, Delbeuck, Devos, Pasquier, & Dubois, 2009; Olson, Iverson et al., 2011). Accordingly, our results strongly support the replacement of MMSE by MoCA in clinical trials involving patients with intracranial tumors. With respect to the already reduced life expectancy and impaired health in many patients, it is mandatory to carefully investigate any further negative impact. This includes the recommendation to avoid new treatments with negative side effects, if their use is not justified by beneficial treatment effects. Due to this, one could argue that it is not justified to simply trust screening tools in this context. As a compromise in a setting with high time and cost restrictions, one could reduce a comprehensive cognitive test battery to the most important tools, as we tried in our study and also suggested by Lageman and colleagues (2010). These authors explicitly sought to reduce a cognitive test battery (containing standardized neurocognitive tests with a widely used format) for research purposes in their study and reported that the assessment of the domains of visuo-construction, processing speed, and verbal memory could capture 90% of all impaired patients. This approach could improve the results of clinical trials in patients with intracranial tumors and prevent risks and side effects on cognitive functions by treatment methods such as radiation or new chemotherapeutic agents. For further research, it is mandatory to include the patient's perspective and expectations on cognitive assessment. This means that beside the careful selection of cognitive tests for a reduced test battery, the ecological validity of the results needs to be assessed. Following this, it is mandatory to ask the patients about their subjective cognitive impairments and their impact

on everyday life to identify the most severe subjective restraints. The primary goal should be the selective inclusion of tests exhibiting a high ecological validity and functions that are highly relevant from the patient's subjective perspective.

Beside a qualitatively high status diagnostic regarding cognitive functioning, a respective assessment of sensory-motor functions for awake craniotomy is mandatory. Such a scale for pre-, intra- and postoperative assessment was established for sensory-motor functions in our second study (Becker, Jehna, Steinmann et al., 2016).

4.2 Assessment of sensory-motor function in awake craniotomy

Awake craniotomies require coordinated teamwork of a multi-professional team consisting of neurosurgeons, anesthesiologists, neuroradiologists and neuropsychologists (Talacchi, Santini, Casagrande et al., 2013). A substantial part of the surgical success, i.e. avoiding permanent postoperative deficits, relies on the intraoperative diagnostic performed by the neuropsychologist. As outlined in the second study (Becker, Jehna, Steinmann et al., 2016), no standardized tool for intraoperative diagnostic of sensory-motor function was available so far. Due to this circumstance, we designed such a tool and investigated its feasibility. Awake craniotomy exhibits difficult requirements such as i) high flexibility in task composition, ii) task restrictions due to the operation scenario, iii) very short time slots for each single task during DCS and iv) an extensive repetition rate of the tasks. To the best of our knowledge, our study introduced the first experimental design of a standardized tool for awake mapping and monitoring of sensory-motor functions which fulfills all these requirements. Further, our results demonstrate the feasibility to **implement** this tool for individually tailored diagnostic in a clinical routine for patients available for awake craniotomy.

Based on these promising results, additional studies with the SMP-a in larger patient samples are planned to investigate its psychometric properties. Due to the thorough design, the SMP-a meets all basic criteria for **implementation objectivity**. Yet, the **evaluation objectivity** in terms of interrater concordance needs to be determined. Its clear definition and examples for the different rating categories should lead to a high interrater reliability; nonetheless the results might encourage a revision of rating examples. To provide a valid evaluation of the SMP-a's **interpretation objectivity**, future studies on healthy subjects are

mandatory. For this population, we would expect no impairments and maximum grade of functionality for each task. Further, comparison of healthy subjects and patients should, for instance, reveal a significant lower functionality in patients with HGG.

Of note, our study provided the first detailed **characterization of the patient population** for awake craniotomy in terms of sensory-motor function: These patients showed high sensory-motor functionality except in fine motor tasks, where medium impairments were determined. The mean KPS score of 76.8 in our study group corresponds with the inclusion criterion of KPS >70% for awake craniotomy recommended by Santini and colleagues (2012). Five out of 17 patients (29.4%) in our study were finally excluded from awake surgery. The mean KPS of the excluded patients was 72 (SD=21.68) and did not differ significantly from the group which finally underwent awake surgery (Mann-Whitney-Test, $U=25.5$, $p=.63$; unpublished data). According to the criteria of Santini and colleagues (2012), we hypothesized that a group with KPS <70 (relative to the group of KPS >70) would show stronger impairments in the SMP-a. In an explorative analysis, we compared the six patients with a KPS <70 to the 11 patients with a KPS >70. The former group showed significant lower functionality in the following SMP-a tasks: rock ($U=10.5$, $p=.009$); paper ($U=10.5$, $p=.009$); finger tapping ($U=14.0$, $p=.037$), rotate wrist ($U=16.0$, $p=.042$), adduct foot ($U=22.0$, $p=.048$) and sensory face ($U=22.0$, $p=.048$). Further studies should test if these results (convergent impairment in KPS and SMP-a) are of relevance for inclusion of patients into awake surgery. In particular, it is necessary to investigate whether the exclusion criteria of KPS <70 and impairments in the SMP-a predict intraoperative compliance and functional results. Contrariwise, a range of the KPS between 40 and 100 in our study indicates that patients with lower physical functionality (KPS <70) were able to undergo assessment with the SMP-a and were also eligible for awake surgery. The KPS is considered as an adequate measure of physical performance (Cheng, Zhang, & Liu, 2009) and widely used as outcome measure, although limitations in reliability and validity are reported (Talacchi, d'Avella et al., 2012). However, its predictive value as successful inclusion criteria for awake surgery might be limited. Instead, the KPS should be considered as an indicator for inclusion, but not as a sole criterion. Other, more specific factors such as cognitive functionality including language ability, specific sensory-motor abilities and psychological eligibility might also have high predictive values. In a second explorative study, we compared the SMP-a profiles of the five excluded patients with that of the included patients. We hypothesized that the excluded

patients would exhibit more severe impairments in the SMP-a. Indeed, excluded patients showed significantly more severe impairments in the following SMP-a tasks: laughing mouth (U=18.0, p=.024), rotate wrist (U=10.0, P=.012), lift shoulder (U=3.5, p=.022) and adduct foot (U=18.0, p=.024). It needs to be determined in future studies whether these tasks are predictors for a successful inclusion into awake surgery. The same is true for the SMP-a's predictive value for intraoperative compliance and operation outcome. Further research is necessary to investigate the differences of included patients in comparison to rejected patients, with the ultimate goal to **establish guidelines** for inclusion and exclusion criteria for awake craniotomy in gliomas.

Future studies for evaluation of the SMP-a's **convergent and divergent validity** are planned. Validation criteria including routine medical measures for physical health such as KPS, but also a general neurological examination could reveal information on the SMP-a's ability to assess similar and complementary information. Moderate to high relationships are expected with neurological rating scales for motor function such as mRS, MCSR, CNS and Graded neurological scale. Moderately high relationships are expected since some items of the SMP-a were adapted from the other scales. The results of the exemplary case documented in publication two indicate an **advantage** of the SMP-a over the classical **neurological examination**. For instance, symptoms of disturbed proprioception are easily missed in the neurological examination but are explicitly assessed in the sensory section of the SMP-a. Additional research is planned to compare the results of a standardized neurological examination and the SMP-a to specify the possible advantages of the SMP-a.

Pre-, intra- and postoperative comparison of sensory-motor assessment in awake craniotomy

Talacchi and colleagues (2013) summarized the **empirical research in awake** craniotomy as follows: "Quality of evidence for the benefits of mapping is scarce (mostly evidence class II, some evidence class III studies) and mainly based on historical control studies, retrospective analyses and expert opinion." (p. 216). Their call for a clear terminology and consistency between pre-, intra- and post-operative testing for language tasks can be generalized to sensory-motor tasks. As one of the basic evaluation principles, the **evaluation method for**

the operative outcome should match the preoperative baseline assessment, otherwise information useful for prognosis and interpretation of clinical result is lost (Talacchi, Santini, Casagrande et al., 2013). With the SMP-a, we provided a tool for pre-, intra- and postoperative testing. Nevertheless, for repeated measurement, the **stability** of the results obtained with the SMP-a (i.e. **retest-reliability**) needs to be investigated. Based on our clinical experience, we would expect higher fluctuation of functionality in patients with gliomas due to the nature of the disease, including seizures, edema and tumor progression as responsible factors for functional decline. Further, we would expect a higher retest-reliability for shorter test-retest time spans in this population. For clear estimation on the true retest-reliability, which accounts only for the measurement error of the SMP-a and not for confounding variables of the disease, future studies should be performed in patients with a more stable disease such as stroke patients.

Despite an agreement on the inclusion of **tumor-related outcome criteria** as main goal in clinical trials, the main focus across the last decades was on medical variables such as disease progression and response to radio- or chemotherapy (Shields & Choucair, 2014). Improved survival time due to maximum resection may have been achieved at the cost of persistent long-term impairments in patients (Talacchi, Taphoorn, & Miceli, 2012). **Little is known** about the patient's functional status (physical, cognitive, psychological) and **health-related quality of life after treatment** (Talacchi, Taphoorn et al., 2012). With the SMP-a, we sought to provide an easy tool for long-term evaluation of the relationship of these factors. Future study goals should include the connection of medical data such as progression free survival and SMP-a data with the patients' perspective towards a "**patient-related outcome**" (see also Talacchi, Taphoorn et al., 2012). Specifically, the evaluation of so called "planned deficits", needs to be addressed, i.e. if they are transient or persistent. This aspect was outlined as "one of the major challenge in the following years" by Talacchi and colleagues (2012).

Nowadays, **different clinical institutions** use different instructions, different items and different rating scales for awake craniotomy in sensory-motor eloquent areas. With the SMP-a, we also aimed at designing a tool suitable for different institutions. To investigate the SMP-a's ability to be reliably implemented in different institutions, investigations of its **interrater reliability** between different institutions are necessary (beside analysis of

feasibility). For evaluation of the SMP-a's interrater-reliability, different professional backgrounds of the user involved in the assessment of sensory-motor function in awake craniotomy have to be considered. Neuropsychologists, medical doctors, clinical linguists and neurophysiologists show different experience levels at rating scales and sensory-motor assessment. Knowledge about these differences would help to interpret the results of sensory-motor assessment in and across different surgical teams. In addition, rules for practice could be derived with the goal to converge the institutions' assessments to a cross-discipline and cross-institutional standard, as requested by other authors (see for example Duffau, 2013, 2014).

Maps of resectability and “maps of rehability”

Maps of resectability provide preoperative estimations of the “expected extent of the resection” (Ius et al., 2011, p. 993). Comparing preoperative and postoperative resection outcome, they computed the probability of leaving a functional tumoral residuum for each voxel of the brain (Ius et al., 2011). For each patient, the preoperative MRI can be overlapped by this map. As a result, information of the likelihood of tumor residuals due to function in cortical areas and fiber tracts are available before DCS mapping is conducted (Ius et al., 2011). For primary motor and somatosensory cortex and the ventral premotor cortex, these authors reported a high likelihood of residual tumor for upper and lower limb in both hemispheres. However, specifications of the concrete intraoperative assessment and DCS elicited events for the residual tumor sites are missing. One could argue that the decision to leave a tumor residue in the brain strongly depends on the assessment method. This is why a map of resectability strongly depends on the institutional protocol for awake surgery. Using a cross-institutional assessment method as provided by the SMP-a, resection maps with a higher generalizability can be constructed in the future.

Application of **lesion behavior mapping** (LBM) as used by Ius and colleagues (2011), is a promising method for future studies including the SMP-a. Here, intraoperative events elicited by DCS can be co-registered on MRI and DTI images and help to determine the critical regions for single tasks (Rorden, Fridriksson, & Karnath, 2009). The combination of LBM with a detailed behavioral assessment by the SMP-a might help to specify expected

impairments of specific areas during DCS, especially in areas with medium or low resectability as described by Ius and colleagues (2011). Based on these results, the **course of functionality** can be characterized for each residual tumor area in a next step by evaluating the relationship between intraoperative grade of impairment and course of postoperative impairment. This might result in estimations of the likelihood of recovery for different grades of impairment for each task, similar to the above discussed SMA-syndrome that showed a high probability of recovery after resection (Duffau, 2011c). Ultimately, this might lead to the generation of a “**map of rehability**”.

To date, only little is known about tailored rehabilitation for glioma patients (Khan, Amatya, Ng, Drummond, & Galea, 2015). With the SMP-a and an evaluation of rehabilitation, one might expect to gain helpful information about the impact of rehabilitation on sensory-motor deficits in glioma patients after awake surgery. As previously described, research on the course of planned deficits could support the neurosurgeons’ intraoperative decisions. If an intraoperative deficit is known to have good postoperative prognosis, an early cessation of resection can be prevented. In addition, future studies should evaluate the ecological validity of impairments in single tasks of the SMP-a, particularly its relationship to long-term return to work and quality of life.

Intraoperative decision making is always based on knowledge about the neuroplastic potential of the brain. Therefore, basic research studies on the brain’s potential for adaptive plasticity in response to lesions such as a glioma are of great value. As discussed above, this could be achieved via controlled trials evaluating rehabilitation but also with the help of imaging studies. The latter approach is described in the following section.

4.3 Neuroplasticity as a key concept: The ability of the right hemisphere for language functions

The third publication included in this thesis (Becker, Jehna, Larsen et al., 2016) addressed the surgical outcome regarding cognitive and language functions in a patient with a congenital missing hemisphere and a HGG in the remaining frontal lobe. This extremely rare combination of diseases provided a unique opportunity for insights into long- and short-term cerebral plasticity.

Due to the missing hemisphere during prenatal and later development, it can be assumed that this patient's brain had to make huge adaptations to achieve a normal range of cognitive and motor functions which are normally distributed across two hemispheres. A neuropsychological assessment 10 years ago revealed average cognitive performance, no aphasia and a spastic hemiparesis of the right arm. These results and the ordinary socio-professional life of the patient indicated successful large scale neuroplastic reorganization. Since the remaining hemisphere was obviously able to provide full functionality, his case can be considered as an example for functional compensation by remote homologues. It was previously argued that an additional lesion of areas which already compensate lost functions is considered to have a large potential for inducing permanent impairment in glioma patients (Duffau, Capelle, Denvil, Sichez, Gatignol, Lopes et al., 2003). Therefore, the growth of a GBM in the patient's single right frontal lobe was expected to have a large impact on his (cognitive) functioning. However, preoperative assessment showed unexpected high results for basic cognitive functions and language abilities, as well as other neurological functions, despite the large tumor. This data suggests that further neuroplastic changes triggered by the GBM helped to avoid severe cognitive and sensory-motor impairments. The patient's aphasic symptoms 10 years after the last assessment and the symptoms of mild cognitive impairment are in concordance with the suggested concept of a **threshold between compensation and impairment** (2007). As argued by these authors "slow-growing lesions exhaust progressively the plastic potential of the brain, letting us observe cognitive and physical deficits if a certain threshold is reached" (Desmurget et al., 2007, p. 910) .

One limitation of the present case report is the absence of long-term standardized data on neuropsychological assessment and MR-imaging. Therefore, no conclusions on the specific underlying structural neuroplastic changes were drawn. To overcome such limitations and gain information on structural plastic changes in glioma patients, we recently designed and initiated a bi-centric long-term study. The goal of this study is to determine the relationship between cerebral structures for language functions such as the arcuate fascicle (AF) and language performance in the long-term course (data acquisition in progress). First results of a pilot study investigating the role of the right hemispheric AF for compensation of language deficits in brain tumor patients emphasized the supportive value of a bilateral symmetry of the AF in these patients. More specific, only laterality of one segment of the AF and the tumor grade were significant predictor variables for speech disturbances (Jehna et al., in

press). We further hypothesize that glioma patients with bilateral AF show a better rehabilitation outcome, as already reported for stroke patients (Forkel et al., 2014). A future implementation of our results might lead to the use of preoperative structural imaging in the clinical routine, to determine the structure of the contralateral AF. If a sufficient structure on the contralateral side is present in the individual patient, tumor resection in the left hemisphere might be extended to total or near-total tumor removal instead of subtotal extirpation. This might result in a prolonged progression free time without increase of language deficits for the patient (see also Shields & Choucair, 2014).

As another open question, it remains unclear whether laterality might change due to white matter alterations in reaction to the tumor growth. In contrast to Duffau's summary (2009a) that there is "no evidence for structural white matter plasticity", more recent results argue in favor of changes in measurements of gray matter density or white matter integrity in healthy subjects (Li, Legault, & Litcofsky, 2014; Thomas & Baker, 2013; Zatorre, Fields, & Johansen-Berg, 2012). Using a longitudinal study design, we aim to investigate white matter plasticity in glioma patients, in whom adaptive plasticity is not initiated by mere learning of a new skill but by a lesion.

4.4 An integrative approach of comprehensive neuropsychological assessment in glioma patients undergoing awake surgery

The main goal of the presented research articles was to **improve neuropsychological diagnostic** for patients with intracranial tumors. In summary, the results of the studies document i) the superiority of a comprehensive neuropsychological test battery over screening tools, ii) successful implementation of a new standardized assessment tool for awake surgery and iii) insights into the plastic potential of the brain. In the following passages, the results are integrated into a comprehensive model of neuropsychological assessment for glioma patients (see Figure 5).

According to the proposed comprehensive testing approach, neuropsychological care starts with the initial diagnosis of a brain tumor and consecutive inpatient stay. Cognitive status diagnostic should be conducted with a comprehensive test battery. In contrast to a short screening tool, a test battery can detect even subtle cognitive impairments which might not

be identified by a standard neurological examination (Duffau, 2014). In addition, it provides valuable information on the patient's cognitive and functional eligibility for awake craniotomy (see section 2.2.3.1.2 Patients' eligibility for an awake craniotomy). The resulting cognitive profile highlights functions likely affected by tumor resection and can help to tailor the intraoperative tasks to the patient's needs and expectations ("**personalized therapeutic management**"; see also Duffau, 2014).

The preparation appointment for the awake surgery will further address factors that determine the individual quality of life for each patient, including job, habits, hobbies, and planned projects. In addition, possible deficits must be discussed with the patient. Valuable information on a patient's psychological eligibility can further be obtained by discussing his fears and concerns with respect to the awake procedure. A preoperative baseline of sensory-motor functions with the SMP-a should be assessed for further intraoperative comparison and outcome evaluation. With this in-depth preoperative protocol, the risk of misclassifying a patient as eligible for awake surgery is minimized. Patients with too low cognitive or sensory-motor capacity as well as severe aphasic disorders would be assigned for intubation narcosis. The preparation appointment also supports the goal of an informed consent for awake surgery. Another advantage is the thorough baseline assessment by the SMP-a as well as the standardized tests of the test battery, which can both be used for further research purposes and intern clinical evaluation of surgical outcome.

In some cases, patients are too impaired to be assessed with a test battery, even at their first inpatient stay. According to the results of our first study, we would suggest the application of the MoCA in such cases. An example of a preoperative status diagnostic with an adapted test battery in combination with a screening tool (MoCA) in a severely impaired patient is provided in our third study. The patient's status assessment had to be performed at the intensive care unit. During the anamnesis, a severe deceleration and low cognitive capacity became apparent. For this patient, language was the most important domain to be preserved. Therefore, the test battery was reduced to a standardized language assessment. Importantly, an awake craniotomy would have focused on language and motor functions. Thus, his eligibility for awake surgery needed to be assessed. The necessity to reduce the test battery to mere language assessment and a cognitive screening was regarded as an indicator for low cognitive functionality. In addition, reliable cortical mapping would have

been hindered by the patient’s substantial deceleration. In a similar vein, normal timing of DCS would have been too fast for this patient, probably hampering a valid interpretation of test results as it was the case in his preoperative fMRI assessment. In combination with the low KPS of 30 (unpublished data), which indicates a very low physical functionality, the duration of an awake surgery would have been too demanding. Consequently, we did not further pursue the preparation for awake surgery with the SMP-a in this patient.

To date, no general **guidelines** on exclusion criteria regarding cognitive, sensory-motor and psychological functioning **for awake craniotomy** exist. The proposed comprehensive preoperative neuropsychological assessment approach refers to several variables, with a potential relationship to intraoperative compliance (e.g. Capacity for test battery given? Moderate cognitive impairment? Sufficient language function?) and ability for cognitive mapping (e.g. at least moderate functionality in SMP-a tasks?). Future studies are necessary to determine their predictive value for intraoperative compliance and surgical success.

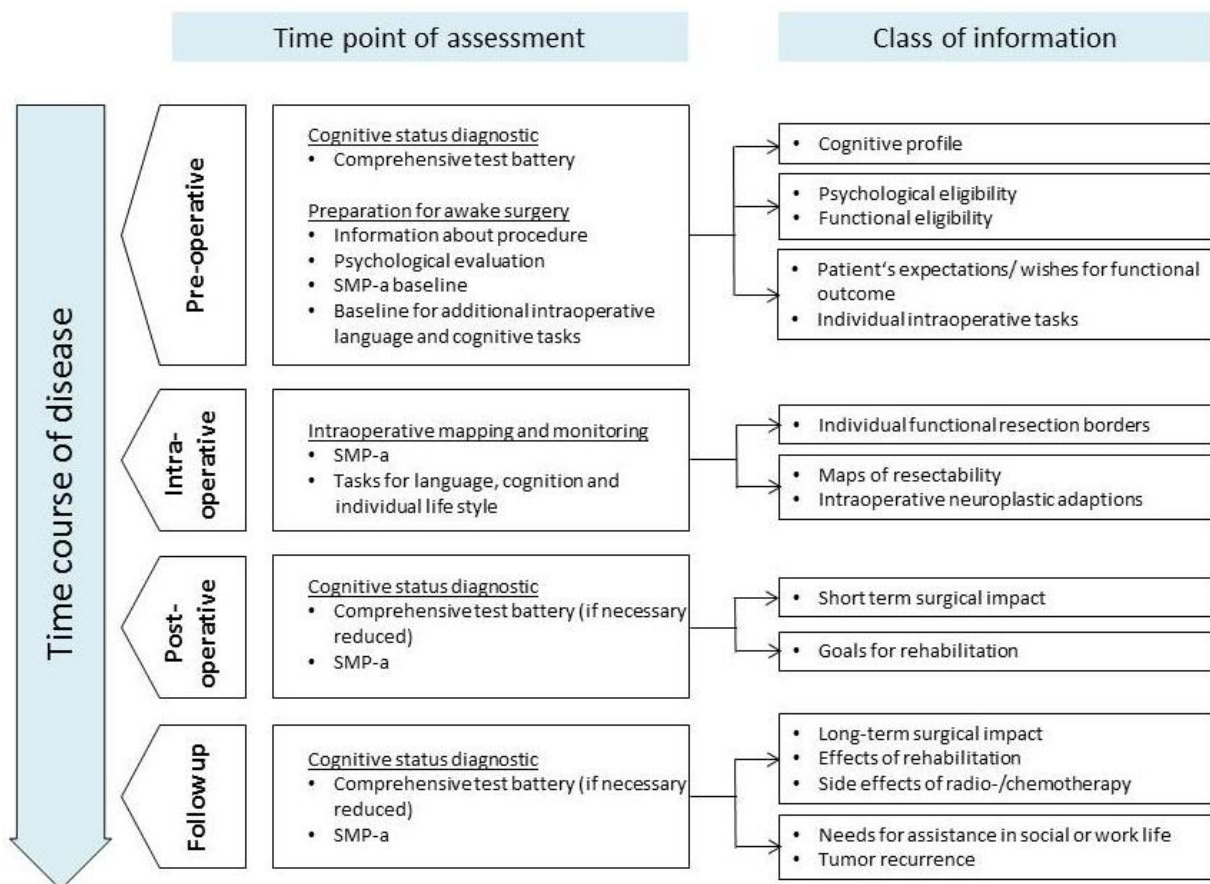


Figure 5: Integrative approach of comprehensive neuropsychological assessment in glioma patients undergoing awake surgery.

The objectives of neuropsychological assessment vary with the phase of disease and treatment (Giovagnoli, 2012). Directly after surgery, the immediate effects of the operation are in the focus. However, especially studies on the benefits of awake craniotomy over intubation narcosis still suffer of several shortcomings (Talacchi, Santini, Casagrande et al., 2013). These limitations include i) a rare assessment of cognitive functions with a comprehensive test battery, ii) missing follow-up assessment of postoperative morbidity, iii) high variance in the methods used for measurement of degree of deterioration and iv) rarely defined quality of deficits (Talacchi, Santini, Casagrande et al., 2013). To overcome these limitations in the area of sensory-motor function, the SMP-a was introduced for a standardized pre-, intra- and postoperative assessment. In addition, the use of the same test battery before and after the operation is suggested in the presented approach of neuropsychological assessment. We hope to be able to verify the beneficial influences of awake craniotomy compared to intubation narcosis by such a standardized evaluation protocol in the future.

Another objective of comprehensive neuropsychological assessment after surgical tumor removal is to plan a specific rehabilitation (Duffau, 2009b). Rehabilitation aims to reduce cognitive and physical impairments related to tumor growth and surgery. This in turn reduces the patient's need for assistance in everyday life and supports reintegration into working life. On the one hand, costs for rehabilitation of patients are a burden for the social health insurance system. On the other hand, an effective rehabilitation helps to ameliorate costs due to time absent from work (Hahn et al., 2003). In addition, costs due to psychological impairment such as depression are decreased. Cognitive and physical functioning are known predictors of quality of life (Bunevicius et al., 2014; Zucchella, Bartolo et al., 2013). Participation in normal life can palliate the burden of the disease and prevent depression (Bunevicius et al., 2014; Ford et al., 2012; Zucchella, Bartolo et al., 2013). There is some evidence that cognitive rehabilitation is effective in patients with high and low grade brain tumors (Giovagnoli, 2012). Nevertheless, a lack of control groups, randomized study designs and neuropsychological baseline or follow-up evaluation hinder precise assessment of the reliability and efficacy of cognitive rehabilitation for patients with intracranial tumors (Khan et al., 2015). The future goal should be to determine type, intensity and duration of rehabilitation for patients with intracranial tumors (Khan et al., 2015).

Beside the benefits of comprehensive cognitive testing, there might be a **risk of over-testing** glioma patients. In patients with a severe disease burden and a short life expectancy, time consuming assessments may increase fatigue and distress (Giovagnoli, 2012). This might especially affect follow-up assessments, where additional treatments such as radio- and chemotherapy as well as tumor recurrence might have further reduced the patient's cognitive and physical state. Here, it is recommended to reduce test batteries to tools for determining awareness and reliability of informed consent before investigations or treatments are initiated (Giovagnoli, 2012). As an alternative to a reduced test battery, the method of **stepwise evaluation** may satisfy clinical indications, patient's fatigability and staff burden (Giovagnoli, 2012). Here, the test protocol is adaptive and ranges from a brief screening of dedicated functions to a detailed examination, if impairments are presumed.

4.5 Concluding remarks

In summary, the present work pointed out various requirements of the neuropsychological assessment in the context of glioma patients undergoing awake surgery. Due to the short history of this specialized discipline, there are still methodological gaps regarding the standardized and goal oriented diagnostic in awake surgery to date. The presented studies aimed to fill these gaps, but also generated novel questions for future studies.

The first study showed that the BCSE cannot be used as valid instrument for cognitive screening in patients with intracranial tumors. For screening purposes, the MoCA turned out to be the best available tool, in clinical as well as research settings. However, a comprehensive test battery could not be replaced by any screening tool. Beside a differentiated cognitive performance profile, a test battery in particular provides additional information on the patient's eligibility for an awake craniotomy and information for individual composition of intraoperative tasks. The second study outlined the lack of a standardized tool for sensory-motor assessment in awake craniotomies. In consequence, the SPM-a was introduced as a feasible tool for pre-, intra- and postoperative assessment purposes. Its validation with other scales for sensory or motor assessment as well as evaluation of its reliability are goals for future multicenter studies. The case report of a HGG in a patient with a congenital absent hemisphere in the third study illustrated the large potential of the human brain for neuroplastic adaption. The good pre- and postoperative

outcome of this patient as well as results of previous works stimulated new hypotheses on the brain's potential for adaptive plasticity. In particular, a long-term study on neuroplasticity of language associated brain areas and white matter tracts in glioma patients was initiated. Results of the first pilot study indicated the relevance of the right hemispheric arcuate fascicle for language performance in patients with tumors in the language dominant hemisphere (Jehna et al., in press). After sufficient evaluation of the SMP-a, an analogous study on plasticity of sensory-motor networks in glioma patients is planned in the future. The long-term objective is an improvement of neuropsychological information supply for medical decision making, and in particular the improvement of the protocol for awake surgeries.

5 SUMMARY

With only 15 newly diagnosed adults per 100.000 inhabitants per year, the prevalence of gliomas (i.e., an intracranial tumor which emanates from neurons and glial supporting tissue) is relatively low. However, the disease and its treatment represent a serious medical condition (Poeck & Hacke, 1998). Gliomas are classified by the world health organization (WHO) in a scheme of four grades of malignancies, according to their histological profile (Poeck & Hacke, 2006). It is common to divide gliomas into low and high grade gliomas (LGG, respectively HGG) due to their different biological behavior. LGGs tend to grow slowly and infiltrate intact brain tissue whereas HGGs grow very fast and more encapsulated (Poeck & Hacke, 1998). Removal of the tumor by neurosurgical operation is the first treatment step to prevent further tumor growth. Tumor surgery aims at maximizing the resection and thereby increasing the patient's survival time. However, surgery can cause severe cognitive and neurological deficits upon injuring eloquent areas. These areas are specialized for dedicated functions such as language or motor function, and resection bears the risk of inducing permanent deficits. Hence, for patients with tumors in eloquent areas a surgery under awake conditions is usually recommended (Duffau, 2011a). During an awake craniotomy the patient is fully conscious and his motor or cognitive abilities can be assessed with diagnostic tasks. With the help of direct cortical stimulation (DCS), maps of cognitive and sensory-motor functions for the individual patient can be compiled intraoperatively. These maps help the neurosurgeon to identify cortical areas and white matter tracts necessary for a specific function (Duffau, 2011a). Therefore, identified eloquent areas will be maintained (Duffau & Mandonnet, 2013). For awake surgery the responsibilities of a neuropsychologist lie in the correct evaluation of a patient's eligibility for the procedure, a valid and reliable pre- and intraoperative assessment of cognitive and sensory-motor functions and an evaluation of the direct and long-term operative outcome, including planning of target-oriented rehabilitation.

As outlined above, the tumor itself but also its treatment with surgery and subsequent radio- and/or chemotherapy can cause changes in sensory-motor abilities, cognitive functioning, personality and affect (Poeck & Hacke, 1998). Indeed, disturbances of language, memory, attention, orientation or planning are frequently found in patients with intracranial tumors (Klein et al., 2002; Meyers et al., 2000; Murray et al., 2000; Santini, Talacchi, Squintani et al.,

2012; Satoer et al., 2012; Scheibel et al., 1996; Scotland et al., 2012; Talacchi et al., 2011; Taphoorn & Klein, 2004; Tucha et al., 2000). Patients with HGGs show lower preoperative cognitive functioning compared to patients with LGGs (Campanella et al., 2015). Data on prevalence of impairments regarding memory, attention and executive functioning in patients with LGGs range from 19% to 83% (van Loon et al., 2015). The time course regarding cognitive deficits can differ significantly depending on tumor type and additional treatment. While 60% of LGG patients were able to return to work, this was only the case in 10-20% of HGG patients in a previous study (Armstrong et al., 2016). Another study (Santini, Talacchi, Squintani et al., 2012) reported that 3-6 months after the operation, 45% of patients showed a decline in cognitive functioning, whereas improvement was reported in 5% of the patients. In another 33% of the patients no changes were found (Santini, Talacchi, Squintani et al., 2012). However, the amount of surgery-induced cognitive impairments cannot be validly estimated since studies on the direct comparison of pre- and postoperative cognitive functionality immediately after the resection are rare (Klein et al., 2012). The high range of the prevalence data can be traced back to high variance in time point of assessment (before/after the operation and course of the disease), different patient samples (first diagnosis, recurrence), different neuropsychological assessment methods (selection of tests, evaluation focus like test-specific or domain-specific analysis) and different criteria for impairment. To date, there is no consensus on how to assess cognitive impairment in patients with intracranial tumors (van Loon et al., 2015).

Prevalence data indicate that a substantial portion of patients has no or only mild cognitive and neurological deficits. Some patients even increase in cognitive and physical functioning after impairments become evident. This can be attributed to the brain's ability to compensate for lesion induced neuronal malfunctions, so called neuroplasticity (Duffau, 2011b). Research findings on the ability for neuroplastic changes in the brain have significant implications for awake surgery. For instance, with the knowledge about transient impairments after resection of an area such as the supplementary motor area that resolve due to neuroplastic changes within a few months, the removal of this area could be recommended.

The present work sought to describe and define the requirements for neuropsychological diagnostic in emergency hospitals treating patients with intracranial tumors. The aim was to

validate current methods and establish a reliable neuropsychological assessment routine for patients undergoing awake surgeries. In addition, a specific diagnostic method for the very special context of intraoperative diagnostics in awake craniotomy was established and evaluated.

The first study in this thesis mainly focused on cognitive status diagnostic and was motivated by the question whether an excellent cognitive screening instrument might be able to substitute a comprehensive neuropsychological test battery. Consequently, the first publication (Becker, Steinmann et al., 2016) investigated if the recently published screening tool “Brief Cognitive Status Diagnostic” (BCSE) has overcome the limitations of the Mini Mental State Examination (MMSE) and Montreal Cognitive Assessment (MoCA) and represents a valid tool for patients with intracranial tumors. Particularly, we examined whether the BCSE would be more reliable than the older screenings in i) detecting patients with intracranial tumors versus healthy subjects and ii) detecting cognitive impaired subjects in a patient cohort asserted by the “gold standard” of a comprehensive neuropsychological test battery covering several cognitive domains.

For the first time, we were able to show that the BCSE has a good feasibility in patients with intracranial tumors. However, it did not allow for a valid separation of healthy individuals from patients or and was not sensitive enough to reliably detect cognitive impairment in patients. As a screening measure, we thus recommend the MoCA instead of BCSE and MMSE due to its favorable diagnostic quality. Nevertheless, in good agreement with other studies, our results support the view that reliable results could only be obtained with a comprehensive neuropsychological test battery, since even the MoCA failed to detect cognitive impairment.

After the first publication clearly indicated the relevance of a comprehensive test battery for cognitive status diagnostic, the second study aimed at improving standardized intraoperative assessment. A review of the existing literature revealed the following major limitations in scales used for sensory-motor functions in the context of awake craniotomy so far: i) lack of practicability, ii) lack of assessing highly relevant functions, and iii) lack of precision in item phrasing or scoring system. To bridge this gap, we designed a rating scale, the Sensory-Motor Profile awake (SMP-a) a suitable tool for awake surgery. We aimed at combining the

advantages of existing neurological scales used for preoperative and postoperative assessment in this setting and evaluated the feasibility of the SMP-a in 17 patients.

Our results support our assumption that the SMP-a is a feasible tool which can be integrated into clinical routine. Furthermore, the SMP-a was applicable even in patients with symptoms of mild aphasia or moderate sensory-motor deficits caused by tumor recurrence. The SMP-a represents the first flexible rating scale for sensory-motor functions which enables individual adaption, but preserves the standardized scoring system. This will allow the comparison between assessment dates, patients and institutions in future applications. However, future studies are mandatory to provide data on the instrument's diagnostic properties with respect to feasibility, objectivity, validity and reliability.

As outlined above, neuroplasticity is a key concept for awake surgery and influences the surgical approach of awake craniotomy considerably (Ius et al., 2011). Since invasive experimental lesion approaches cannot be carried out in healthy human participants due to ethical concerns, this branch of research is dependent on patients with brain lesions. Therefore, results obtained from patients with unique or rare disease constellations complement the results of the few empirical studies. Our third publication (Becker, Jehna, Larsen et al., 2016), which presents a case report of a HGG in a patient with a congenital absent hemisphere, illustrated the huge potential of the human brain for neuroplastic adaption. This patient was born with only one hemisphere and developed a HGG in his single frontal lobe. Ten years ago, neuropsychological assessment revealed average cognitive performance in this patient, without any signs of aphasia but a spastic hemiparesis of the right arm. These results and the patient's relatively normal socio-professional life indicated successful large scale neuroplastic reorganization. Due to the fact that his single hemisphere was already forced to compensate for the missing one, we expected that this patient would now present with severe cognitive deficits due to the tumor. However, in contrast to our hypothesis, he showed only a deceleration, moderate deficits in language functions as well as mild impairments of basic cognitive functions. We assumed that his single hemisphere was able to establish further neuroplastic mechanisms to compensate for the tumor growth. The good operative outcome of this patient as well as results of previous works stimulated a new hypothesis on the brain's general potential for plasticity. In particular, neuroplasticity of language associated brain areas and white matter tracts is currently investigated in

subsequent long-term research in our glioma patients. First results of a pilot study revealed a positive relationship between the volume of the right hemispheric arcuate fascicle (AF) homologue and a better language performance in patients with glioma in the left sided, language dominant hemisphere (Jehna et al., in press). Similar positive relationships were reported by Forkel and colleagues (2014) for rehabilitation of language and the bilateral symmetrical arrangement of the AF in stroke patients. If additional studies yield similar results, a more extensive resection of tumor tissue in the left hemisphere in patients with bilateral symmetrical AFs might be implemented in neurosurgical settings in the future. After sufficient evaluation of the SMP-a, an analogues study on plasticity of sensory-motor networks in glioma patients is planned.

The results of the studies included in this thesis can be integrated into a comprehensive approach for neuropsychological assessment in glioma patients eligible for awake craniotomy. The advantages of a comprehensive test battery are reflected in the reduction of the risk to miss cognitive impairments. Furthermore, it provides the opportunity to assess valuable additional information about a patient's eligibility for an awake craniotomy such as frustration tolerance or compliance under stress. The novel tool SMP-a can be integrated into a preparation appointment for awake surgery. Therewith, a baseline assessment of sensory-motor function is established for further evaluation. In addition, the SMP-a can serve as a base for further discussion of possible intraoperative impairments and the patient's fears. This helps the neuropsychologist to gain information on a patient's emotional stability and estimate his intraoperative compliance. During awake surgery, cortical mapping and functional monitoring of sensory-motor functions can be conducted with the SMP-a beside individually selected tasks for other functions such as language. The same tools as used for preoperative and intraoperative assessment serve as postoperative test battery, with the goal to plan a rehabilitation adapted to the patient's needs and evaluate operative short-term and long-term outcome in a standardized fashion.

In summary, our studies provide novel results that might help clinicians to choose reliable and valid methods for a comprehensive assessment of glioma patients undergoing awake surgery. In addition, this work outlined the importance of comprehensive neuropsychological assessment for research purposes and revealed several areas of missing standardization such as surgical long-term evaluation. Future studies are necessary to

evaluate the presented tools, especially the SMP-a, and develop guidelines for inclusion and exclusion of patients in awake craniotomy. Additionally, research on the ecological validity of test results should be intensified with the goal to further include the patients' perspective on impairments and quality of life into neurosurgery. The same is true for a precise assessment of efficacy of (cognitive) rehabilitation for patients with intracranial tumors. This includes the mandatory evaluation of so called "planned deficits" under awake surgery. One future goal should be the compilation of maps including information on resectability and estimated rehabilitation success for dedicated brain sites, which can then be integrated into routine surgical planning.

6 DEUTSCHE ZUSAMMENFASSUNG (SUMMARY IN GERMAN)

Die klinische Neuropsychologie ist im 21. Jahrhundert als eigenständige Fachdisziplin der kognitiven Neurowissenschaften mit eigenen Universitätslehrstühlen, Vereinigungen und Fachzeitschriften etabliert (Goldenberg, 2007). Als wissenschaftliche Disziplin zielt sie darauf ab, die zentralnervösen Mechanismen zu verstehen, welche menschlichem Verhalten und Erleben zu Grunde liegen (Hartje & Poeck, 2006). Hierfür werden fortlaufend Befunde aus der „klassischen“ Psychologie, Neurologie, Neuroanatomie und Neurophysiologie integriert. Als Schnittstelle zwischen Medizin und Psychologie wächst die Bedeutung der klinischen Neuropsychologie angesichts des steigenden durchschnittlichen Alters der Bevölkerung und der damit einhergehenden wachsenden Zahl an behandlungsbedürftigen Hirnerkrankungen. Sowohl für die Prognose als auch für die Therapie der Erkrankungssymptome ist eine valide neuropsychologische Diagnostik von hoher Relevanz.

Infolgedessen stellt die Diagnostik von kognitiven und affektiven Beeinträchtigungen nach einem Hirnschaden ein erstes, elementares Tätigkeitsfeld für Neuropsychologen dar. Die diagnostischen Fragestellungen umfassen die klassische Status- und Verlaufsdagnostik wie auch die patientenorientierte Erstellung von Behandlungsplänen. Für ein qualitativ hochwertiges Vorgehen hilft die Orientierung an Standards aus der klinischen und allgemeinspsychologischen Diagnostik. Im Gegensatz zu den vorgenannten Disziplinen werden im Rahmen der neuropsychologischen Diagnostik basale und höhere Wahrnehmungsleistungen, Gedächtnisfunktionen, Konzentration, Aufmerksamkeit und senso-motorische Funktionen wie auch spezifische arbeits- und ausbildungsbezogene Funktionen erfasst. Diese werden häufig durch eine Evaluation des Affektes und der Persönlichkeit eines Patienten ergänzt (Hartje & Poeck, 2006). Ein zweites Haupttätigkeitsfeld für Neuropsychologen liegt in der Therapie von funktionellen Beeinträchtigungen nach einem Hirnschaden. Ziel ist hier die Wiedereingliederung des Patienten in sein soziales und berufliches Leben (Sturm et al., 2007).

Die Aufgaben der klinischen Neuropsychologie in der ambulanten Diagnostik und der Rehabilitation sind in der bestehenden Literatur bereits gut beschrieben. Es gibt jedoch bislang keine umfassenden Arbeiten, welche die externen Anforderungen und spezifischen diagnostischen Fragestellungen für die Neuropsychologie im Kontext der Neurochirurgie thematisiert. Die vorliegende Arbeit sollten die spezifischen Anforderungen, welche ein

Akutkrankenhaus zur Behandlung von Hirntumorpatienten stellt, beschrieben und definiert werden. Das Hauptziel war dabei, die derzeit angewendeten Methoden zu validieren und eine reliable neuropsychologische Routinediagnostik für Patienten im Rahmen der Wachoperation zu etablieren. Im Besonderen wurde eine Methode für die spezielle intraoperative Diagnostik für Wachoperationen neu entwickelt und evaluiert.

Intrakranielle Gliome zählen zu den primären Hirntumoren und wachsen aus Neuronen und glialen Stützzellen des Gehirns (Poeck & Hacke, 1998). Sie werden anhand ihrer biologischen Eigenschaften in vier Tumorgrade nach WHO (world health organization) eingeteilt (Poeck & Hacke, 2006). Die Zellen von niedriggradigen Gliomen (low grade glioma, LGG) mit einem WHO-Grad I und II neigen im Laufe der Zeit zur anaplastischen Transformation. Hierdurch entstehen höhergradige Tumoranteile (Grad III und IV), welche unter anderem ein schnelleres Tumorwachstum mit sich bringen (Shaw et al., 2002). Dies betrifft circa 79% der LGG-Patienten (Shaw et al., 2002). Die medizinische Behandlung von Gliomen sieht in den meisten Fällen eine chirurgische Entfernung des Tumors vor. Bei bestimmten (höhergradigen) Gliomen wird eine Chemo- und/oder Bestrahlungstherapie angeschlossen. Im Langzeitverlauf zeigen niedriggradige Tumoren ein längeres Intervall bis zum ersten Rezidiv und eine deutlich höhere durchschnittliche Überlebenszeit als höhergradige Tumoren (Poeck & Hacke, 2006). Bei höhergradigen Gliomen (high grade glioma, HGG) kann trotz wiederholter Operationen und begleitender Radio-Chemotherapie der Verlauf der Erkrankung nur um wenige Monate oder Jahre aufgeschoben werden.

Eine Besonderheit stellen Tumoren mit einer Lokalisation in so genannten eloquenten Arealen dar (Chacko et al., 2013). Eloquente Areale bezeichnen Hirnstrukturen, welche auf bestimmte Funktionen wie beispielsweise Sprache oder Motorik spezialisiert sind. In solch einem Fall kann die Operation zur Entfernung des Tumors als Wachoperation durchgeführt werden (Chacko et al., 2013). Bei dieser Operationsform ist der Patient während der Tumorresektion bei vollem Bewusstsein und kann mithilfe diagnostischer Tests untersucht werden. Ergebnis dieser Diagnostik ist eine intraoperative Kartierung der Funktionen im Operationsgebiet. Die erstellte Karte kann die Resektionsentscheidungen des Neurochirurgen beeinflussen, da Hirnareale trotz Tumorinfiltration belassen werden, wenn sie sich als funktionsrelevant erweisen. Ziel ist es, durch die intraoperative Diagnostik am wachen Patienten den Tumor so vollständig, aber schonend wie möglich zu entfernen und

dauerhafte Beeinträchtigungen zu vermeiden. Wachoperationen haben bereits in den 1940er Jahren ihren Ursprung, als Wilder Penfield das freiliegende Gehirn seiner Epilepsiepatienten mit elektrischen Impulsen stimulierte und ihre Reaktionen darauf für diagnostische Zwecke studierte (Penfield & Boldrey 1937). Auch heute noch gelten Wachoperationen mit direkter kortikaler Stimulation (direct cortical stimulation, DCS) für die Gliomchirurgie als Goldstandard (Mandonnet, 2011). Trotz großer technischer Entwicklungen in der präoperativen und intraoperativen Bildgebungstechnik stellt die Kartierung von zerebralen Funktionen mit Hilfe der DCS derzeit die reliabelste Methode dar, um das Risiko eines untersuchten Areals für eine permanenten Beeinträchtigung durch eine Resektion abzuschätzen (Ius et al., 2011). DCS kann als Modell für eine transiente virtuelle Läsion des stimulierten Areals angesehen werden. Die Funktion von Kortexarealen, aber auch verbindenden Faserbahnen der weißen Substanz, wird durch die Applikation eines kurzen Stromimpulses unterbrochen oder auch angeregt (Duffau, 2011a). Ist es dem Patienten in der Folge beispielsweise nicht mehr möglich, ein Bild zu benennen, wird das stimulierte Areal als essentiell für die untersuchte Funktion angenommen und folglich nicht reseziert (Duffau, 2011b). Aufgabe der neuropsychologischen Diagnostik im Kontext von Wachoperationen ist es, die Eignung eines Patienten für eine Wachoperation fest zu stellen. Darüber hinaus müssen kognitive und senso-motorische Funktionen prä- aber auch intraoperativ valide und reliabel erfasst werden. Des Weiteren kann das direkte wie auch das langfristige Operationsergebnis evaluiert werden, um die eingesetzten Vorgehensweisen weiter zu verbessern. Die postoperative Untersuchung umfasst zusätzlich die Planung der zielorientierten Rehabilitation.

Sowohl der Tumor selbst als auch seine Behandlung mit Operationen, Radio- und Chemotherapie können Veränderungen in den physiologischen und kognitiven Funktionen, der Persönlichkeit und dem Affekt auslösen (Poeck & Hacke, 1998). In der Praxis werden Einschränkungen der Sprache, des Gedächtnisses, der Aufmerksamkeit, der Orientierung und der Handlungsplanung häufig bei Patienten mit intrakraniellen Tumoren beobachtet (Klein et al., 2002; Meyers et al., 2000; Murray et al., 2000; Santini, Talacchi, Squintani et al., 2012; Satoer et al., 2012; Scheibel et al., 1996; Scotland et al., 2012; Talacchi et al., 2011; Taphoorn & Klein, 2004; Tucha et al., 2000). Patienten mit HGG zeigen größere präoperative kognitive Einschränkungen als Patienten mit LGG (Campanella et al., 2015). Die Prävalenzzahlen zu Einschränkungen im Gedächtnis, der Aufmerksamkeit und den

exekutiven Funktionen reichen von 16% bis 83% (van Loon et al., 2015). Der Verlauf der kognitiven Einschränkungen bei Hirntumorpatienten unterscheidet sich deutlich zwischen den verschiedenen Tumorarten und den zusätzlichen Behandlungen. Beispielsweise kehren 60% der LGG-Patienten in ihren Beruf zurück, bei HGG-Patienten sind dies lediglich 10-20% (Armstrong et al., 2016). 3-6 Monate nach der Operation weisen 45% der Patienten eine weitere Verschlechterung der kognitiven Funktionen auf, wohingegen eine Verbesserung für nur 5% berichtet wird (Santini, Talacchi, Squintani et al., 2012). Bei einem Drittel der Patienten tritt keine Veränderung im Vergleich zum präoperativen Status ein (Santini, Talacchi, Squintani et al., 2012). Trotz der genannten Studien kann das Ausmaß der operationsinduzierten kognitiven Beeinträchtigungen derzeit noch nicht valide eingeschätzt werden, da die Zahl der Studien mit einem direkten Vergleich von prä- und postoperativen Ergebnissen noch zu gering ist (Klein et al., 2012). Die hohe Varianz der Prävalenzzahlen kann auf deutliche Unterschiede der einzelnen Studien bzgl. des Erhebungszeitpunkts (vor/nach der Operation oder im Verlauf), der Patientengruppen (Erstdiagnose, Rezidiv), der eingesetzten neuropsychologischen Erhebungsmethoden (Testauswahl, Evaluationsfokus Einzeltest oder Domänen bezogen) und der Kriterien für das Vorliegen einer Beeinträchtigung zurückgeführt werden. So herrscht bislang kein Konsens bezüglich der Erhebung von kognitiven Beeinträchtigungen bei Hirntumorpatienten (van Loon et al., 2015).

Die genannten Prävalenzzahlen legen nahe, dass ein gewisser Anteil von Patienten vor, aber auch nach der Operation keine oder nur geringe kognitive und neurologische Defizite aufweist. Andere Patienten wiederum zeigen Verbesserungen in ihrem funktionellen Status, nachdem Beeinträchtigungen festgestellt geworden sind. Diese Beobachtungen können auf die Fähigkeit des Gehirns zurückgeführt werden, läSIONSINDUZIERTE neuronale Funktionsstörungen zu kompensieren, die so genannte Neuroplastizität (Duffau, 2011b). Hierbei unterscheiden bisherige Untersuchungen kurzzeitige Anpassungen innerhalb von Minuten oder Stunden und mittel- bzw. langfristige Veränderungen (Duffau, 2011c). Neben der zeitlichen Dimension konnten fMRT-Studien eine hierarchische Strukturierung der durch einen (niedriggradigen) Tumor ausgelösten neuronalen Anpassungen belegen (Desmurget et al., 2007). So sind in einem ersten Schritt noch funktionelle neuronale Areale innerhalb des Tumors auffindbar, in einem zweiten Anpassungsschritt verteilen jedoch neuroplastische Mechanismen eloquente Areale um das Tumorgewebe herum um. Sollte die Kompensation nach wie vor unzureichend sein, kann eine Funktionsübernahme durch entferntere Areale

innerhalb der erkrankten Hirnhemisphäre und/oder durch kontralaterale homologe Areale erfolgen (Desmurget et al., 2007). In der präoperativen Erkrankungsphase erlauben LGGs, da sie langsam wachsen, eine bessere Anpassung der neuronalen Funktionen als akute Läsionen wie bspw. ein Schlaganfall (Desmurget et al., 2007). Dies äußert sich unter anderem in einer signifikant geringeren Rate an neurologischen und neuropsychologischen Ausfällen im Vergleich zu Schlaganfallpatienten (Desmurget et al., 2007). Darüber hinaus unterscheiden sich langsam und schnell wachsende Läsionen in ihrem Muster der Anpassung: langsam wachsende Läsionen rekrutieren häufiger ipsilaterale, entfernte Areale und kontralaterale homologe Areale (Desmurget et al., 2007). Während der Operation scheint es durch die Resektion selbst zu spontanen Veränderungen in funktionalen Netzwerken zu kommen und es können, Dank intraoperativer Diagnostik am wachen Patienten, während der Operation redundante, jedoch bislang stille Areale identifiziert werden (Duffau, 2011c). Ihr tumorinfiltriertes Gegenstück kann reseziert werden und das vormals redundante Areal übernimmt die Funktion spontan (Duffau, 2011c). Auch postoperativ können neuroplastische Veränderungen durch spezifische Rehabilitation gefördert werden (Duffau, 2011c; Zucchella, Capone et al., 2013). Die geschilderten Befunde führten bislang zu zwei wichtigen therapeutischen Implikationen. Zum Einen konnte die Annahme, dass verschiedene Hirnbereiche und Funktionen ein unterschiedliches Potential für plastische Veränderungen aufweisen, durch eine Studie von Ius und Kollegen (2011) untermauert werden. Sie erstellten mit Hilfe von DCS eine Karte über die Wahrscheinlichkeiten, funktionelle Areale innerhalb eines tumorinfiltrierten Areals zu identifizieren. Eine hohe Wahrscheinlichkeit hierfür wurde insbesondere für den primären motorischen und sensorischen Kortex angegeben. Ergänzend hierzu veröffentlichte Duffau eine Aufzählung von Hirnarealen, deren Entfernung oft nur mit einer vorübergehenden Einschränkung assoziiert ist, wie bspw. das supplementär motorische Areal (SMA) (Duffau, 2011c). Zusammengefasst erlauben beide Forschungsergebnisse durch Anwendung auf den individuellen Patienten, das Ausmaß der möglichen Resektion und der unmittelbar folgenden Einschränkungen vor der Operation abzuschätzen. Die zweite wichtige therapeutische Implikation stellt das Vorgehen der „gestaffelten Operationen“ (staged neurosurgical approach) dar (Talacchi, Santini, Casagrande et al., 2013; Talacchi, Santini, Casartelli et al., 2013). Es ist bereits gut belegt, dass Faktoren wie die Resektion selbst, die anschließende Rehabilitation und das erneute Tumorwachstum funktionelle Anpassungen

im Gehirn auslösen (Duffau, 2011c). Sollten bei einem individuellen Patienten während der Operation nach wie vor eloquente Areale innerhalb des Tumors identifiziert werden, können diese zum Zweck der Erhaltung der Funktion belassen werden. In diesem Fall kann gewartet werden, bis zusätzliche neuroplastische Veränderungen zur Relokalisation der Areale geführt haben und eine Folgeoperation Monate oder Jahre später die vollständige Resektion erlaubt (Duffau, 2011c). Bedingt durch ethische und strukturelle Hindernisse ist die Untersuchung der Neuroplastizität des menschlichen Gehirns schwierig, so dass bislang nur wenig über Prädiktoren und Limitationen des plastischen Potentials bekannt ist. Einen limitierenden Faktor stellen weiße Faserbahnen dar: eine gewisse Mindestanzahl an verbindenden weißen Faserbahnen muss bei der Operation belassen werden, um eine funktionelle Rehabilitation zu erlauben (Ius et al., 2011). Dies wird derzeit darauf zurückgeführt, dass das menschliche Gehirn keine Möglichkeit hat, neue Faserbahnen in der weißen Substanz zu bilden (Duffau, 2009a). Vor diesem Hintergrund erscheint eine valide intraoperative Diagnostik zur Identifizierung von funktionellen Faserbahnen umso wichtiger.

Die oben geschilderten Befunde verdeutlichen den hohen Stellenwert von standardisierter und valider neuropsychologischer Diagnostik vor wie auch während der Operation. Den Fokus der vorliegenden Arbeit bildete daher die Erstellung eines Konzeptes zur neuropsychologischen Diagnostik von Patienten für Wachoperationen. Hierfür wurden die Ergebnisse dreier Publikationen integriert.

Die erste Publikation der vorliegenden Arbeit konzentrierte sich auf die neuropsychologische Statusdiagnostik bei neurochirurgischen Patienten. Motiviert wurde die Untersuchung durch die Frage, ob ein kognitives Screeninginstrument für diesen Zweck ausreichend sein kann. Hierfür wurde das neu publizierte Screeninginstrument „Brief Cognitive Status Exam“ (BCSE) mit den beiden in diesem Kontext am häufigsten genutzten Instrumenten, dem Mini Mental State Examination (MMSE) und dem Montreal Cognitive Assessment (MoCA), verglichen. Untersucht wurde die Fragestellung, ob der BCSE die Limitationen der beiden anderen Instrumente bzgl. der diagnostischen Qualität überwunden hat und ein valides Screeninginstrument im neurochirurgischen Kontext darstellt. Im Besonderen untersuchten wir, ob der BCSE reliabler als die beiden älteren Instrumente i) Patienten mit intrakraniellen Tumoren von gesunden Probanden unterscheiden kann und ii) kognitiv eingeschränkte

Patienten (erhoben mit dem Goldstandard einer umfassenden neuropsychologischen Testbatterie) aus einer Patientenkohorte identifizieren kann.

Unsere Ergebnisse zeigten erstmalig, dass der BCSE bei Hirntumorpatienten eine vergleichbar gute Anwendbarkeit wie der MMSE und der MoCA aufweist. Jedoch erreichte er keine zufriedenstellenden Ergebnisse bei der Identifizierung von Patienten unter gesunden Probanden und bei der Identifizierung von kognitiven Einschränkungen in einer Patientenkohorte. Aufgrund seiner in den meisten Bereichen überlegenen diagnostischen Qualität haben wir den MoCA für den Einsatz als Screeninginstrument bei Hirntumorpatienten empfohlen. Dennoch zeigten die Ergebnisse auch, dass selbst ein gutes Screeninginstrument wie der MoCA einer Testbatterie unterlegen ist, da auch er kognitive Einschränkungen nicht immer ausreichend verlässlich identifizierte. Somit konnten wir, in Übereinstimmung mit anderen Studien, die Ansicht unterstützen, dass reliable Ergebnisse in Bezug auf den kognitiven Status von Hirntumorpatienten nur mit einer umfassenden neuropsychologischen Testbatterie erhoben werden können.

Nachdem in der ersten Publikation gezeigt werden konnte, dass im Rahmen der kognitiven Statusdiagnostik eine umfassende neuropsychologische Testbatterie einem guten Screeninginstrument nach wie vor überlegen ist, zielte die zweite Untersuchung auf die Evaluation der intraoperativen Diagnostik ab. Eine systematische Durchsicht der bisherigen Literatur deckte signifikante Mängel der bislang für die Erfassung senso-motorischer Funktionen genutzter Ratingskalen bei Wachoperationen auf: a) eine eingeschränkte Anwendbarkeit besonders intraoperativ, b) einen Mangel an Erfassung hoch relevanter Funktionen wie bspw. Sensorik, sowie c) eine mangelnde Präzision bei der Itemformulierung oder des Ratingsystems (Becker, Jehna, Steinmann et al., 2016). Um diese Lücke zu schließen, wurde eine Ratingskala für die Anwendung bei Wachoperationen, das Sensory-Motor Profile awake (SMP-a), entworfen. Ziel war es, die Vorteile der bereits prä- und postoperativ genutzten neurologischen Skalen zu kombinieren und die Anwendbarkeit des SMP-a zu evaluieren.

Die Ergebnisse der zweiten Studie unterstützen die Annahme, dass das SMP-a ein geeignetes Instrument für den angestrebten Kontext ist und in die klinische Routinediagnostik für Wachoperationen integriert werden kann. Darüber hinaus konnte gezeigt werden, dass das SMP-a auch bei Patienten mit leichter Aphasie und mittelgradigen senso-motorischen

Einschränkungen, wie sie beispielsweise oft durch ein Tumorrezidiv verursacht werden, einsetzbar war. Das vorliegende Instrument stellt die erste flexible Ratingskala für sensorische Funktionen dar, welche die individuelle Adaptation an die Patientenbedürfnisse gestattet, dabei jedoch ihr standardisiertes Ratingsystem beibehält. Das SMP-a erlaubt damit in zukünftigen Studien einen Vergleich von Ergebnissen zwischen unterschiedlichen Institutionen, verschiedenen Patienten und Erhebungszeitpunkten. Allerdings sind im Vorfeld weitere Studien mit größeren Patientenkollektiven notwendig, um die diagnostischen Kennwerte des SMP-a in den Bereichen Anwendbarkeit in anderen Kliniken, Objektivität, Validität und Reliabilität zu evaluieren.

Wie bereits oben angeführt, stellt die Neuroplastizität ein Schlüsselkonzept für Wachoperationen dar und beeinflusst das operative Vorgehen maßgeblich. Da sich experimentelle Läsionsuntersuchungen am Menschen aus ethischen Gründen verbieten, ist dieser Zweig der Forschung auf Patienten mit vorliegenden Hirnläsionen angewiesen. Daher ergänzen die Untersuchungsergebnisse von Patienten mit besonderen Läsionsmustern die Ergebnisse der wenigen empirischen Untersuchungen auf wertvolle Weise. Die dritte Publikation der vorliegenden Arbeit (Becker, Jehna, Larsen et al., 2016) stellte den Fall eines Patienten mit einer fehlenden Hirnhemisphäre und einem späteren HGG vor und gab Einblicke in die kurzfristigen und langfristigen neuroplastischen Anpassungen. Bedingt durch eine seltene intrauterine Komplikation wurde der vorgestellte Patient mit einer rechten, jedoch ohne linke Hirnhemisphäre geboren (Hemihydranencephalie). Jahre später entwickelte sich ein HGG in seinem verbleibenden rechten Frontallappen. Eine Untersuchung zehn Jahre zuvor belegte durchschnittliche kognitive und sprachliche Funktionen, was auf eine sehr gute Anpassungsleistung seines Gehirns an das Fehlen einer ganzen Hemisphäre hinweist. Da die rechte Hemisphäre des Patienten in der Lage war, eine gute kognitive Funktionalität zu gewährleisten, kann sie als „funktionelle Kompensation durch homologe Areale“ für die linke Hemisphäre gewertet werden (in Anlehnung an Desmurget et al., 2007). Vorherige Befunde legen nahe, dass eine zusätzliche Beschädigung von Arealen, welche bereits verloren gegangene Funktionen voll kompensieren, mit hoher Wahrscheinlichkeit zu permanenten Funktionseinbußen bei Gliompatienten hervorrufen (Duffau, Capelle, Denvil, Sichez, Gatignol, Lopes et al., 2003). Dies führte zu der Annahme, dass aufgrund des Tumors nun mit schweren kognitiven Defiziten zu rechnen sei. Im Gegensatz dazu zeigte der Patient in einer neuropsychologischen Untersuchung lediglich

eine Verlangsamung, mittelgradige sprachliche Einschränkungen und leichte Einschränkungen kognitiver Basisleistungen. Als mögliche Erklärung hierfür diskutierten wir weitere neuroplastische Anpassungen seiner verbleibenden Hemisphäre, die durch das Tumorwachstum induziert wurden.

Das dargestellte Beispiel der immensen Anpassungsleistung des Gehirns und insbesondere der Sprachfunktionen an Läsionen, hat weitere Studien angeregt. Im Besonderen soll die Neuroplastizität von sprachassoziierten Kortexarealen und Faserbahnen in einer Langzeitstudie an Gliompatienten untersucht werden. Es sollen Faktoren, die zu einer guten neuroplastischen Anpassung beitragen, eruiert werden und ihre Bedeutung für die zukünftige Patientenbehandlung untersucht werden. Einen Ausblick auf die zu erwartenden Ergebnisse lieferten die Ergebnisse der ersten Pilotstudie dieses Projektes. Hier konnten Belege dafür gefunden werden, dass das Volumen des homologen rechtsseitigen Fasciculus arcuatus (FA) positiv mit einer besseren Sprachfähigkeit bei Patienten mit Gliomen in der linken, sprachdominanten Hemisphäre zusammenhängt (Jehna et al., in press). Ähnliche positive Einflüsse eines gut ausgeprägten homologen FA konnten Forkel und Kollegen (2014) für die Rehabilitation von Sprachfunktionen bei Schlaganfallpatienten dokumentieren. Sollten weitere Studien zu einem ähnlichen Ergebnis kommen, kann womöglich in Zukunft bei Patienten mit beidseitig angelegtem FA eine vollständigere Resektion von Tumorarealen der linken Hemisphäre als bisher erfolgen.

Nach einer umfassenden Evaluation des SMP-a sind analoge Studien zur Neuroplastizität des senso-motorischen Netzwerkes bei Gliompatienten geplant.

Die Ergebnisse der präsentierten Studien können in ein umfassendes Konzept der neuropsychologischen Diagnostik bei Patienten mit Gliomen integriert werden, welche einer Wachoperation unterzogen werden sollen. Die Vorteile einer präoperativen Diagnostik mit einer umfassenden neuropsychologischen Testbatterie liegen in der deutlich reduzierten Wahrscheinlichkeit, kognitive und senso-motorische Einschränkungen zu übersehen. Darüber hinaus erlaubt es die Untersuchungssituation einer umfassenden präoperativen neuropsychologischen Testung, wertvolle Informationen über die Eignung eines Patienten für eine Wachoperation zu erheben. Dies betrifft insbesondere die Verhaltensbeobachtung für Frustrationstoleranz und Compliance unter Anforderung. Darüber hinaus können, ausgehend vom kognitiven Profil des Patienten und seinen Bedürfnissen, individuell

Aufgaben für die Wachoperation ausgewählt werden. Das vorgeschlagene Instrument SMP-a kann in das Vorbereitungsgespräch für die Wachoperation integriert werden. Hierdurch kann eine standardisierte Erfassung der präoperativen senso-motorischen Funktionen, welche für alle weiteren Vergleiche herangezogen werden kann, gewährleistet werden. Des Weiteren kann das SMP-a als Grundlage für die Diskussion von möglichen intraoperativen Einschränkungen und Befürchtungen des Patienten genutzt werden. Dies liefert weitere hilfreiche Informationen bezüglich der emotionalen Stabilität des Patienten und unterstützt die Einschätzung der vermuteten intraoperativen Compliance. Während der Wachoperation kann das kortikale Mapping und das Monitoring der senso-motorischen Funktionen mit den individuell ausgesuchten Aufgaben des SMP-a standardisiert durchgeführt und protokolliert werden. Eine Ergänzung findet, sofern dies derzeit möglich ist, durch Aufgaben aus anderen Funktionsbereichen wie bspw. der Sprache statt. Postoperativ kann durch den Einsatz derselben diagnostischen Instrumente wie zum prä- und intraoperativen Zeitpunkt ein standardisierter Vergleich der Funktionen zu Evaluationszwecken erreicht werden. Ziel ist aus klinischer Sicht die Planung einer patientenorientierten Rehabilitation. Für Forschungszwecke steht die Evaluation des kurz- und langfristigen operativen Outcomes wie auch der Zusammenhänge zwischen strukturellen Veränderungen und kognitiven/senso-motorischen Funktionen an erster Stelle.

Zusammenfassend haben die skizzierten Studien Ergebnisse hervorgebracht, welche Klinikern bei der Auswahl von reliablen und validen Methoden für die umfassende Diagnostik von Gliompatienten bei Wachoperation Orientierung bieten. Darüber hinaus hat die vorliegende Arbeit die Bedeutung der umfassenden neuropsychologischen Diagnostik für wissenschaftliche Zwecke dargelegt und für mehrere Bereiche eine nach wie vor notwendige Standardisierung eruiert (bspw. die Evaluation von Wachoperationen im Langzeitverlauf). Es sind zukünftig vor allem Studien notwendig, welche die dargestellten Methoden, insbesondere das SMP-a, evaluieren und die Entwicklung von Leitlinien für den Einschluss und Ausschluss von Patienten für eine Wachoperation initiieren. Darüber hinaus sollten Forschungsbemühungen zur ökologischen Validität der Ergebnisse der neuropsychologischen Testergebnisse intensiviert werden, mit dem Ziel die subjektive Perspektive der Patienten auf ihre Einschränkungen und die damit verbundene Lebensqualität weiter in die neurochirurgische Behandlung zu integrieren. Dasselbe gilt für die Evaluation der Effektivität von (kognitiver) Rehabilitation bei Gliompatienten. Dies beinhaltet insbesondere die

Evaluation so genannter geplanter Defizite bei der Wachoperation. Zukünftiges Ziel sollte die Erstellung von zerebralen Karten mit Informationen über Resezierbarkeit und die wahrscheinliche Rehabilitierbarkeit eines bestimmten Hirnareals sein, welche in die routinemäßige Planung der chirurgischen Eingriffe integriert werden können.

7 REFERENCES

- Adelbratt, S., & Strang, P. (2000). Death anxiety in brain tumour patients and their spouses. *Palliative Medicine*, *14*(6), 499–507. doi:10.1191/026921600701536426
- Amelang, M., Zielinski, W., Fydrich, T., & Moosbrugger, H. (2002). *Psychologische Diagnostik und Intervention: Mit 35 Tabellen* (3., korrigierte, aktualisierte und überarb. Aufl. / unter Mitarb. von Thomas Fydrich.). *Springer-Lehrbuch*. Berlin [u.a.]: Springer.
- Armstrong, T. S., Bishof, A. M., Brown, P. D., Klein, M., Taphoorn, Martin J B, & Theodore-Okłota, C. (2016). Determining priority signs and symptoms for use as clinical outcomes assessments in trials including patients with malignant gliomas: Panel 1 Report. *Neuro-Oncology*, *18 Suppl 2*, ii1-ii12. doi:10.1093/neuonc/nov267
- Beauducel, A., & Leue, A. (2014). *Psychologische Diagnostik* (neue Ausg). *Bachelorstudium Psychologie*. Göttingen, Niedersachs: Hogrefe Verlag.
- Becker, J., Jehna, M., Larsen, N., Synowitz, M., & Hartwigsen, G. (2016). Glioblastoma in hemihydranencephaly: preoperative and postoperative language ability of the right hemisphere. *Acta neurochirurgica*, *158*(7), 1317–1323. doi:10.1007/s00701-016-2825-1
- Becker, J., Jehna, M., Steinmann, E., Mehdorn, H. M., Synowitz, M., & Hartwigsen, G. (2016). The sensory-motor profile awake-A new tool for pre-, intra-, and postoperative assessment of sensory-motor function. *Clinical Neurology and Neurosurgery*, *147*, 39–45. doi:10.1016/j.clineuro.2016.05.022
- Becker, J., Steinmann, E., Könemann, M., Gabske, S., Mehdorn, H. M., Synowitz, M., . . . Goebel, S. (2016). Cognitive screening in patients with intracranial tumors: validation of the BCSE. *Journal of neuro-oncology*, *127*(3), 559–567. doi:10.1007/s11060-016-2064-6
- Behrens, T. E. J., Brady, J. M., Clare, S., Jenkinson, M., Johansen-Berg, H., Matthews, P. M., . . . Woolrich, M. W. (2003). Characterization and propagation of uncertainty in diffusion-weighted MR imaging. *Magnetic resonance in medicine*, *50*(5), 1077–1088. doi:10.1002/mrm.10609
- Bello, L., Castellano, A., Fava, E., Casaceli, G., Riva, M., & Falini, A. (2011). Preoperative Diffuson Tensor Imaging (DTI): contribution to surgical planning and validation by intraoperative electrostimulation. In H. Duffau (Ed.), *Brain mapping. From neural basis of cognition to surgical applications*. Vienna, New York: Springer.
- Berger, M. S., & Ojemann, G. A. (1992). Intraoperative brain mapping techniques in neuro-oncology. *Stereotactic and functional neurosurgery*, *58*(1-4), 153–161.
- Berlit, P. (Ed.). (2006). *Klinische Neurologie* (2., aktualisierte Aufl). Heidelberg: Springer Medizin.
- Bernstein, I. H., Lacritz, L., Barlow, C. E., Weiner, M. F., & DeFina, L. F. (2011). Psychometric evaluation of the Montreal Cognitive Assessment (MoCA) in three diverse samples. *The Clinical Neuropsychologist*, *25*(1), 119–126. doi:10.1080/13854046.2010.533196
- Bosma, I., Vos, M. J., Heimans, J. J., Taphoorn, M. J. B., Aaronson, N. K. P. T. J., van der Ploeg, H. M., . . . Klein, M. (2007). The course of neurocognitive functioning in high-grade glioma patients. *Neuro-Oncology*, *9*, 53–62.
- Bunevicius, A., Tamasauskas, S., Deltuva, V., Tamasauskas, A., Radziunas, A., & Bunevicius, R. (2014). Predictors of health-related quality of life in neurosurgical brain tumor patients: focus on patient-centered perspective. *Acta neurochirurgica*, *156*(2), 367–374. doi:10.1007/s00701-013-1930-7

- Bürgel, U., Mädler, B., Honey, C. R., Thron, A., Gilsbach, J., & Coenen, V. A. (2009). Fiber tracking with distinct software tools results in a clear diversity in anatomical fiber tract portrayal. *Central European neurosurgery*, *70*(1), 27–35. doi:10.1055/s-0028-1087212
- Campanella, F., Fabbro, F., Ius, T., Shallice, T., & Skrap, M. (2015). Acute effects of surgery on emotion and personality of brain tumor patients: surgery impact, histological aspects, and recovery. *Neuro-Oncology*, *17*(8), 1121–1131. doi:10.1093/neuonc/nov065
- Catani, M., Howard, R. J., Pajevic, S., & Jones, D. K. (2002). Virtual in Vivo Interactive Dissection of White Matter Fasciculi in the Human Brain. *NeuroImage*, *17*(1), 77–94. doi:10.1006/nimg.2002.1136
- Catani, M., & Thiebaut de Schotten, M. (2008). A diffusion tensor imaging tractography atlas for virtual in vivo dissections. *Cortex; a journal devoted to the study of the nervous system and behavior*, *44*(8), 1105–1132. doi:10.1016/j.cortex.2008.05.004
- Chacko, A. G., Thomas, S. G., Babu, K. S., Daniel, R. T., Chacko, G., Prabhu, K., . . . Korula, G. (2013). Awake craniotomy and electrophysiological mapping for eloquent area tumours. *Clinical Neurology and Neurosurgery*, *115*(3), 329–334. doi:10.1016/j.clineuro.2012.10.022
- Chaytor, N., & Schmitter-Edgecombe, M. (2003). The ecological validity of neuropsychological tests: a review of the literature on everyday cognitive skills. *Neuropsychology review*, *13*(4), 181–197.
- Cheng, J.-x., Zhang, X., & Liu, B.-L. (2009). Health-related quality of life in patients with high-grade glioma. *Neuro-Oncology*, *11*(1), 41–50. doi:10.1215/15228517-2008-050
- Coello, A. F., Moritz-Gasser, S., Martino, J., Martinoni, M., Matsuda, R., & Duffau, H. (2013). Selection of intraoperative tasks for awake mapping based on relationships between tumor location and functional networks. *Journal of Neurosurgery*, *119*(6), 1380–1394. doi:10.3171/2013.6.JNS122470
- Corina, D. P., Loudermilk, B. C., Detwiler, L., Martin, R. F., Brinkley, J. F., & Ojemann, G. (2010). Analysis of naming errors during cortical stimulation mapping: implications for models of language representation. *Brain and language*, *115*(2), 101–112. doi:10.1016/j.bandl.2010.04.001.
- Correa, D. D., DeAngelis, L. M., Shi, W., Thaler, H. T., Lin, M., & Abrey, L. E. (2007). Cognitive functions in low-grade gliomas: disease and treatment effects. *Journal of neuro-oncology*, *81*(2), 175–184. doi:10.1007/s11060-006-9212-3
- Correa, D. D., Shi, W., Thaler, H. T., Cheung, A. M., DeAngelis, L. M., & Abrey, L. E. (2008). Longitudinal cognitive follow-up in low grade gliomas. *Journal of neuro-oncology*, *86*(3), 321–327. doi:10.1007/s11060-007-9474-4
- De Witte, E., Satoer, D., Colle, H., Robert, E., Visch-Brink, E., & Mariën, P. (2015). Subcortical language and non-language mapping in awake brain surgery: the use of multimodal tests. *Acta neurochirurgica*, *157*(4), 577–588. doi:10.1007/s00701-014-2317-0
- De Witte, E., Satoer, D., Robert, E., Colle, H., Verheyen, S., Visch-Brink, E., & Mariën, P. (2015). The Dutch Linguistic Intraoperative Protocol: A valid linguistic approach to awake brain surgery. *Brain and language*, *140*, 35–48. doi:10.1016/j.bandl.2014.10.011
- De Witte, E., & Mariën, P. (2013). The neurolinguistic approach to awake surgery reviewed. *Clinical Neurology and Neurosurgery*, *115*(2), 127–145. doi:10.1016/j.clineuro.2012.09.015

- Desmurget, M., Bonnetblanc, F., & Duffau, H. (2007). Contrasting acute and slow-growing lesions: a new door to brain plasticity. *Brain : a journal of neurology*, *130*(Pt 4), 898–914. doi:10.1093/brain/awl300
- Díaz, J. L., Barreto, P., Gallego, J. M., Barbero, J., Bayés, R., & Barcia, J. A. (2009). Proper information during the surgical decision-making process lowers the anxiety of patients with high-grade gliomas. *Acta neurochirurgica*, *151*(4), 357–362. doi:10.1007/s00701-009-0195-7
- Duffau, H., Capelle, L., Denvil, D., Sichez, N., Gatignol, P., Lopes, M., . . . van Effenterre, R. (2003). Functional recovery after surgical resection of low grade gliomas in eloquent brain: hypothesis of brain compensation. *Journal of neurology, neurosurgery, and psychiatry*, *74*(7), 901–907.
- Duffau, H., Denvil, D., Lopes, M., Gasparini, F., Cohen, L., Capelle, L., & van Effenterre, R. (2002). Intraoperative mapping of the cortical areas involved in multiplication and subtraction: an electrostimulation study in a patient with a left parietal glioma. *Journal of neurology, neurosurgery, and psychiatry*, *73*(6), 733–738.
- Duffau, H. (2005). Lessons from brain mapping in surgery for low-grade glioma: insights into associations between tumour and brain plasticity. *The Lancet Neurology*, *4*(8), 476–486. doi:10.1016/S1474-4422(05)70140-X
- Duffau, H. (2009a). Does post-lesional subcortical plasticity exist in the human brain? *Neuroscience research*, *65*(2), 131–135. doi:10.1016/j.neures.2009.07.002
- Duffau, H. (2009b). Surgery of low-grade gliomas: towards a 'functional neurooncology'. *Current opinion in oncology*, *21*(6), 543–549. doi:10.1097/CCO.0b013e3283305996
- Duffau, H. (2010). Awake Surgery for Nonlanguage Mapping. *Neurosurgery*, *66*(3), 523–529. doi:10.1227/01.NEU.0000364996.97762.73
- Duffau, H. (2011a). Awake mapping and tumor surgery. In H. Duffau (Ed.), *Brain mapping. From neural basis of cognition to surgical applications* (pp. 305–318). Vienna, New York: Springer.
- Duffau, H. (Ed.). (2011b). *Brain mapping: From neural basis of cognition to surgical applications*. Vienna, New York: Springer.
- Duffau, H. (2011c). Brain plasticity: a new concept in neuroscience. In H. Duffau (Ed.), *Brain mapping. From neural basis of cognition to surgical applications* (pp. 349–360). Vienna, New York: Springer.
- Duffau, H. (2011d). Indications of awake mapping and selection of intraoperative tasks. In H. Duffau (Ed.), *Brain mapping. From neural basis of cognition to surgical applications* (pp. 321–334). Vienna, New York: Springer.
- Duffau, H. (2013). Cognitive assessment in glioma patients. *Journal of Neurosurgery*, *119*(5), 1348–1349. doi:10.3171/2012.2.JNS112372.
- Duffau, H. (2014). Toward an "active" cognitive assessment in patients with diffuse low-grade glioma. *World neurosurgery*, *82*(1-2), e129-31. doi:10.1016/j.wneu.2014.03.023
- Duffau, H., Capelle, L., Denvil, D., Sichez, N., Gatignol, P., Taillandier, L., . . . van Effenterre, R. (2003). Usefulness of intraoperative electrical subcortical mapping during surgery for low-grade gliomas located within eloquent brain regions: functional results in a consecutive series of 103 patients. *Journal of Neurosurgery*, *98*(4), 764–778. doi:10.3171/jns.2003.98.4.0764

- Duffau, H., & Mandonnet, E. (2013). The "onco-functional balance" in surgery for diffuse low-grade glioma: integrating the extent of resection with quality of life. *Acta neurochirurgica*, 155(6), 951–957. doi:10.1007/s00701-013-1653-9
- Fawcett, T. (2006). An introduction to ROC analysis. *Pattern Recognition Letters*, 27(8), 861–874. doi:10.1016/j.patrec.2005.10.010
- Folstein, M. (1998). Mini-mental and son. *International journal of geriatric psychiatry*, 13(5), 290–294. Retrieved from <http://www.ncbi.nlm.nih.gov/pubmed/9658261>
- Folstein, M. F., Folstein, S. E., & McHugh, P. R. (1975). "Mini-Mental State" A practical method for grading the cognitive state of patients for the clinician. *Journal of Psychiatric Research*, 12(3), 189–198. doi:10.1016/0022-3956(75)90026-6
- Ford, E., Catt, S., Chalmers, A., & Fallowfield, L. (2012). Systematic review of supportive care needs in patients with primary malignant brain tumors. *Neuro-Oncology*, 14(4), 392–404. doi:10.1093/neuonc/nor229
- Forkel, S. J., Thiebaut de Schotten, M., Dell'acqua, F., Kalra, L., Murphy, Declan G M, Williams, Steven C R, & Catani, M. (2014). Anatomical predictors of aphasia recovery: a tractography study of bilateral perisylvian language networks. *Brain : a journal of neurology*, 137(Pt 7), 2027–2039. doi:10.1093/brain/awu113
- Frommelt, P. (Ed.). (2010). *NeuroRehabilitation: Ein Praxisbuch für interdisziplinäre Teams ; mit 92 Tabellen*. Berlin, Heidelberg: Springer.
- Guggel, S., & Sturm, W. (2005). Leitlinien der Gesellschaft für Neuropsychologie (GNP) für neuropsychologische Diagnostik und Therapie. *Zeitschrift für Neuropsychologie*, 16(4), 175–199. doi:10.1024/1016-264X.16.4.175
- Giovagnoli, A. R. (2005). Facets and determinants of quality of life in patients with recurrent high grade glioma. *Journal of Neurology, Neurosurgery & Psychiatry*, 76(4), 562–568. doi:10.1136/jnnp.2004.036186
- Giovagnoli, A. R. (2012). Investigation of cognitive impairments in people with brain tumors. *Journal of neuro-oncology*, 108(2), 277–283. doi:10.1007/s11060-012-0815-6
- Giussani, C., Roux, F.-E., Ojemann, J., Sganzerla, E. P., Pirillo, D., & Papagno, C. (2010). Is preoperative functional magnetic resonance imaging reliable for language areas mapping in brain tumor surgery? Review of language functional magnetic resonance imaging and direct cortical stimulation correlation studies. *Neurosurgery*, 66(1), 113–120. doi:10.1227/01.NEU.0000360392.15450.C9
- Goebel, S., Kaup, L., Wiesner, C. D., & Mehdorn, H. M. (2013). Affective state and cognitive functioning in patients with intracranial tumors: validity of the neuropsychological baseline assessment. *Psycho-oncology*, 22(6), 1319–1327. doi:10.1002/pon.3142
- Goebel, S., Strenge, H., & Mehdorn, H. M. (2012). Acute stress in patients with brain cancer during primary care. *Supportive care in cancer : official journal of the Multinational Association of Supportive Care in Cancer*, 20(7), 1425–1434. doi:10.1007/s00520-011-1225-6
- Goldenberg, G. (2007). *Neuropsychologie (4): Grundlagen, Klinik, Rehabilitation* (4., aktualisierte und erweiterte Auflage): Urban & Fischer.
- Habets, E. J. J., Kloet, A., Walchenbach, R., Vecht, C. J., Klein, M., & Taphoorn, M. J. B. (2014). Tumour and surgery effects on cognitive functioning in high-grade glioma patients. *Acta neurochirurgica*, 156(8), 1451–1459. doi:10.1007/s00701-014-2115-8

- Hahn, C., Dunn, R., Logue, P., King, J., Edwards, C., & Halperin, E. (2003). Prospective study of neuropsychologic testing and quality-of-life assessment of adults with primary malignant brain tumors. *International Journal of Radiation Oncology*Biophysics*, *55*(4), 992–999. doi:10.1016/S0360-3016(02)04205-0
- Hartje, W., & Poeck, K. (Eds.). (2006). *Klinische Neuropsychologie: 29 Tabellen* (6., unveränd. Aufl.). Stuttgart [u.a.]: Thieme.
- Ius, T., Angelini, E., Thiebaut de Schotten, M., Mandonnet, E., & Duffau, H. (2011). Evidence for potentials and limitations of brain plasticity using an atlas of functional resectability of WHO grade II gliomas: towards a "minimal common brain". *NeuroImage*, *56*(3), 992–1000. doi:10.1016/j.neuroimage.2011.03.022
- Jehna, M., Becker, J., Zaar, K., Campe, G. von, Reishofer, G., Payer, F., . . . Deutschmann, H. (in press). Symmetry of the arcuate fasciculus impacts on language performance of patients with brain tumors in the language-dominant hemisphere. *Journal of Neurosurgery*, 2016.
- Kessler, J., Denzler, P., & Markowitsch, H. J. (1990). *Der Mini-Mental-Status-Test*. Weinheim: Beltz.
- Khan, F., Amatya, B., Ng, L., Drummond, K., & Galea, M. (2015). Multidisciplinary rehabilitation after primary brain tumour treatment. *The Cochrane database of systematic reviews*, (8), CD009509. doi:10.1002/14651858.CD009509.pub3
- Klein, M., Heimans, J. J., Aaronson, N. K., van der Ploeg, H. M., Grit, J., Muller, M., . . . Taphoorn, M. J. (2002). Effect of radiotherapy and other treatment-related factors on mid-term to long-term cognitive sequelae in low-grade gliomas: a comparative study. *The Lancet*, *360*(9343), 1361–1368. doi:10.1016/S0140-6736(02)11398-5
- Klein, M., Duffau, H., & Witt Hamer, P. C. (2012). Cognition and resective surgery for diffuse infiltrative glioma: an overview. *Journal of neuro-oncology*, *108*(2), 309–318. doi:10.1007/s11060-012-0811-x
- Klein, M., Engelberts, Nadine H J, van der Ploeg, Henk M, Kasteleijn-Nolst Trenité, Dorotheé G A, Aaronson, N. K., Taphoorn, Martin J B, . . . Heimans, J. J. (2003). Epilepsy in low-grade gliomas: the impact on cognitive function and quality of life. *Annals of neurology*, *54*(4), 514–520. doi:10.1002/ana.10712
- Klein, M., Taphoorn, M. J. B., Heimans, J. J., van der Ploeg, H. M., Vandertop, W. P., Smit, E. F., . . . Aaronson, N. K. (2001). Neurobehavioral status and health-related quality of life in newly diagnosed high-grade glioma patients. *Journal of Clinical Oncology*, *19*, 4037–4047.
- Kraemer, H. C. (1992). *Evaluating medical tests: Objective and quantitative guidelines*. Newbury Park, Calif.: Sage Publications.
- Lageman, S. K., Cerhan, J. H., Locke, D. E. C., Anderson, S. K., Wu, W., & Brown, P. D. (2010). Comparing neuropsychological tasks to optimize brief cognitive batteries for brain tumor clinical trials. *Journal of neuro-oncology*, *96*(2), 271–276. doi:10.1007/s11060-009-9960-y
- Le Rhun, E., Delbeuck, X., Devos, P., Pasquier, F., & Dubois, F. (2009). Troubles cognitifs dans les gliomes de grade II et III de l'adulte: À propos d'une série de 15 patients [Cognitive disorders and adult grade II and III gliomas: analysis of a series of 15 patients]. *Neuro-Chirurgie*, *55*(3), 303–308. doi:10.1016/j.neuchi.2008.08.111
- Lezak, M. D. (Ed.). (2012). *Neuropsychological assessment* (5th ed). Oxford, New York: Oxford University Press.

- Li, P., Legault, J., & Litcofsky, K. A. (2014). Neuroplasticity as a function of second language learning: anatomical changes in the human brain. *Cortex; a journal devoted to the study of the nervous system and behavior*, *58*, 301–324. doi:10.1016/j.cortex.2014.05.001
- Lienert, G. A., & Raatz, U. (1998). *Testaufbau und Testanalyse* (6. Aufl., Studienausg). [Weinheim]: Beltz Verlagsgruppe.
- Louis, D. N., Ohgaki, H., Wiestler, O. D., Cavenee, W. K., Burger, P. C., Jouvett, A., . . . Kleihues, P. (2007). The 2007 WHO classification of tumours of the central nervous system. *Acta neuropathologica*, *114*(2), 97–109. doi:10.1007/s00401-007-0243-4
- Malloy, P. F., Cummings, J. L., Coffey, C. E., Duffy, J., Fink, M., Lauterbach, E. C., . . . Salloway, S. (1997). Cognitive screening instruments in neuropsychiatry: a report of the Committee on Research of the American Neuropsychiatric Association. *The Journal of Neuropsychiatry and Clinical Neurosciences*, *9*(2), 189–197.
- Mandonnet, E. (2011). Intraoperative electrical mapping: advances, limitations and perspectives. In H. Duffau (Ed.), *Brain mapping. From neural basis of cognition to surgical applications* (pp. 101–108). Vienna, New York: Springer.
- Margraf, J., Maier, W., & Pschyrembel, W. (Eds.). (2012). *Pschyrembel Psychiatrie, klinische Psychologie, Psychotherapie* (2., überarb. Aufl.). Berlin, Boston, Mass.: De Gruyter.
- Martino, J., Taillandier, L., Moritz-Gasser, S., Gatignol, P., & Duffau, H. (2009). Re-operation is a safe and effective therapeutic strategy in recurrent WHO grade II gliomas within eloquent areas. *Acta neurochirurgica*, *151*(5), 427-36; discussion 436. doi:10.1007/s00701-009-0232-6
- Meskal, I., Gehring, K., Rutten, G.-J. M., & Sitskoorn, M. M. (2016). Cognitive functioning in meningioma patients: a systematic review. *Journal of neuro-oncology*. doi:10.1007/s11060-016-2115-z
- Meyers, C. A., & Brown, P. D. (2006). Role and relevance of neurocognitive assessment in clinical trials of patients with CNS tumors. *Journal of Clinical Oncology*, *24*(8), 1305–1309. doi:10.1200/JCO.2005.04.6086
- Meyers, C. A., Hess, K. R., Yung, W. K., & Levin, V. A. (2000). Cognitive function as a predictor of survival in patients with recurrent malignant glioma. *Journal of clinical oncology : official journal of the American Society of Clinical Oncology*, *18*(3), 646–650.
- Meyers, C. A., Rock, E. P., & Fine, H. A. (2012). Refining endpoints in brain tumor clinical trials. *Journal of neuro-oncology*, *108*(2), 227–230. doi:10.1007/s11060-012-0813-8
- Meyers, C. A., & Wefel, J. S. (2003). The use of the Mini-Mental State Examination to assess cognitive functioning in cancer trials: No ifs, ands, buts, or sensitivity. *Journal of Clinical Oncology*, *21*(19), 3557–3558.
- Moosbrugger, H., & Kelava, A. (2012a). Qualitätsanforderungen an einen psychologischen Test (Testgütekriterien). In H. Moosbrugger & A. Kelava (Eds.), *Testtheorie und Fragebogenkonstruktion* (2nd ed., pp. 8–26). Berlin, Heidelberg: Springer-Verlag Berlin Heidelberg.
- Moosbrugger, H., & Kelava, A. (Eds.). (2012b). *Testtheorie und Fragebogenkonstruktion* (2., aktualisierte und überarbeitete Auflage). Berlin, Heidelberg: Springer-Verlag Berlin Heidelberg.
- Moritz-Gasser, S., Herbet, G., Maldonado, I. L., & Duffau, H. (2012). Lexical access speed is significantly correlated with the return to professional activities after awake surgery for

- low-grade gliomas. *Journal of neuro-oncology*, 107(3), 633–641. doi:10.1007/s11060-011-0789-9
- Münste, T. F., & Herrmann, M. (2007). Klinische Neurologie. In W. Sturm, M. Herrmann, & T. F. Münste (Eds.), *Lehrbuch der klinischen Neuropsychologie* (2nd ed., pp. 131–154). Heidelberg: Spektrum Akad. Verl.
- Murray, K. J., Scott, C., Zachariah, B., Michalski, J. M., Demans, W., Vora, N. L., . . . Movsas, B. (2000). Importance of the Mini-Mental Status Examination in the treatment of patients with brain metastases: A report from the radiation therapy oncology group protocol 91-04. *Journal of Radiation Oncology, Biology, Physics*, 48, 59–64.
- Nabavi, A., Goebel, S., Doerner, L., Warneke, N., Ulmer, S., & Mehdorn, M. (2009). Awake craniotomy and intraoperative magnetic resonance imaging: patient selection, preparation, and technique. *Topics in magnetic resonance imaging : TMRI*, 19(4), 191–196. doi:10.1097/RMR.0b013e3181963b46
- Nasreddine, Z. S., Phillips, N. A., Bedirian, V., Charbonneau, S., Whitehead, V., Collin, I., . . . Chertkow, H. (2005). The Montreal Cognitive Assessment, MoCA: A brief screening tool for mild cognitive impairment. *Journal of the American Geriatrics Society*, 53(4), 695–699.
- Nossek, E., Matot, I., Shahar, T., Barzilai, O., Rapoport, Y., Gonen, T., . . . Ram, Z. (2013). Failed awake craniotomy: a retrospective analysis in 424 patients undergoing craniotomy for brain tumor. *Journal of Neurosurgery*, 118(2), 243–249. doi:10.3171/2012.10.JNS12511
- Ohgaki, H., & Kleihues, P. (2009). Genetic alterations and signaling pathways in the evolution of gliomas. *Cancer science*, 100(12), 2235–2241. doi:10.1111/j.1349-7006.2009.01308.x
- Olson, R. A., Iverson, G. L., Parkinson, M., Carolan, H., Ellwood, A., & McKenzie, M. Investigation of cognitive screening measures in patients with brain tumors: Diagnostic accuracy and correlation with quality of life.: Meeting Abstract e13000. *Journal of Clinical Oncology*, 2009(27).
- Olson, R. A., Chhanabhai, T., & McKenzie, M. (2008). Feasibility study of the Montreal Cognitive Assessment (MoCA) in patients with brain metastases. *Supportive Care in Cancer*, 16(11), 1273–1278. doi:10.1007/s00520-008-0431-3
- Olson, R. A., Iverson, G. L., Carolan, H., Parkinson, M., Brooks, B. L., & McKenzie, M. (2011). Prospective comparison of two cognitive screening tests: Diagnostic accuracy and correlation with community integration and quality of life. *Journal of Neurooncology*, 105, 337–344.
- Olson, R. A., Tyldesley, S., Carolan, H., Parkinson, M., Chhanabhai, T., & McKenzie, M. (2011). Prospective comparison of the prognostic utility of the Mini Mental State Examination and the Montreal Cognitive Assessment in patients with brain metastases. *Supportive Care in Cancer*, 19(11), 1849–1855. doi:10.1007/s00520-010-1028-1
- Ownsworth, T., Hawkes, A., Steginga, S., Walker, D., & Shum, D. (2009). A biopsychosocial perspective on adjustment and quality of life following brain tumor: a systematic evaluation of the literature. *Disability and rehabilitation*, 31(13), 1038–1055. doi:10.1080/09638280802509538
- Park, S. H., Goo, J. M., & Jo, C.-H. (2004). Receiver operating characteristic (ROC) curve: practical review for radiologists. *Korean journal of radiology*, 5(1), 11–18. doi:10.3348/kjr.2004.5.1.11

- Patel, R. R., & Mehta, M. P. (2007). Targeted therapy for brain metastases: Improving the therapeutic ratio. *Clinical Cancer Research*, 13(6), 1675–1683. doi:10.1158/1078-0432.CCR-06-2489
- Penfield, W., & Boldrey, E. (1937). Somatic motor and sensory representation in the cerebral cortex of man as studied by electrical stimulation. *Brain*, 60(4), 389–443. doi:10.1093/brain/60.4.389
- Perks, A., Chakravarti, S., & Manninen, P. (2009). Preoperative anxiety in neurosurgical patients. *Journal of neurosurgical anesthesiology*, 21(2), 127–130. doi:10.1097/ANA.0b013e31819a6ca3
- Petermann, F., & Lepach, A. C. (Eds.). (2012). *Always learning. Wechsler Memory Scale-Fourth Edition (WMS-IV). Manual zur Durchführung und Auswertung*. (4. Aufl). Frankfurt: Pearson.
- Picht, T., Kombos, T., Gramm, H. J., Brock, M., & Suess, O. (2006). Multimodal protocol for awake craniotomy in language cortex tumour surgery. *Acta neurochirurgica*, 148(2), 127–37; discussion 137–8. doi:10.1007/s00701-005-0706-0
- Pierpaoli, C., Jezzard, P., Basser, P. J., Barnett, A., & Di Chiro, G. (1996). Diffusion tensor MR imaging of the human brain. *Radiology*, 201(3), 637–648. doi:10.1148/radiology.201.3.8939209
- Poeck, K., & Hacke, W. (2006). *Neurologie: Mit 85 Tabellen ; [neue Approbationsordnung]* (12., aktualisierte und erw. Aufl.). *Springer-Lehrbuch*. Berlin: Springer.
- Poeck, K., & Hacke, W. (1998). *Neurologie: Mit 74 Tabellen* (10., vollst. überarb. und größtenteils neu verf. Aufl.). *Springer-Lehrbuch*. Berlin [u.a.]: Springer.
- Reijneveld, J. C., Sitskoorn, M. M., Klein, M., Nuyen, J., & Taphoorn, M. J. (2001). Cognitive status and quality of life in patients with suspected versus proven low-grade gliomas. *Neurology*, 56(5), 618–623.
- Robert Koch-Institut / Gesellschaft der epidemiologischen Krebsregister in Deutschland e.V. (Ed.). (2013). *Krebs in Deutschland 2009/2010: Häufigkeiten und Trends*. (9th ed.).
- Robles, S. G., Gatignol, P., Lehericy, S., & Duffau, H. (2008). Long-term brain plasticity allowing a multistage surgical approach to World Health Organization Grade II gliomas in eloquent areas. *Journal of Neurosurgery*, 109(4), 615–624. doi:10.3171/JNS/2008/109/10/0615
- Rofes, A., Aguiar, V. de, & Miceli, G. (2015). A minimal standardization setting for language mapping tests: an Italian example. *Neurological sciences : official journal of the Italian Neurological Society and of the Italian Society of Clinical Neurophysiology*, 36(7), 1113–1119. doi:10.1007/s10072-015-2192-3
- Rofes, A., & Miceli, G. (2014). Language mapping with verbs and sentences in awake surgery: a review. *Neuropsychology review*, 24(2), 185–199. doi:10.1007/s11065-014-9258-5
- Rorden, C., Fridriksson, J., & Karnath, H.-O. (2009). An evaluation of traditional and novel tools for lesion behavior mapping. *NeuroImage*, 44(4), 1355–1362. doi:10.1016/j.neuroimage.2008.09.031
- Röther, J. (2006). Hirntumoren. In P. Berlit (Ed.), *Klinische Neurologie* (2nd ed., pp. 630–664). Heidelberg: Springer Medizin.
- Rutten, G.-J. M., & Ramsey, N. F. (2011). Functional neuroimaging in neurosurgical practice. In H. Duffau (Ed.), *Brain mapping. From neural basis of cognition to surgical applications* (pp. 207–227). Vienna, New York: Springer.

- Santini, B., Talacchi, A., Squintani, G., Casagrande, F., Capasso, R., & Miceli, G. (2012). Cognitive outcome after awake surgery for tumors in language areas. *Journal of neuro-oncology*, *108*(2), 319–326. doi:10.1007/s11060-012-0817-4
- Santini, B., Talacchi, A., Casagrande, F., Casartelli, M., Savazzi, S., Procaccio, F., & Gerosa, M. (2012). Eligibility criteria and psychological profiles in patient candidates for awake craniotomy: a pilot study. *Journal of neurosurgical anesthesiology*, *24*(3), 209–216. doi:10.1097/ANA.0b013e3182464aec
- Satoer, D., Vork, J., Visch-Brink, E., Smits, M., Dirven, C., & Vincent, A. (2012). Cognitive functioning early after surgery of gliomas in eloquent areas. *Journal of Neurosurgery*, *117*, 831–838.
- Satoer, D., Visch-Brink, E., Dirven, C., & Vincent, A. (2016). Glioma surgery in eloquent areas: can we preserve cognition? *Acta neurochirurgica*, *158*(1), 35–50. doi:10.1007/s00701-015-2601-7
- Satoer, D., Visch-Brink, E., Smits, M., Kloet, A., Looman, C., Dirven, C., & Vincent, A. (2014). Long-term evaluation of cognition after glioma surgery in eloquent areas. *Journal of neuro-oncology*, *116*(1), 153–160. doi:10.1007/s11060-013-1275-3
- Scheibel, R. S., Meyers, C. A., & Levin, V. A. (1996). Cognitive dysfunction following surgery for intracerebral glioma: influence of histopathology, lesion location, and treatment. *Journal of neuro-oncology*, *30*(1), 61–69.
- Schnider, A. (2008). *Verhaltensneurologie: Die neurologische Seite der Neuropsychologie. Eine Einführung für Ärzte und Psychologen* (2nd ed.). Stuttgart: Thieme.
- Scotland, J. L., Whittle, I. R., & Deary, I. J. (2012). Cognitive functioning in newly presenting patients with supratentorial intracranial tumors: Is there a role for inspection time? *Neuro-Oncology*, *14*, 360–367.
- Shaw, E., Arusell, R., Scheithauer, B., O'Fallon, J., O'Neill, B., Dinapoli, R., . . . Abrams, R. (2002). Prospective randomized trial of low- versus high-dose radiation therapy in adults with supratentorial low-grade glioma: initial report of a North Central Cancer Treatment Group/Radiation Therapy Oncology Group/Eastern Cooperative Oncology Group study. *Journal of clinical oncology : official journal of the American Society of Clinical Oncology*, *20*(9), 2267–2276.
- Sherman, E. M. S., Brooks, B. L., Iverson, G. L., Slick, D. J., & Strauss, E. (2011). Reliability and Validity in Neuropsychology. In M. R. Schoenberg & J. G. Scott (Eds.), *The little black book of neuropsychology. A syndrome-based approach* (pp. 873–892). New York, London: Springer.
- Shibamoto, Y., Baba, F., Oda, K., Hayashi, S., Kokubo, M., Ishihara, S.-I., . . . Koizumi, M. (2008). Incidence of brain atrophy and decline in Mini-Mental State Examination score after whole-brain radiotherapy in patients with brain metastases: A prospective study. *International Journal of Radiation Oncology*Biophysics*Physics*, *72*(4), 1168–1173.
- Shields, L., & Choucair, A. K. (2014). Management of low-grade gliomas: a review of patient-perceived quality of life and neurocognitive outcome. *World neurosurgery*, *82*(1-2), e299-309. doi:10.1016/j.wneu.2014.02.033
- Smith, T., Gildeh, N., & Holmes, C. (2007). The Montreal Cognitive Assessment: Validity and utility in a memory clinic setting. *Canadian Journal of Psychiatry*, *52*, 329–332.
- Snyder, P. J., & Whitaker, H. A. (2013). Neurologic heuristics and artistic whimsy: the cerebral cartography of wilder penfield. *Journal of the history of the neurosciences*, *22*(3), 277–291. doi:10.1080/0964704X.2012.757965

- Strauss, E., Sherman, E. M. S., Slick, D. J., & Spreen, O. (2006). Psychometrics in Neuropsychological assessment. In E. Strauss, E. M. S. Sherman, & O. Spreen (Eds.), *A compendium of neuropsychological tests. Administration, norms, and commentary* (3rd ed., pp. 3–31). Oxford, New York: Oxford University Press.
- Sturm, W., Herrmann, M., & Münte, T. F. (Eds.). (2007). *Lehrbuch der klinischen Neuropsychologie* (2. Aufl). Heidelberg: Spektrum Akad. Verl.
- Talacchi, A., d'Avella, D., Denaro, L., Santini, B., Meneghelli, P., Savazzi, S., & Gerosa, M. (2012). Cognitive outcome as part and parcel of clinical outcome in brain tumor surgery. *Journal of neuro-oncology*, *108*(2), 327–332. doi:10.1007/s11060-012-0818-3
- Talacchi, A., Santini, B., Casagrande, F., Alessandrini, F., Zoccatelli, G., & Squintani, G. M. (2013). Awake surgery between art and science. Part I: clinical and operative settings. [Awake surgery between art and science. Part I: clinical and operative settings]. *Functional neurology*, *28*(3), 205–221.
- Talacchi, A., Santini, B., Casartelli, M., Monti, A., Capasso, R., & Miceli, G. (2013). Awake surgery between art and science. Part II: language and cognitive mapping. [Awake surgery between art and science. Part II: language and cognitive mapping]. *Functional neurology*, *28*(3), 223–229.
- Talacchi, A., Santini, B., Savazzi, S., & Gerosa, M. (2011). Cognitive effects of tumour and surgical treatment in glioma patients. *Journal of neuro-oncology*, *103*(3), 541–549. doi:10.1007/s11060-010-0417-0
- Talacchi, A., Taphoorn, M., & Miceli, G. (2012). Reconsidering outcomes that matter to patients. *Journal of neuro-oncology*, *108*(2), 219–220. doi:10.1007/s11060-012-0830-7
- Taphoorn, M. J. B., & Klein, M. (2004). Cognitive deficits in adult patients with brain tumours. *The Lancet Neurology*, *3*(3), 159–168. doi:10.1016/S1474-4422(04)00680-5
- Thomas, C., & Baker, C. I. (2013). Teaching an adult brain new tricks: a critical review of evidence for training-dependent structural plasticity in humans. *NeuroImage*, *73*, 225–236. doi:10.1016/j.neuroimage.2012.03.069
- Tombaugh, T. (2004). Trail Making Test A and B: Normative data stratified by age and education. *Archives of Clinical Neuropsychology*, *19*(2), 203–214. doi:10.1016/S0887-6177(03)00039-8
- Tombaugh, T. N., & McIntyre, N. J. (1992). The Mini-Mental State Examination: A comprehensive review. *Journal of the American Geriatrics Society*, *40*, 922–935.
- Tucha, O., Smely, C., Preier, M., Becker, G., Paul, G. M., & Lange, K. W. (2003). Preoperative and postoperative cognitive functioning in patients with frontal meningiomas. *Journal of Neurosurgery*, *98*, 21–31.
- Tucha, O., Smely, C., Preier, M., & Lange, K. W. (2000). Cognitive deficits before treatment among patients with brain tumors. *Neurosurgery*, *47*(2), 324–33; discussion 333–4.
- Urbina, S. (Ed.). (2004). *Essentials of behavioral science series. Essentials of psychological testing*. Hoboken, N.J.: John Wiley & Sons.
- van Loon, E., Heijenbrok-Kal, M. H., van Loon, Wouter S, van den Bent, Martin J, Vincent, Arnaud J P E, Koning, I. de, & Ribbers, G. M. (2015). Assessment methods and prevalence of cognitive dysfunction in patients with low-grade glioma: A systematic review. *Journal of Rehabilitation Medicine*, *47*(6), 481–488. doi:10.2340/16501977-1975
- Wager, M., Du Boisgueheneuc, F., Pluchon, C., Bouyer, C., Stal, V., Bataille, B., . . . Gil, R. (2013). Intraoperative monitoring of an aspect of executive functions: administration of

- the Stroop test in 9 adult patients during awake surgery for resection of frontal glioma. *Neurosurgery*, 72(2 Suppl Operative), ons169-80; discussion ons180-1. doi:10.1227/NEU.0b013e31827bf1d6
- Weinberg, R. A. (2013). *The biology of cancer* (Second edition). New York: Taylor & Francis.
- Whitaker, H. A., & Ojemann, G. A. (1977). Graded localisation of naming from electrical stimulation mapping of left cerebral cortex. *Nature*, 270(5632), 50–51.
- Whittle, I. R., Borthwick, S., & Haq, N. (2003). Brain dysfunction following 'awake' craniotomy, brain mapping and resection of glioma. *British journal of neurosurgery*, 17(2), 130–137.
- Xerri, C. (2011). Experience-dependent reorganization of somatosensory Experience-dependent reorganization of somatosensory and motor cortical areas: towards a neurobiology of rehabilitation. In H. Duffau (Ed.), *Brain mapping. From neural basis of cognition to surgical applications* (pp. 111–129). Vienna, New York: Springer.
- Yordanova, Y. N., Moritz-Gasser, S., & Duffau, H. (2011). Awake surgery for WHO Grade II gliomas within "noneloquent" areas in the left dominant hemisphere: toward a "supratotal" resection. Clinical article. *Journal of Neurosurgery*, 115(2), 232–239. doi:10.3171/2011.3.JNS101333
- Youden, W. J. (1950). Index for rating diagnostic tests. *Cancer*, 3(1), 32–35.
- Zatorre, R. J., Fields, R. D., & Johansen-Berg, H. (2012). Plasticity in gray and white: neuroimaging changes in brain structure during learning. *Nature neuroscience*, 15(4), 528–536. doi:10.1038/nn.3045.
- Zucchella, C., Bartolo, M., Di Lorenzo, C., Villani, V., & Pace, A. (2013). Cognitive impairment in primary brain tumors outpatients: a prospective cross-sectional survey. *Journal of neuro-oncology*, 112(3), 455–460. doi:10.1007/s11060-013-1076-8
- Zucchella, C., Capone, A., Codella, V., Nunzio, A. M., Vecchione, C., Sandrini, G., . . . Bartolo, M. (2013). Cognitive rehabilitation for early post-surgery inpatients affected by primary brain tumor: A randomized, controlled trial. *Journal of neuro-oncology*. doi:10.1007/s11060-013-1153-z

8 APPENDIX

- I **Becker, J., Steinmann, E., Könemann, M., Gabske, S., Mehdorn, H. M., Synowitz, M., Hartwigsen, G., Goebel, S. (2016).** Cognitive screening in patients with intracranial tumors: validation of the BCSE. *Journal of Neuro-oncology*, 127(3), 559–567. doi:10.1007/s11060-016-2064-6

Reprint with kind permission of Springer (<http://www.springer.com>)

- II **Becker, J., Jehna, M., Steinmann, E., Mehdorn, H. M., Synowitz, M., & Hartwigsen, G. (2016).** The sensory-motor profile awake - A new tool for pre-, intra-, and postoperative assessment of sensory-motor function. *Clinical Neurology and Neurosurgery*, 147, 39–45. doi:10.1016/j.clineuro.2016.05.022

Reprint with kind permission of Elsevier (<https://www.elsevier.com>)

- III **Becker, J., Jehna, M., Larsen, N., Synowitz, M., & Hartwigsen, G. (2016).** Glioblastoma in hemihydranencephaly: preoperative and postoperative language ability of the right hemisphere. *Acta Neurochirurgica*, 158(7), 1317–1323. doi:10.1007/s00701-016-2825-1

Reprint with kind permission of Springer (<http://www.springer.com>)

Appendix I

Cognitive screening in patients with intracranial tumors: validation of the BCSE

Juliane Becker¹ · Elisabeth Steinmann¹ · Maria Könemann¹ ·
Sonja Gabske¹ · Hubertus Maximilian Mehdorn¹ ·
Michael Synowitz¹ · Gesa Hartwigsen^{2,3} · Simone Goebel¹

Received: 16 September 2015 / Accepted: 22 January 2016
© Springer Science+Business Media New York 2016

Abstract This study presents the first validation of the Brief Cognitive Status Exam (BCSE) against two other screening tools for cognitive impairment in patients with intracranial tumors. 58 patients and 22 matched healthy controls completed the BCSE, the Mini Mental State Examination (MMSE) and the Montreal Cognitive Assessment (MoCA). Patients were additionally tested with a comprehensive neuropsychological battery. Based on this assessment, they were classified as cognitively impaired or unimpaired on five cognitive domains. Analyses revealed a comparable feasibility of the BCSE relative to the MoCA and the MMSE, but a smaller range of assessed functions (e.g., no correlation with the domain visual-spatial functions). The ability to separate patients and healthy controls was extremely poor for BCSE and MMSE (sensitivity of 38.6 % and less), but moderate for MoCA (sensitivity 68.97 %). Detection of cognitive impairment in patients was worst with BCSE (sensitivity 37 %; MoCA 92.9 %, MMSE 44.4 %) as compared to neuropsychological testing. Moreover, prediction of cognitive outcome was also worst for the BCSE (AUC = .713, NPV = 50 %). An optimal cut-off of 50.5 increased the

results slightly. In summary, the BCSE showed good feasibility but no sufficient results in separating healthy individuals from patients or detecting cognitive impairment in patients. Consequently, as a screening measure, we would recommend the MoCA instead of the BCSE. However, since even the MoCA failed to detect cognitive impairment, our study supports the view that reliable results could only be obtained with a comprehensive neuropsychological battery.

Keywords Screening instrument · Neuropsychological diagnostic · Intracranial tumor

Introduction

Intracranial tumors refer to any solid neoplasm inside the bony skull. Their growth can alter normal brain function and cause symptoms like increased intracranial pressure, neurological deficits, epileptic seizures and (neuro-) psychological changes. Common treatment for intracranial tumors includes neurosurgical operations, chemotherapy and/or radiotherapy. These treatments, as well as the growth of the intracranial tumor mass and possible infiltration of brain tissue are likely to account for the frequently reported reduced cognitive abilities in this patient group [1–8].

Cognitive performance relies on intact sensory and motor abilities and several discrete functions. They are typically assessed during neuropsychological examinations that consider multiple domains representative for both hemispheres, including memory, attention, orientation, speech and executive functions [8]. Precise identification of (even minor) cognitive impairments is on one hand important for clinical patient management since it

Electronic supplementary material The online version of this article (doi:10.1007/s11060-016-2064-6) contains supplementary material, which is available to authorized users.

✉ Juliane Becker
juliane.becker@uksh.de

¹ Department of Neurosurgery, University Hospital Schleswig-Holstein, Arnold-Heller-Straße 3, 24105 Kiel, Germany

² Department of Psychology, University of Kiel, Kiel, Germany

³ Department of Neuropsychology, Max Planck Institute for Human Cognitive and Brain Sciences, Leipzig, Germany

determines further treatment options like cognitive and social rehabilitation. Moreover, cognitive impairment is a predictor of recurrence and survival [3, 9] and is associated with an overall decrease in quality of life and execution of activities of daily living [10, 11]. On the other hand, identification of cognitive impairment is particularly important for research studies that include cognitive status as an outcome measure, for example in evaluation of treatment effects and side effects [8, 9, 11, 12]. The current gold standard recommends a comprehensive neuropsychological test battery with a duration of at least one hour for assessment of cognitive domains [13]. However, comprehensive testing is very costly as it necessitates trained personal, test rooms, testing materials and time. Therefore, many clinical trials rely on short screening tools like the MMSE [12, 14–16]. However, it is questionable whether cognitive screening instruments represent valid alternatives to comprehensive neuropsychological test batteries in some settings and patients [12, 15, 17]. As one of the few studies considering a comparison of screening tools against the gold standard of a comprehensive neuropsychological test battery, Olson and colleagues [18] compared the screening tools MMSE and MoCA [19] in patients with intracranial tumors ($n = 58$). They reported a sensitivity of only 61.9 % for the MoCA and 19 % for the MMSE and a specificity of 94.4 % for the MMSE (MoCA 55.6 %) relative to a 3–4 h neuropsychological assessment battery. Further analysis failed to reveal any cut-off score where satisfying detection of cognitive impairment in this population was possible and further investigations of the MoCA in this collective were recommended. Hence, valid alternative screening tools for detection of cognitive decline are desirable. The need for studies involving new, alternative screening tools was further stressed by the results of a previous study in acute stroke patients that demonstrated an underestimation of cognitive impairment for the MoCA compared to a neuropsychological assessment [20].

The novel screening instrument BCSE [21] might represent a promising tool for this purpose. However, to the best of our knowledge, this test has not been compared to the gold standard of a test battery to date. Consequently, the validity and diagnostic properties of the BCSE to identify cognitive impairment in patients with intracranial tumors remain to be determined.

The primary goal of this study was to explore whether the BCSE is a superior alternative for neuropsychological screening as compared with the MoCA and MMSE in patients with intracranial tumors. A validation of this novel tool was mandatory since this test has not been used in patients with intracranial tumors so far. Therefore, our first aim was to examine the feasibility and convergent validity of the BCSE in comparison to the established screening instruments MoCA and MMSE.

Secondly, we aimed at providing a comprehensive comparison of the sensitivity and specificity and other diagnostic properties of the BCSE relative to MoCA and MMSE. Particularly, we examined whether the BCSE would be more reliable than the older screenings in (i) detecting patients with intracranial tumors versus healthy subjects and (ii) detecting cognitive impaired subjects in a patient cohort asserted by the gold standard of a comprehensive neuropsychological test battery covering several cognitive domains.

The neuropsychological test battery in our study was conceptualized as a German version of the cognitive domains suggested by Olson and colleagues [18] but was considerably shorter in terms of assessment time. This was mandatory to reduce the influences of exhaustion, selection bias and split assessment that was reported previously [18]. Thereby, we aimed to reduce the dropout rate and gain complete neuropsychological profiles for each patient.

Methods

Screening-instruments

The *BCSE*, as part of the Wechsler Memory Scale—Fourth Edition [21], is a screening tool to assesses basic cognitive functions: orientation to time, incidental recall, mental control, planning/visual perceptual processing, inhibitory control, and verbal productivity. The necessary assessment time ranges between 7 and 11 min. To the best of our knowledge, only one previous study evaluated the BCSE [22] by comparing it with the MMSE in patients with mild cognitive impairment (MCI) or dementia and healthy controls. The BCSE provided a better sensitivity in patients with Alzheimer's dementia. However, it was less specific in correctly distinguishing older adults with MCI from healthy controls. The present study should thus represent the first validation of the diagnostic properties of the BCSE in patients with intracranial tumors.

The *MoCA* evaluates cognitive functions in about 10 min [19]. Current studies show a clear advantage over the MMSE also in neuro-oncological patients [6, 23, 24]. The MoCA provides a relatively higher sensitivity compared to the MMSE [19, 24–26] and is less affected by ceiling effects [27] as it includes more demanding tasks [19]. However, specificity was lower than in MMSE [19, 23, 25, 26]. It was previously validated in patients with intracranial tumors [24].

The *MMSE* [14, 28] assesses cognitive functions also in about 10 min. The MMSE is often used in patients with intracranial tumors [2, 29, 30], although it has not been systematically validated in these patients to date [16, 29]. Moreover, application in patient groups other than

dementia has been criticized [30] as it demonstrated a relatively low validity [12, 16, 19, 26, 31].

Feasibility analysis

We assessed admission time and subjective perceived tolerability and strain for each screening instrument. For the latter, we modified the ranges of a visual analogue scale (VAS) [32] from “not at all tolerable” (0) to “very tolerable” (10) and respectively from “not at all exhausting” (0) to “very exhausting” (10). In addition, patients had to state which screening tool they would prefer. For subjective validity, they were asked which of the screening tools was best in measuring their perceived changes due to the disease.

Cognitive domains

Table 1 displays the applied test battery, which was based on two previous studies (see Online Resource 1 for procedure of assessment) [7, 10]. Both used comprehensive neuropsychological test batteries and assigned tests to particular domains. In the study by Satoer and colleagues [7], lexical word fluency was assigned to the domain language. In contrast, semantic word fluency was assigned to the domain “memory” in the present study since areas involved in executive and verbal functions seem to support semantic word fluency, but contribute less to this task than temporal (i.e., memory related) regions [33]. Indeed, neuroimaging studies revealed stronger activation in the left hippocampal areas than in the dorsolateral pre-frontal cortex for semantic word fluency [34].

Subjects

All eligible patients scheduled for routine neuropsychological examination between April 2013 and July 2014 were pre-screened for study participation. The control group was recruited among relatives and matched to the patient group in terms of age, years of education and gender (for detailed information see Online Resource 1).

Statistical analysis

The data analyses were carried out with the statistical package for social sciences (SPSS) Version 21...0 and MedCalc V.12.2.1.0. For a detailed description of the statistical analysis concerning the preliminary analysis including feasibility and validity see Online Resource 1.

We referred to the cut-off scores reported in the respective manuals for group definition of cognitive status variables in the screening tools. All subjects reaching lower scores were labeled as “cognitively impaired.” In case of

the MMSE, we used <26 as cut-off [14]. For the MoCA and the BCSE, we used the standard cut-off scores of <27 or the percentile rank of <15 , respectively [19, 21].

In the test battery, cognitive impairment was assumed when at least one domain was indicative of impairment [1, 43]. For each domain, we obtained a z-score following the procedure outlined by two previous studies, for details see Online Resource 1 [1, 44].

In a first step, we calculated sensitivity, specificity, positive predictive value (PPV), negative predictive value (NPV) and diagnostic accuracy (DA) in detecting patients with intracranial tumors among healthy controls for the BCSE, MoCA and MMSE. Secondly, we tested these screening tools against a neuropsychological test battery. In each case, receiver operating characteristic (ROC) curves were constructed. The area under the curve (AUC) was calculated for each ROC curve as a measure of test accuracy. Statistical significances of the differences between AUCs were assessed with a non-parametric approach [45]. Optimal cut-off values were derived at ROC coordinate points where both sensitivity and specificity were optimized using the Youden Index [46]. In addition, we again calculated sensitivity, specificity, PPV, NPV and DA for the three screenings at these optimal cut-off scores.

Results

Subjects

In this prospective study trial, 58 patients participated before or after ($n = 5$) their neurosurgical operation (for details see Online Resource 2: Flowchart of the recruitment process). Sample characteristic are shown in Table 2. 58 patients (50 % female) aged 27–80 ($M = 58.03$; $SD = 13.94$) completed the whole assessment in 75–115 min; two of them completed only the screening instruments due to fatigue and exhaustion (1 of them only MoCA). Results regarding the prevalence of cognitive impairment are displayed in Online Resource 2.

The healthy, matched control subjects ($n = 22$) did not reveal any differences in age, gender or education (for details see Online Resource 2). Overall, the control group had significantly higher scores on each screening tool than the patient cohort.

Preliminary analysis

Analysis of feasibility

Assessment time for all three tools varied between 2 and 21 min (BCSE: $Md = 8$, range 4–15; MMSE: $Md = 5$, range 2–15, MoCA: $Md = 10$, range 3–21). The perceived

Table 1 Neuropsychological test battery

Domain/test	Cognitive abilities	Description
Language		
Subtests of the Aachen Aphasia Test (AAT, [35])		
Token test	Verbal comprehension	Pointing to and manipulating geometric forms on verbal command
Naming	Word finding	Naming Objects, colors and complex activities
Written language	Verbal academic skills	Writing to dictation and reading aloud
Language comprehension	Auditory and reading comprehension	Finding the object/scene out of three distracting stimuli
Lexical word fluency [36]	Phonological fluency	Producing words beginning with a given letter within 2 min
Attention and visuo- motor speed		
Digit Span [37]	Attention and working memory	Immediate repetition of digits forward and in reverse order
Trail-making test part A (TMT-A, [38])	Visuo-motor speed	Connecting 25 encircled numbers
Memory		
Memo-test [39]	Immediate and delayed verbal memory	Learning 10-item wordlist within five repetitions, recall after 15 min
Rey-Complex-Figure-Test (CFT, [40]) delayed recall	Implicit visual-spatial memory	Reproduction of the copied figure from memory
Semantic word fluency [36]	Semantic memory	Naming animals within two minutes
Executive functions		
Five-point test (FPT, [41]) sub score productivity	Figural fluency	Production of patterns by connecting dots within rectangles within three minutes
Trail-making test part B (TMT-B, [38])	Cognitive flexibility, visuo-motor speed	Connecting 25 encircled numbers and letters in alternating order
Semantic alternating categorical word fluency [36]	Flexibility of verbal fluency	Naming sports and fruits alternating within two minutes
Visuo-spatial functions		
Visual Object and Space Perception battery (VOSP, [42])		
Object decision	Object perception	Detecting silhouettes of a real object among fantasy drawings
CFT [40] copy	Visual-spatial processing	Copying a complex figure

AAT Aachen aphasia test; CFT Rey-complex-figure-test; FPT Five-point test; TMT-A Trail-making test part A; TMT-B Trail-making test part B; VOSP Visual object and space perception battery

strain of the BCSE (Md = 3, range 0–9) differed significantly from the MMSE (Md = 1, range 0–9; $z = -3.817$, $p = 0.000$). The subjective tolerability was significantly higher for the BCSE (Md = 9.5, range 5–10) than the MoCA (Md = 9, range 0.5–10; $z = -2.053$, $p = 0.038$). The screening tools were judged as equally appropriate by the patients ($X^2_{(2)} = 0.304$, $p = 0.899$), but the MoCA was significantly more often rated as the screening tool which can “detect actual problems” (32.8 %, $n = 19$), the MMSE was preferred by 5.2 % ($n = 3$), the BCSE by 17.2 % ($n = 10$) ($X^2_{(2)} = 12.063$, $p = 0.003$).

Analysis of validity

The BCSE correlated with the MMSE ($r = 0.475$, $p = 0.000$) and the MoCA ($r = 0.485$, $p = 0.000$). It showed significant correlations with the domains speech ($r = 0.388$, $p = 0.000$), attention and visuo-motor speed

($r = 0.302$, $p = 0.002$), memory ($r = 0.378$, $p = .000$) and executive functions ($r = 0.351$, $p = 0.000$), but no correlation with visual-spatial functions ($r = 0.070$, $p = 0.473$). Detailed results for MoCA and MMSE are displayed in Online Resource 2.

Main analysis: diagnostic properties of BCSE

Distinguishing patients from healthy controls

The MoCA revealed the highest sensitivity, while specificity was higher for MMSE and MoCA. Both tools classified 100 % of the control group as cognitively unimpaired, as compared with 81.8 % according to the BCSE. Best PPV was shown for MMSE and MoCA, best NPV and best diagnostic accuracy (DA) for the MoCA (Table 3). The AUC was highest for MoCA (0.848), but significant differences were only found between MoCA and BCSE.

Table 2 Sample characteristics patient cohort (N = 58)

Variable	n	%
Mean age in years	M = 58.03 (SD = 13.94) range = 27–80	
Sex		
Female	29	50
Male	29	50
Education (highest level)		
Elementary school	26	44.8
Junior high school	17	29.3
University entrance diploma	11	19.0
University degree	3	5.2
No graduation	1	1.7
Current employment status		
Currently employed/in education	37	64.0
Retired	17	29.3
Housekeeper/unemployed	4	6.9
Pre-morbid intellectual level/IQ ^a	M = 110.25 (SD = 10.80) range = 82–137	
Karnofsky Performance Status 0-100 (n = 47)	M = 87.13 (SD = 13.54) range = 50–100	
Previous neurosurgical treatment		
None	47	58.8
First recurrence after initial operation	10	12.5
Second recurrence	1	1.3
WHO grading		
WHO I	15	29.9
WHO II	9	15.5
WHO III	7	12.1
WHO IV	20	34.5
No WHO grading		
Malignant tumor (Metastases)	4	6.9
Benign tumor (Schwannoma)	1	1.7
No histopathological report ^b	2	3.4
Tumor-histological diagnosis		
Meningioma	15	25.9
Astrocytoma	10	17.2
Glioblastoma multiforme	20	34.5
Other	11	19.0
No histopathological report	2	3.4
Tumor-lateralization		
Right	23	39.7
Left	24	41.4
Other (e.g. multiple or medial)	11	19.0
Main tumor-localization		
Frontal	20	34.5
Temporal	11	19.0
Parietal	11	19.0
Occipital	2	3.4
Multiple	8	14.0

Table 2 continued

Variable	n	%
Basal ganglia, cerebellum and adjacent structures	6	10.3

M arithmetic mean; *SD* standard deviation; *WHO* World health organization

^a Estimated via the socio-demographic equation [47, 48]

^b One patient suffered from a meningioma of the falx cerebri (radiological report), but died under the surgery. One patient declined a surgery and was diagnosed with gliomatosis cerebri (radiological report)

Table 3 Diagnostic properties distinguishing patients from healthy controls (manual cut-off)

	AUC	SD	P	Sensitivity	Specificity	PPV	NPV	DA
BCSE	0.699	0.0638	0.0018	38.6	81.82	84.6	34.0	50.6
MoCA	0.848	0.0409	<0.0001	68.97	100	100	55.3	77.5
MMSE	0.826	0.0463	<0.0001	28.07	100	100	33.9	47.4
Comparison of AUC ^o		<i>z</i>	<i>p</i>					
MoCA-BCSE	1.966	.0493*						
MMSE-BCSE	1.611	0.1072						
MMSE-MoCA	-0.356	0.7218						

AUC area under the curve; *BCSE* Brief Cognitive Status Exam; *DA* diagnostic accuracy; *MMSE* Mini Mental State examination; *MoCA* Montreal cognitive assessment; *NPV* negative predictive value; *P* probability; *PPV* positive predictive value; *SD* standard deviation; ^o test statistic: *z* value; * significant with *P* < .05

Distinguishing patients with cognitive decline from unimpaired patients

The full protocol could not be applied to all patients: Priority was given to tests that were most relevant to the preparation and evaluation of the operative procedure, which accounts for fluctuating number of patients per domain (see [1]). 48.1 % (n = 26) of the patients were classified as unimpaired and 51.9 % (n = 28) as impaired in at least one domain (see Online Resource 2).

MoCA showed better sensitivity than MMSE at the respective cut-off scores, indicating higher specificity (Table 4). At the optimal cut-off score, sensitivity was highest for MoCA and specificity was highest for MMSE. Regarding cognitive impairment in the neuropsychological test battery, the AUC for MoCA was highest. A significant difference between two ROC curves was found for MoCA and BCSE.

Discussion

This is the first study comparing the BCSE with the MoCA and the MMSE in terms of feasibility and diagnostic properties in patients with intracranial tumors. With respect to the feasibility of the BCSE in patients with intracranial tumors, we experienced that assessment time of the BCSE was similar to the estimated time provided in the manual and lay between MMSE and MoCA. All screening tools were perceived as hardly straining, highly tolerable and

equally appropriate. The significantly higher strain of BCSE and MoCA in comparison with MMSE probably reflects higher demands on executive functions and memory in both tests. Additionally, the BCSE was rated as more tolerable than the MoCA, which might explain why the MoCA, as the subjectively most difficult tool, was significantly more often judged as the screening tool that could “detect the actual problems”.

As expected, we found medium but significant correlations between the BCSE and the two other screening tools (r = 0.475–0.485). While the BCSE was the only screening that failed to show a significant relationship with visuo-spatial functions, this test showed low significant correlations with all other domains. This can be explained by the lack of the BCSE in assessing visuo-spatial functions. As this is the first study investigating the BCSE in the population of patients with intracranial tumors, our results remain to be replicated in future studies. A detailed discussion of the results of MoCA and MMSE can be found in Online Resource 3.

Distinguishing patients and healthy controls

One of our main goals was to examine the BCSE’s ability to correctly distinguish patients with an intracranial tumor from healthy individuals. It should be kept in mind, however, that the screening tools were not constructed to address this specific issue.

Regarding the specificity of the tools, it should be noted that the control group was correctly classified as

Table 4 Diagnostic properties of cognitive impairment according to neuropsychological test battery

	AUC	SD	P	Manuals cut-off	J	sens	spec	PPV	NPV	DA
BCSE	0.713	0.0747	0.003	PR 15 %		37.0	65.4	52.6	50.0	50.9
MoCA	0.895	0.0412	<0.000	<26	0.503	92.9	61.5	72.2	88.9	77.8
MMSE	0.845	0.0547	<0.000	<26	0.516	44.4	92.3	85.7	61.5	67.9
Comparison of AUC ^o		z	p							
MoCA-BCSE		2.133	0.033*							
MMSE-BCSE		1.426	0.154							
MMSE-MoCA		-0.730	0.47							
				Optimal cut-off						
BCSE				<51/50.5	0.439	59.3	84.6	80.0	66.7	72.7
MoCA				<24/23.5	0.632	78.6	84.6	84.6	78.5	81.5
MMSE				<28/27.5	0.625	74.1	88.5	87.0	76.7	81.1

AUC area under the curve; BCSE Brief Cognitive Status Exam; DA diagnostic accuracy; J Youden's J; MMSE Mini Mental State examination; MoCA Montreal cognitive assessment; NPV negative predictive value; p probability; PPV positive predictive value; PR percentile rank; SD standard deviation; sens sensitivity; spec specificity; ^o test statistic: z value; * significant with $p < .05$

unimpaired with 100 % by MMSE and MoCA. Surprisingly, the BCSE considered four of them as impaired. With respect to the very low specificity in detecting cognitive impairment (see below), we assume that this outcome is a false positive classification. The ability to correctly identify those individuals who have been classified as tumor patients (i.e., the sensitivity) was extremely poor for BCSE (38.6 %), but also for the MMSE with even less sensitivity. The best, but still moderate sensitivity was achieved for the MoCA (68.97 %). Better results were obtained for the probability that the tested person was a patient (i.e., impaired) based upon a positive score (PPV), which was considerably higher for all screenings (BCSE 84.6 %, MoCA 100 %, MMSE 100 %). In contrast, the NPV probability of a valid negative test result (i.e., unimpaired) was very low (≤ 55.3 %). Overall, diagnostic accuracy favored the MoCA. ROC-analysis revealed low AUC for BCSE, while AUCs for MMSE and MoCA were good (0.826 and 0.848). Although no significant differences (only in tendency) were found between the AUCs of MoCA and MMSE, our results suggest that the MoCA seems to be the best alternative in clinical screening situations because it demonstrated the highest sensitivity. However, it should be noted that it still misses one third of ill patients, indicating that it should not serve as the sole criterion for assuming a brain disease and initiating further diagnostic.

Detecting cognitively impaired patients

Our second main goal was to examine the ability of the BCSE to correctly identify those patients who have been classified as cognitively impaired according to the current gold standard of a comprehensive neuropsychological test

battery. When the cut-offs provided by the manuals were used, the BCSE showed extremely low abilities to detect impaired individuals (37 %). The best alternative screening tool was the MoCA (92.9 %). Considering the specificity, the BCSE's ability to detect cognitively unimpaired individuals among patients with an intracranial tumor was moderate but similar to the results of the MoCA (MoCA 61.5 %; BCSE 65.4 %). The best alternative screening for this purpose was the MMSE (92.3 %). Converging results were reported by other authors comparing MMSE and MoCA in different and similar patient populations [18, 19, 26, 49]. For the BCSE, the poor results need to be further explored in future studies.

Finally, prediction of cognitive outcome was worst for the BCSE (AUC = 0.713) compared to the other screening tools. Hence, with respect to the negative predictive value (NPV), results from BCSE were in poor agreement with the neuropsychological test battery as patients with a BCSE score above PR 15 were likely to meet neuropsychological criteria for cognitive impairment after comprehensive evaluation (NPV = 50 %). Conversely, patients classified as impaired by the BCSE (score < PR15) had a probability of 52.6 % to be diagnosed as impaired by the test battery. The best alternative screening tool here again was the MoCA with clearly superior results (NPV = 88.9; PPV = 72.2).

Importantly, examination of different cut-off scores lead to the conclusion that only in case of the BCSE the use of an optimal cut-off increased both sensitivity and specificity, indicating that the use of the stratified norms leads to substantial misclassification of patients with intracranial tumors. Despite this improvement, the values remained far below the diagnostic ability of MMSE and MoCA.

In summary, the BCSE is as feasible as the MoCA or the MMSE in patients with intracranial tumors, but seems to

lack the assessment of visuo-spatial functions. In addition, compared to MoCA and MMSE, it showed the lowest diagnostic qualities in several areas and therefore cannot be recommended as a screening tool for cognitive status in these patients. This also holds true for clinical trials, as our results identified the MoCA as the screening tool with best PPV and NPV and again did not favor the BCSE. Nevertheless, for clinical as well as research settings it should be kept in mind that screening tools usually underestimate the amount of cognitive deficits and the effect of treatment on cognition in comparison with a comprehensive neuropsychological test battery.

Acknowledgments We would like to thank the Familie Mehdorn Stiftung for funding this study. We thank Rajka Matthiesen and Lea Schmitz for the excellent assistance in data acquisition, and Yumiko Nakai for her helpful comments on the manuscript. This manuscript or parts of it have not been published previously and have not been submitted simultaneously for publication in another source.

Funding Juliane Becker and Elisabeth Steinmann were receiving a grant from the Familie Mehdorn Stiftung. None of the other authors received any financial or material support.

Compliance with ethical standards

Disclosure of potential conflicts of interest The authors declare that they have no conflict of interest.

Ethical approval All procedures performed in this study involving human participants were in accordance with the ethical standards of the institutional research committee and with the 1964 Helsinki declaration and its later amendments.

Informed consent Informed consent was obtained from all individual participants included in the study.

References

1. Talacchi A, Santini B, Savazzi S et al (2011) Cognitive effects of tumour and surgical treatment in glioma patients. *J Neurooncol* 103(3):541–549. doi:10.1007/s11060-010-0417-0
2. Murray KJ, Scott C, Zachariah B et al (2000) Importance of the Mini-Mental Status Examination in the treatment of patients with brain metastases: a report from the radiation therapy oncology group protocol 91-04. *J Radiat Oncol Biol Phys* 48:59–64
3. Meyers CA, Hess KR, Yung WKA et al (2000) Cognitive function as a predictor of survival in patients with recurrent malignant glioma. *J Clin Oncol* 18:646–650
4. Klein M, Heimans JJ, Aaronson NK et al (2002) Effect of radiotherapy and other treatment-related factors on mid-term to long-term cognitive sequelae in low-grade gliomas: a comparative study. *Lancet* 360(9343):1361–1368. doi:10.1016/S0140-6736(02)11398-5
5. Santini B, Talacchi A, Squintani G et al (2012) Cognitive outcome after awake surgery for tumors in language areas. *J Neurooncol* 108(2):319–326. doi:10.1007/s11060-012-0817-4
6. Olson RA, Chhanabhai T, McKenzie M (2008) Feasibility study of the Montreal Cognitive Assessment (MoCA) in patients with brain metastases. *Support Care Cancer* 16(11):1273–1278. doi:10.1007/s00520-008-0431-3
7. Satoer D, Vork J, Visch-Brink E et al (2012) Cognitive functioning early after surgery of gliomas in eloquent areas. *J Neurosurg* 117:831–838
8. Taphoorn MJB, Klein M (2004) Cognitive deficits in adult patients with brain tumours. *Lancet Neurol* 3(3):159–168. doi:10.1016/S1474-4422(04)00680-5
9. Meyers CA, Rock EP, Fine HA (2012) Refining endpoints in brain tumor clinical trials. *J Neurooncol* 108(2):227–230. doi:10.1007/s11060-012-0813-8
10. Zucchella C, Bartolo M, Di Lorenzo C et al (2013) Cognitive impairment in primary brain tumors outpatients: a prospective cross-sectional survey. *J Neurooncol* 112(3):455–460. doi:10.1007/s11060-013-1076-8
11. Bunevicius A, Tamasauskas S, Deltuva V et al (2014) Predictors of health-related quality of life in neurosurgical brain tumor patients: focus on patient-centered perspective. *Acta Neurochir (Wien)* 156(2):367–374. doi:10.1007/s00701-013-1930-7
12. Meyers CA, Brown PD (2006) Role and relevance of neurocognitive assessment in clinical trials of patients with CNS tumors. *J Clin Oncol* 24(8):1305–1309. doi:10.1200/JCO.2005.04.6086
13. Papagno C, Casarotti A, Comi A et al (2012) Measuring clinical outcomes in neuro-oncology. A battery to evaluate low-grade gliomas (LGG). *J Neurooncol* 108(2):269–275. doi:10.1007/s11060-012-0824-5
14. Folstein MF, Folstein SE, McHugh PR (1975) “Mini-Mental State” A practical method for grading the cognitive state of patients for the clinician. *J Psychiatr Res* 12(3):189–198. doi:10.1016/0022-3956(75)90026-6
15. Patel RR, Mehta MP (2007) Targeted therapy for brain metastases: improving the therapeutic ratio. *Clin Cancer Res* 13(6):1675–1683. doi:10.1158/1078-0432.CCR-06-2489
16. Meyers CA, Wefel JS (2003) The use of the Mini-Mental State Examination to assess cognitive functioning in cancer trials: no ifs, ands, buts, or sensitivity. *J Clin Oncol* 21(19):3557–3558
17. Vardy J, Wong K, Yi Q et al (2006) Assessing cognitive function in cancer patients. *Support Care Cancer* 14(11):1111–1118. doi:10.1007/s00520-006-0037-6
18. Olson RA, Iverson GL, Carolan H et al (2011) Prospective comparison of two cognitive screening tests: diagnostic accuracy and correlation with community integration and quality of life. *J Neurooncol* 105:337–344
19. Nasreddine ZS, Phillips NA, Bedirian V et al (2005) The Montreal Cognitive Assessment, MoCA: a brief screening tool for mild cognitive impairment. *J Am Geriatr Soc* 53(4):695–699
20. Chan E, Khan S, Oliver R et al (2014) Underestimation of cognitive impairments by the Montreal Cognitive Assessment (MoCA) in an acute stroke unit population. *J Neurol Sci* 343(1–2):176–179. doi:10.1016/j.jns.2014.05.005
21. Petermann F, Lepach AC (eds) (2012) Wechsler Memory Scale-Fourth Edition (WMS-IV). Manual zur Durchführung und Auswertung. Always learning, 4th edn. Pearson, Frankfurt
22. Bouman Z, Hendriks, Marc PH, Aldenkamp AP et al. (2014) Clinical validation of the WMS-IV-NL brief cognitive status exam (BCSE) in older adults with MCI or dementia. *Int Psychogeriatr*, 1–9, doi: 10.1017/S1041610214001471
23. Olson RA, Iverson GL, Parkinson M, Carolan H, Ellwood A, McKenzie M (2009) Investigation of cognitive screening measures in patients with brain tumors: Diagnostic accuracy and correlation with quality of life.: Meeting Abstract e13000. *J Clin Oncol*, 27
24. Olson RA, Tyldesley S, Carolan H et al (2011) Prospective comparison of the prognostic utility of the Mini Mental State Examination and the Montreal Cognitive Assessment in patients

- with brain metastases. *Support Care Cancer* 19(11):1849–1855. doi:[10.1007/s00520-010-1028-1](https://doi.org/10.1007/s00520-010-1028-1)
25. Gauthier S, Reisberg B, Zaudig M et al (2006) Mild cognitive impairment. *Lancet* 367:1262–1270
 26. Smith T, Gildeh N, Holmes C (2007) The Montreal Cognitive Assessment: validity and utility in a memory clinic setting. *Can J Psychiatry* 52:329–332
 27. Wong GKC, Lam S, Ngai K et al (2012) Evaluation of cognitive impairment by the Montreal Cognitive Assessment in patients with aneurysmal subarachnoid haemorrhage: prevalence, risk factors and correlations with 3 month outcomes. *J Neurol Neurosurg Psychiatry* 83(11):1112–1117. doi:[10.1136/jnnp-2012-302217](https://doi.org/10.1136/jnnp-2012-302217)
 28. Kessler J, Denzler P, Markowitsch HJ (1990) Der mini-mental-status-test. Beltz, Weinheim
 29. Brown PD, Buckner JC, O'Fallon JR et al (2003) Effects of radiotherapy on cognitive function in patients with low-grade glioma measured by the folstein mini-mental state examination. *J Clin Oncol* 21(13):2519–2524. doi:[10.1200/JCO.2003.04.172](https://doi.org/10.1200/JCO.2003.04.172)
 30. Malloy PF, Cummings JL, Coffey CE et al (1997) Cognitive screening instruments in neuropsychiatry: a report of the Committee on Research of the American Neuropsychiatric Association. *J Neuropsychiat Clin Neurosci* 9(2):189–197
 31. Shibamoto Y, Baba F, Oda K et al (2008) Incidence of brain atrophy and decline in Mini-Mental State Examination score after whole-brain radiotherapy in patients with brain metastases: a prospective study. *Int J Radiat Oncol Biol Phys* 72(4):1168–1173
 32. NCCN (2003) Distress management Clinical practice guidelines. *J Natl Compr Cancer Netw* 1(3):344–374
 33. Baldo JV, Schwartz S, Wilkins D et al (2006) Role of frontal versus temporal cortex in verbal fluency as revealed by voxel-based lesion symptom mapping. *J Int Neuropsychol Soc* 12(6):896–900. doi:[10.1017/S1355617706061078](https://doi.org/10.1017/S1355617706061078)
 34. Pihlajamäki M, Tanila H, Hänninen T et al (2000) Verbal fluency activates the left medial temporal lobe: a functional magnetic resonance imaging study. *Ann Neurol* 47(4):470–476. doi:[10.1002/1531-8249\(200004\)47:4<470::AID-ANA10>3.0.CO;2-M](https://doi.org/10.1002/1531-8249(200004)47:4<470::AID-ANA10>3.0.CO;2-M)
 35. Huber W, Poeck K, Weniger D, Willmes K (1983) Aachener Aphasie Test (AAT). Hogrefe, Göttingen
 36. Aschenbrenner A, Tucha O, Lange K (2000) Regensburger Wortflüssigkeits-Test (RWT), Handanweisung. Hogrefe, Göttingen
 37. von Aster M, Neubauer A, Horn R (2006) Wechsler-Intelligenztest für Erwachsene WIE. Manual. Übersetzung und Adaption der WAIS-III von David Wechsler. Hartcourt Test Services, Frankfurt am Main
 38. Tombaugh T (2004) Trail making test A and B: normative data stratified by age and education. *Arch Clin Neuropsychol* 19(2):203–214. doi:[10.1016/S0887-6177\(03\)00039-8](https://doi.org/10.1016/S0887-6177(03)00039-8)
 39. Schaaf A, Kessler J, Grond M, Fink GR (1992) Memo-test manual. Beltz Testgesellschaft, Weinheim
 40. Rey A, Osterrieth PA (1998) Rey-Complex Figur Test (CFT). In: Spreen O, Strauss E (eds) A compendium of neuropsychological tests: administration, norms, and commentary, 2nd edn. Oxford University Press, New York, pp 341–363
 41. Goebel S, Fischer R, Ferstl R et al (2009) Normative data and psychometric properties for qualitative and quantitative scoring criteria of the Five-point Test. *Clin Neuropsychol* 23(4):675–690. doi:[10.1080/13854040802389185](https://doi.org/10.1080/13854040802389185)
 42. Warrington EK, James M. (1992) Testbatterie für visuelle Objekt- und Raumwahrnehmung (VOSP). Burry St Edmunds, Thames Valley Test Company
 43. Vardy J, Tannock I (2007) Cognitive function after chemotherapy in adults with solid tumours. *Crit Rev Oncol/Hematol* 63(3):183–202. doi:[10.1016/j.critrevonc.2007.06.001](https://doi.org/10.1016/j.critrevonc.2007.06.001)
 44. Correa DD, Shi W, Thaler HT et al (2008) Longitudinal cognitive follow-up in low grade gliomas. *J Neurooncol* 86(3):321–327. doi:[10.1007/s11060-007-9474-4](https://doi.org/10.1007/s11060-007-9474-4)
 45. DeLong ER, DeLong DM, Clarke-Pearson DL (1988) Comparing the areas under two or more correlated receiver operating characteristic curves: a nonparametric approach. *Biometrics* 44(3):837. doi:[10.2307/2531595](https://doi.org/10.2307/2531595)
 46. Youden WJ (1950) Index for rating diagnostic tests. *Cancer* 3(1):32–35
 47. Leplow B, Friege L (1998) Eine Sozialformel zur Schätzung der prä-morbiden Intelligenz. *Zeitschrift für Klinische Psychologie* 27: 1–8
 48. Jahn T, Beitlich D, Hepp S et al (2013) Drei Sozialformeln zur Schätzung der (prä-morbiden) Intelligenzquotienten nach Wechsler. *Zeitschrift für Neuropsychologie* 24(1):7–24. doi:[10.1024/1016-264X/a000084](https://doi.org/10.1024/1016-264X/a000084)
 49. Le Rhun E, Delbeuck X, Devos P et al (2009) Troubles cognitifs dans les gliomes de grade II et III de l'adulte: À propos d'une série de 15 patients (Cognitive disorders and adult grade II and III gliomas: analysis of a series of 15 patients). *Neurochirurgie* 55(3):303–308. doi:[10.1016/j.neuchi.2008.08.111](https://doi.org/10.1016/j.neuchi.2008.08.111)

Cognitive screening in patients with intracranial tumors:

Validation of the BCSE

Journal of Neuro-Oncology

Authors:

Juliane Becker ¹, MA; Elisabeth Steinmann ¹, MA; Maria Könemann ¹, MA; Sonja Gabske ¹, MA; Hubertus Maximilian Mehdorn ¹, MD; Michael Synowitz ¹, MD; Gesa Hartwigsen ², PhD, MA; Simone Goebel ¹, PhD, MA

1 Department of Neurosurgery, University Hospital Schleswig–Holstein, Kiel, Germany

2 Department of Psychology, University of Kiel, Kiel, Germany

Address correspondence to Juliane Becker, E-Mail: juliane.becker@uksh.de

Online Resource 1: Additional material section methods

Subjects

Inclusion and exclusion criteria for all patients

Online Resource 1 table 1 displays the Inclusion and exclusion criteria of this study. We excluded patient with a hemiplegia of the dominant arm, because this would have impeded their participation in most of the tests used in this study (i.e., paper and pencil tests). The same holds true for a neglect, which would cause patients to work only on one side of a given test sheet. A complete hemianopsia reduces the speed of visual exploration and therefore reduces the patient's performance in visual-motor speed dependent tasks.

Online Resource 1 table 1: Detailed Information about inclusion and exclusion criteria

Inclusion criteria

- diagnosis of an intracranial tumor (primary brain tumor, meningioma or metastasis);
- age between 20 and 80 years;
- native language German

Exclusion criteria

- severe aphasia (defined as less of 30% correct items in elected subtests of the AAT [1])
- serious physical/medical conditions like hemiplegia of the dominant arm, deficient orientation in terms of person and/or situation; being bedbound (Karnofsky Performance Scale <50) [2]
- known dementia or cognitive impairment prior to diagnosis of an intracranial tumor
- known history of drug abuse
- known medication with anesthetics (like Morphine or Diazepam) or antipsychotics (like Haloperidol) at the day of the assessment
- severe deficits in eyesight like diplopic images, complete hemianopsia, neglect or visual hallucinations (examination of eyesight [3])

AAT = Aachener Aphasie Test

Online Resource 1: Additional material section methods

Procedure of assessment

Patient's assessment took place 1-5 days prior or 4-5 days after the operation during in-patient stay as part of the patients' diagnostic routine. Participants did not receive any reimbursement. None of the patients were institutionalized. Socio-demographic and medical data were obtained via a semi-structured interview and the medical history. The pre-morbid intellectual level of functioning was estimated via the socio-demographic equation [4, 5]. First, eligible patients were asked to participate, familiarized with the procedure and gave their written informed consent. This was followed by comprehensive exploration, estimation of premorbid intelligence and AAT. If patients were further included, the three screening-instruments were given in pseudo-randomized order including the VASs for tolerability and strain as well as questions for subjective preference and validity. The neuropsychological test battery was performed in the following order: CFT copy, immediate verbal memory, digit span, verbal and figural fluency, VOSP, TMT, CFT delay, delayed verbal memory. Total assessment time was 75-115 min for each patient. The control group completed a shortened demographic interview and the screenings in pseudo-randomized order.

Statistical analysis

Preliminary analysis

Patient characteristics and raw test scores were presented using descriptive statistics. A difference with a p value < .05 was regarded as statistically significant (two tailed test) unless otherwise specified. To match patient data with healthy controls, categorical data were analyzed using the Fisher's exact test or χ^2 test, with ORs and 95% confidence interval (CI) where appropriate. For direct comparison of age and test scores, Mann-Whitney-U-Test was calculated. Median comparison of subjective data for strain, tolerability, preference and subjective validity was done with Wilcoxon signed-rank test. Correlations between screening tools, domains and risk factors were assessed using Kendal's rank correlation.

Main Analysis: Defining cognitive impairment

We first transformed raw test scores of the neuropsychological test battery into z-scores, based on the normative data of each subtest. Afterwards, we summed up the z-scores for all tests of a specific domain for each patient separately and calculated his mean z-score for each domain. For definition of cognitive impairment, we followed Vardy and colleagues [6] and determined moderate cognitive impairment as more than 1.5 standard deviations (SD) below the mean which corresponds to a z-score of <-1.5 [7]. Patients who met this criterion for cognitive impairment in at least one cognitive domain were labeled as "cognitively impaired".

References

1. Huber, W., Poeck, K., Weniger, D. & Willmes, K. (1983) Aachener Aphasie Test (AAT). Hogrefe, Göttingen
2. Karnofsky, D. A., Burchenal, J. H. (1949) The Clinical Evaluation of Chemotherapeutic Agents in Cancer. In: C. M. MacLeod (ed) Evaluation of Chemotherapeutic Agents. Columbia Univ Press, p 196
3. Niedeggen M, Jörgens S (2005) Visuelle Wahrnehmungsstörungen. Fortschritte der Neuropsychologie, Bd. 5. Hogrefe, Göttingen
4. Lепlow, B. & Friege, L. (1998) Eine Sozialformel zur Schätzung der prämorbidem Intelligenz. Zeitschrift für Klinische Psychologie(27): 1–8
5. Jahn T, Beitlich D, Hepp S et al. (2013) Drei Sozialformeln zur Schätzung der (prämorbidem) Intelligenzquotienten nach Wechsler. Zeitschrift für Neuropsychologie 24(1): 7–24. doi: 10.1024/1016-264X/a000084
6. Vardy J, Tannock I (2007) Cognitive function after chemotherapy in adults with solid tumours. Critical Reviews in Oncology/Hematology 63(3): 183–202. doi: 10.1016/j.critrevonc.2007.06.001
7. Vardy J, Rourke S, Tannock IF (2007) Evaluation of cognitive function associated with chemotherapy: A review of published studies and recommendations for future research. Journal of Clinical Oncology 25(17): 2455–2463

Cognitive screening in patients with intracranial tumors:

Validation of the BCSE

Journal of Neuro-Oncology

Authors:

Juliane Becker ¹, MA; Elisabeth Steinmann ¹, MA; Maria Könemann ¹, MA; Sonja Gabske ¹, MA; Hubertus Maximilian Mehdorn ¹, MD; Michael Synowitz ¹, MD; Gesa Hartwigsen ², PhD, MA; Simone Goebel ¹, PhD, MA

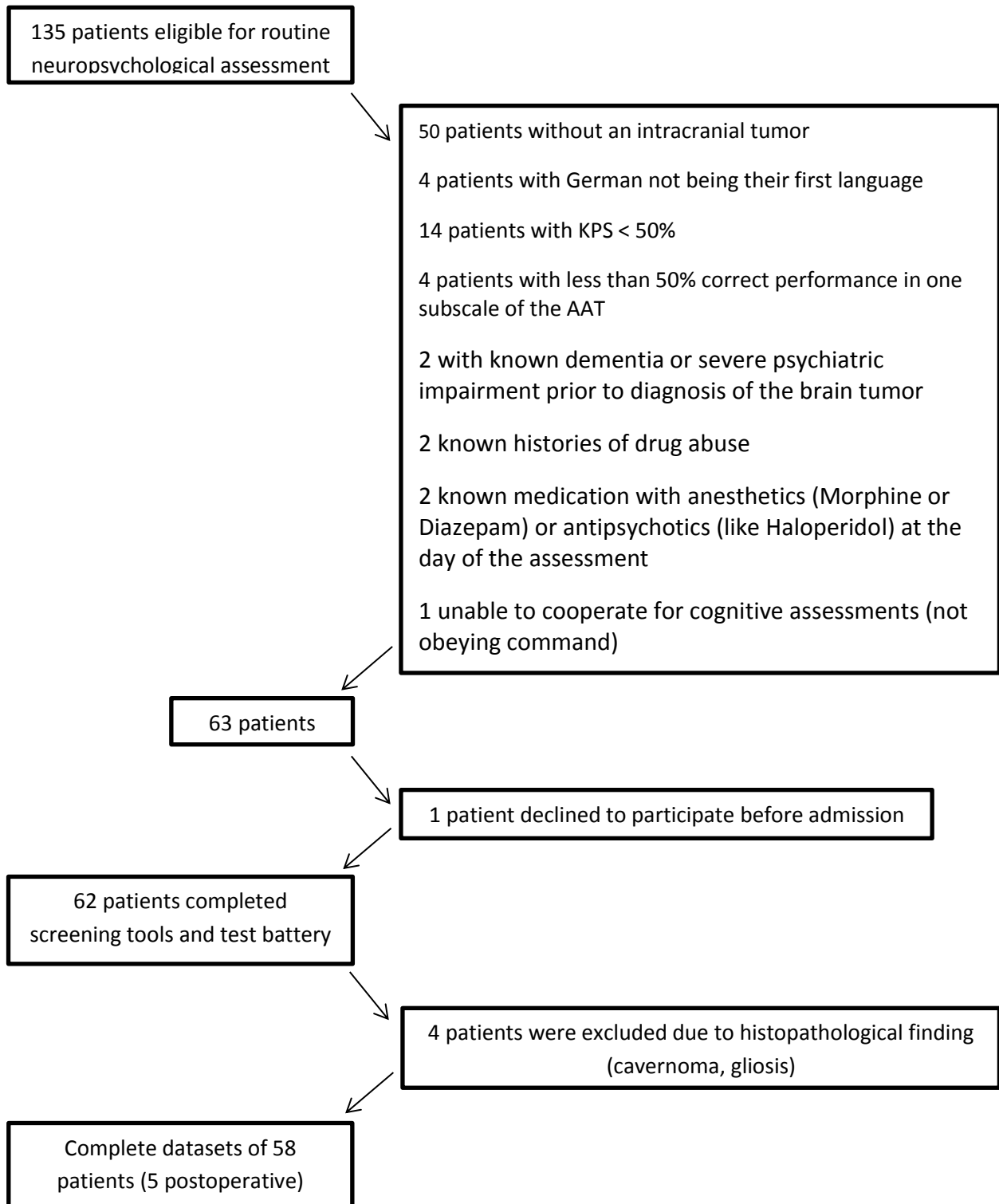
1 Department of Neurosurgery, University Hospital Schleswig–Holstein, Kiel, Germany

2 Department of Psychology, University of Kiel, Kiel, Germany

Address correspondence to Juliane Becker, E-Mail: juliane.becker@uksh.de

Online Resource 2: Additional material section results

Online Resource 2 figure 1: Flowchart of patient recruitment



AAT = Aachener Aphasia Test; KPS = Karnofsky Performance Scale

Online Resource 2: Additional material section results

Prevalence of cognitive impairment in patients with intracranial tumors

According to the screening tools, 28.1% up to 69.0% of the patients were classified as cognitively impaired. For details see table 1. 51.9% (n = 28) of the patients were classified as impaired in at least one cognitive domain. Most frequently, cognitive impairment was found in only one domain. Patients showed most often deficits in memory and visuo-spatial functions.

Online Resource 2 table 1: Cognitive impairment in patients

Screening tools°	Md	range	n	%
BCSE (n=57)	52	16-58	22	37.9
MoCA (n=58)	23	11-30	40	69.0
MMSE (n=57)	28	18-30	16	28.1

No. of impaired domains ^ (N=54)	n	%	cumulative %
0	26	48.1	100
1	15	27.8	51.9
2	9	16.7	24.0
3	3	5.6	7.4
4	1	1.9	1.9

Domain	z-scores		z < -1.5	
	M	SD	n	%
Language (n = 55)	0.18	1.12	3	5.6
Attention and visuo-motor speed (n = 53)	-0.39	1.31	6	11.3
Memory (n = 53)	-0.75	1.10	15	28.3
Executive functions (n = 50)	-0.62	1.24	9	18.0
Visuo-spatial functions (n = 54)	-1.19	1.82	15	27.8

BCSE = Brief Cognitive Status Exam; M = arithmetic mean; Md = Median; MMSE = Mini Mental State examination; MoCA = Montreal cognitive assessment; n = number; SD = standard deviation; °classification on basis of the manuals (MMSE cut-off: <26, MoCA cut-off <26, BCSE 15% percentile rank); ^ full protocol could not be applied to all patients: Priority was given to tests that were most relevant to the preparation and evaluation of the operative procedure (see [1]).

Online Resource 2: Additional material section results

Sample characteristics healthy control group

Online Resource 2 table 2: Sample characteristics healthy control group (N= 22)

			test statistics ³		
Mean age in years	M = 55.00 (SD= 15.37) range = 23-83		U = 589.0 , p = .602		
Sex	n	%			
Female	15	68.2	$\chi^2_{(1)} = 2.130$, p = .209		
Male	7	31.8			
Education (highest level)					
Elementary school	8	36.4	$\chi^2_{(4)} = 2.231$, p = .738		
Junior high school	8	36.4			
University entrance diploma	6	27.3			
University degree no graduation	0 0	0 0			
cognitively impaired^o					
	Md	range	n	%	
BCSE (n = 22)	56	42-58	4	18.2	U=377.0; p=.003
MoCA (n = 22)	28	26-30	0	0.0	U=194.5; p=.000
MMSE (n = 21)	30	27-30	0	0.0	U=208.0; p=.000

BCSE = Brief Cognitive Status Exam; M = arithmetic mean; Md = Median; MMSE = Mini Mental State examination; MoCA = Montreal cognitive assessment; n = number; p = probability; SD = standard deviation; U = Test statistic for Mann-Whitney-U-Test; χ^2 = test statistic chi-square test; ³ in comparison with the patient group; ^oclassification on basis of the manuals (MMSE cut-off: <26, MoCA cut-off <26, BCSE 15% percentile rank)

Results preliminary analysis

Analysis of feasibility: Additional results

The subjective strain differed significantly between MMSE (Md= 10, range =0-10) and MoCA (Md= 3, range= 0-8) ($z=-3.838$, $p=.000$). The subjective tolerability of MMSE had a median of 10 and a range of 0-10. The screening tools were judged as appropriate by the patients (MMSE 24.1%, $n=14$; MoCA 25.9%, $n=15$; BCSE 29.3% $n=17$).

Analysis of validity: Additional results

Correlation of MMSE and MoCA was slightly higher than for BCSE and both other tools (table 3). MMSE and MoCA sum scores correlated significantly with each of the five domains ($r=.192$ to $.539$). For details see table 4.

Online Resource 2: Additional material section results

Online Resource 2 table 3: Correlational analysis of the screening tools (Kendall-Tau-b)

	BCSE	MoCA
MMSE (n=78)	.475** p=.000	.641** p=.000
MoCA (n=79)	.485** p=.000	

BCSE = Brief Cognitive Status Exam; MMSE = Mini Mental State examination; MoCA = Montreal cognitive assessment; p = probability; * significant with $p < .05$ (two-tailed); ** significant with $p < .01$ (two-tailed)

Online Resource 2 table 4: Correlational analysis of screening tools (sum score) and domains (mean z-score) (Kendall-Tau-b)

screening (sum score)	Domain				
	speech	attention and visuo-motor speed	memory	executive functions	visual-spatial functions
BCSE	.388** (n=54)	.302** (n=52)	.378** (n=52)	.351** (n=50)	.070 p=.473 (n=53)
MoCA	.473** (n=55)	.389** (n=53)	.539** (n=53)	.385** (n=50)	.192* (n=54)
MMSE	.447** (n=54)	.395** (n=52)	.499** (n=52)	.333** (n=50)	.213* (n=53)

BCSE = Brief Cognitive Status Exam; MMSE = Mini Mental State examination; MoCA = Montreal cognitive assessment; n = number; *higher values indicating higher strain; °higher values indicating higher tolerability; * significant with $p < .05$ (two-tailed); ** significant with $p < .01$ (two-tailed)

Several *risk factors* showed significant relationship with the sum scores of the screening tools: higher age was correlated with lower sum scores in each screening tool ($r = -.46$ to $-.36$; $p = .000$), male patients showed lower sum scores for MoCA and BCSE ($U = 271.5$ respective $U = 259.5$; $p = .019$ respective $.018$), higher educational status was correlated with higher sum scores ($r = .287$ to $.304$; $p = .004$ to $.006$) and higher WHO-grade was correlated with lower sum scores ($r = -.338$ to $-.197$; $p = .001$ to $.059$). No relationship was found for lesion side (hemisphere) and premorbid IQ.

References

1. Satoer D, Vork J, Visch-Brink E et al. (2012) Cognitive functioning early after surgery of gliomas in eloquent areas. *Journal of Neurosurgery* 117: 831–838

Cognitive screening in patients with intracranial tumors:

Validation of the BCSE

Journal of Neuro-Oncology

Authors:

Juliane Becker ¹, MA; Elisabeth Steinmann ¹, MA; Maria Könemann ¹, MA; Sonja Gabske ¹, MA; Hubertus Maximilian Mehdorn ¹, MD; Michael Synowitz ¹, MD; Gesa Hartwigsen ², PhD, MA; Simone Goebel ¹, PhD, MA

1 Department of Neurosurgery, University Hospital Schleswig–Holstein, Kiel, Germany

2 Department of Psychology, University of Kiel, Kiel, Germany

Address correspondence to Juliane Becker, E-Mail: juliane.becker@uksh.de

Prevalence of cognitive impairment

Screenings

Comparison of healthy individuals with patients who were diagnosed with an intracranial tumor showed significantly higher scores in each screening tool for the healthy group. Depending on the screening tool used, 28.1% (MMSE) to 69.0% (MoCA) of the patients were classified as cognitively impaired when the published cut-off scores were used. We are not aware of any previous classification studies on cognitive impairment in a comparable collective. However, similar rates of 30% were found for the MMSE in patients with an intracranial tumor after radiotherapy [1]. The high rate of 69% of MoCA defined cognitive impairment corresponds roughly to the findings of Olson and colleagues [1] who studied patients with intracranial tumors after radiation and reported cognitive impairment in 80% of their sample. However, these findings need to be interpreted with caution since a later study by the same group reported different prevalence rates in patients after resection of intracranial tumors and chemo-/radiotherapy (MMSE 12.8% and MoCA 53.8% both with cut-offs <26) [2]. Finally, 37.9% of our patients showed BCSE-defined cognitive impairment. These findings need to be replicated in other samples as there are no previous studies on the application of the BCSE in a similar collective.

Domains

According to the comprehensive neuropsychological test battery applied in our study, 51.9% of the patients demonstrated cognitive impairment in *at least one cognitive domain*. This is in line with previous findings of defining cognitive impairment as a z-score of -2 in at least one domain and comparable reported rates of 38% and 37% impaired patients with intracranial tumors [3, 4]. Cognitive impairment in *only one domain* was prevalent in 27.8% of the patients, only 24.2% showed impairment in *two or more domains*. This also matches previous reports of cognitive impairment in only one domain in 24 % [3] or 32 % [4] of the tested collective, while 14% [3] or 5% [4] had two or more impaired domains. Among the most frequently affected domains were memory, visuo-spatial functions and executive functions, which is also in line with previous studies [3–5]. Note that discrepancies in prevalence between the different studies can be explained by different tests applied in each domain and different definitions of impairment (i.e., z-scores ranging from -1 to -2, all tests in one domain impaired) or selection biases in the study sample. For instance, Santini and Satoer [4, 5] restricted their study sample to patients undergoing awake surgery. In most of their patients, tumors were localized in the left hemisphere, which might have produced a higher prevalence of speech impairment than usually reported in the population of patients with intracranial tumors.

Preliminary analysis

Validity of MMSE and MoCA

Similar correlations of $r=.641$ between MMSE and MoCA were found in previous studies [6, 7], while investigations in individuals with mild cognitive impairment and mild Alzheimer's disease [8] or patients with brain metastasis after surgery and radiotherapy demonstrated higher correlations ($r=.74$, [9]).

The MMSE showed low, but significant correlation with each of the five domains, which was unexpected because executive functions were not assessed and other studies reported a poor sensitivity to detect visuo-spatial deficits [10]. In our sample, the visuo-spatial domain yielded the smallest correlation compared to other domains, which might be explained by the fact that the visuo-spatial items of the MMSE and the neuropsychological tests for the respective domain are similar (copy a figure). The correlation with the executive domain might be explained by the fact that executive functions contribute to almost all cognitive functions [11]. The MoCA also demonstrated a significant low to medium relationship with all five cognitive domains, indicating that each domain is roughly assessed by this test.

As expected, correlations between age, education, WHO grading and cognitive performance were found for healthy adults and, as formerly reported by other authors, also for patients with intracranial tumors [1, 10, 12–14]. Additionally, male patients showed worse cognitive performance in the MoCA and BCSE. Notably, while both tools include a word fluency task which usually reveals better performance in females [12], this test is not included in the MMSE. This might explain the observed differences in our patient sample. The missing relationship between intelligence and cognitive performance might be attributed to the measure of intelligence via estimation of a premorbid status. No relationship was found between tumor-affected hemisphere and performance in the screening tools.

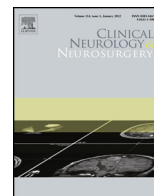
References

1. Olson RA, Chhanabhai T, McKenzie M (2008) Feasibility study of the Montreal Cognitive Assessment (MoCA) in patients with brain metastases. *Support Care Cancer* 16(11): 1273–1278. doi: 10.1007/s00520-008-0431-3

Online Resource 3: Additional material section discussion

2. Olson RA, Iverson GL, Carolan H et al. (2011) Prospective comparison of two cognitive screening tests: Diagnostic accuracy and correlation with community integration and quality of life. *Journal of Neurooncology* 105: 337–344
3. Talacchi A, Santini B, Savazzi S et al. (2011) Cognitive effects of tumour and surgical treatment in glioma patients. *J Neurooncol* 103(3): 541–549. doi: 10.1007/s11060-010-0417-0
4. Santini B, Talacchi A, Squintani G et al. (2012) Cognitive outcome after awake surgery for tumors in language areas. *J. Neurooncol.* 108(2): 319–326. doi: 10.1007/s11060-012-0817-4
5. Satoer D, Vork J, Visch-Brink E et al. (2012) Cognitive functioning early after surgery of gliomas in eloquent areas. *Journal of Neurosurgery* 117: 831–838
6. Regine WF, Schmitt FA, Scott CB et al. (2004) Feasibility of neurocognitive outcome evaluations in patients with brain metastases in a multi-institutional cooperative group setting: results of Radiation Therapy Oncology Group trial BR-0018. *International Journal of Radiation Oncology*Biophysics*Physics* 58(5): 1346–1352. doi: 10.1016/j.ijrobp.2003.09.023
7. Smith T, Gildeh N, Holmes C (2007) The Montreal Cognitive Assessment: Validity and utility in a memory clinic setting. *Canadian Journal of Psychiatry* 52: 329–332
8. Nasreddine ZS, Phillips NA, Bedirian V et al. (2005) The Montreal Cognitive Assessment, MoCA: A brief screening tool for mild cognitive impairment. *Journal of the American Geriatrics Society* 53(4): 695–699
9. Olson RA, Tyldesley S, Carolan H et al. (2011) Prospective comparison of the prognostic utility of the Mini Mental State Examination and the Montreal Cognitive Assessment in patients with brain metastases. *Support Care Cancer* 19(11): 1849–1855. doi: 10.1007/s00520-010-1028-1
10. Malloy PF, Cummings JL, Coffey CE et al. (1997) Cognitive screening instruments in neuropsychiatry: a report of the Committee on Research of the American Neuropsychiatric Association. *The Journal of Neuropsychiatry and Clinical Neurosciences* 9(2): 189–197
11. Schnider A (2008) *Verhaltensneurologie: Die neurologische Seite der Neuropsychologie. Eine Einführung für Ärzte und Psychologen*, 2nd edn. Thieme, Stuttgart
12. Iverson GL, Brooks BL (2011) Improving accuracy for identifying cognitive impairment. In: Schoenberg MR, Scott JG (eds) *The little black book of neuropsychology: A syndrome-based approach*. Springer, New York, London, pp 923–950
13. Tucha O, Smely C, Preier M et al. (2000) Cognitive deficits before treatment among patients with brain tumors. *Neurosurgery* 47(2): 324-33; discussion 333-4
14. Rossetti HC, Lacritz LH, Cullum CM et al. (2011) Normative data for the Montreal Cognitive Assessment (MoCA) in a population-based sample. *Neurology* 77(13): 1272–1275. doi: 10.1212/WNL.0b013e318230208a

Appendix II



The sensory-motor profile awake—A new tool for pre-, intra-, and postoperative assessment of sensory-motor function



Juliane Becker^{a,*}, Margit Jehna^b, Elisabeth Steinmann^a, Hubertus M. Mehdorn^a, Michael Synowitz^a, Gesa Hartwigsen^c

^a Department of Neurosurgery, University Hospital Schleswig–Holstein, Kiel, Schleswig–Holstein, Germany

^b Division of Neuroradiology, Vascular and Interventional Radiology, Department of Radiology, Medical University of Graz, Austria

^c Department of Neuropsychology, Max Planck Institute for Human Cognitive and Brain Sciences, Leipzig, Germany

ARTICLE INFO

Article history:

Received 28 January 2016

Received in revised form 17 May 2016

Accepted 22 May 2016

Available online 24 May 2016

Keywords:

Awake craniotomy

Neuropsychological monitoring

Sensory-motor function

Brain tumor

Non-language mapping

Direct cortical stimulation

ABSTRACT

Objectives: Awake craniotomy is a well-established procedure in surgery of intracranial tumors in eloquent areas. However, sufficiently standardized instruments for the assessment of sensory-motor function before, during and after the operation are currently lacking, despite their importance for evaluation of operative outcome.

Patients and methods: To address this issue, we designed a standardized assessment tool (the “sensory-motor profile awake scale”; SMP-a). The final scale consists of three motor sections (face, arm and leg) assessing both gross and fine motor skills and one sensory section. It differentiates between six grades of impairment and its tasks are applicable for intraoperative continuous monitoring of sensory-motor functions and supporting processes. We analyzed the data of 17 patients with intracranial tumors eligible for awake craniotomy who were preoperatively assessed with the SMP-a. In addition, we present an exemplary case.

Results: Our data support the assumption that the SMP-a is feasible in patients eligible for awake craniotomy, even in patients with symptoms of mild aphasia or more severe sensory-motor deficits caused by tumor recurrence. The exemplary case demonstrates the feasibility of repeated measures with the SMP-a in a tumor patient, including the adaption of tasks to the individual requirements of an intraoperative setting.

Conclusion: This exploratory study suggests that the SMP-a might be a feasible rating scale in patients with intracranial tumors. The flexibility of the scale enables individual adaption, but preserves the standardized scoring system to allow comparison between assessment dates, patients and, hopefully in the future, institutions. However, future studies are mandatory to provide data on the instrument’s diagnostic properties with respect to feasibility, objectivity, validity and reliability.

© 2016 Elsevier B.V. All rights reserved.

1. Introduction

Awake craniotomies are usually considered in patients with intracranial tumors located in or near motor areas to prevent cortical and/or subcortical damage which might lead to permanent neurologic deficits [1–5]. Direct cortical stimulation (DCS)

and mapping supports the surgeon with real-time intraoperative information and this way accounts for individual variability of cortical organization and neuroplastic changes [2,6]. The neurosurgeon must be aware of a wide range of possible intraoperative changes (e.g. slowing of movements, weakness, dysarthria or delayed response) since they guide the decision for resection [7]. A suitable tool for intraoperative monitoring should account for all these changes and support the neurosurgeon with valid and standardized that is, easy-to-interpret information during the operation.

So far, the available literature on awake craniotomy in motor eloquent areas provides either no information on the methods used to monitor endangered functions, or is restricted to the assessment of somatosensory and motor evoked potentials or unstandard-

* Corresponding author at: Department of Neurosurgery, University Hospital Schleswig–Holstein, Arnold–Heller–Straße 3, D–24105 Kiel, Germany.

E-mail addresses: juliane.becker@uksh.de (J. Becker), margit.jehna@medunigraz.at (M. Jehna), elisabeth.steinmann@uksh.de (E. Steinmann), Maximilian.Mehdorn@uksh.de (H.M. Mehdorn), Michael.Synowitz@uksh.de (M. Synowitz), hartwigsen@cbs.mpg.de (G. Hartwigsen).

Table 1
Rating scale for the assessment of complex sensory-motor functions in brain tumor patients undergoing awake craniotomy (sensory-motor profile awake; SMP-a).

SMP-a	□ preoperative □ intraoperative □ postoperative						notes
	severe impairment		medium impairment		no/slight impairment		
face	0	1	2	3	4	5	
frown forehead	0	1	2	3	4	5	
blink eyes	0	1	2	3	4	5	
wrinkle nose	0	1	2	3	4	5	
kissing lips	0	1	2	3	4	5	
laughing mouth	0	1	2	3	4	5	
mouthwash	0	1	2	3	4	5	
poke tongue out	0	1	2	3	4	5	
hand and arm							
hand:							
rock	0	1	2	3	4	5	
fine	0	1	2	3	4	5	
motor	0	1	2	3	4	5	
skills	0	1	2	3	4	5	
paper	0	1	2	3	4	5	
well	0	1	2	3	4	5	
finger tapping (oscillating)	0	1	2	3	4	5	
strength: shake hands	0	1	2	3	4	5	
rotate wrist	0	1	2	3	4	5	
flex elbow	0	1	2	3	4	5	
lift shoulder	0	1	2	3	4	5	
leg							
lift knee slightly	0	1	2	3	4	5	
adduct and abduct foot	0	1	2	3	4	5	
move toes	0	1	2	3	4	5	
strength: press foot against hand (io)	0	1	2	3	4	5	
sensory							
face	0	1	2	3	4	5	
fingers	0	1	2	3	4	5	
arm	0	1	2	3	4	5	
leg	0	1	2	3	4	5	
toes	0	1	2	3	4	5	

(io): first baseline in the operating room.

ized behavioral monitoring [1,8–16]. **Evoked potentials** provide only limited reliability and impairments of non-monitored muscles could not be avoided in previous studies [2,13,17–19]. Another limitation of this technique is that evoked potentials provide no information on the direct effects of the DCS as reflected in continuous voluntary movement during awake craniotomy [2]. The above-cited limitations probably partly result from the fact that sensory-motor function is a complex and integrated process, comprising mobilization itself and several adaptation processes [20–24]. This might explain why registration of simple muscle contractions alone is insufficient for obtaining optimal evaluation [18,25,26]. **Behavioral monitoring** as alternative assessment strategy during DCS might increase the reliability and validity of sensory-motor assessment [25,27–30]. However, previous studies solely applied non-standardized or semi-standardized approaches of instructing their patients. Moreover, it remains unclear, if and how baseline assessment of the patients' functions was done and how the surgery-induced alterations were rated and reported. Therefore, inter-study comparability is hardly existent. In addition, for evaluation of the surgical outcome, previous approaches often assessed very different functions on variable scales compared to the monitored and this way protected functions under surgery [29,30]. Consequently, a valid conclusion on the value of awake craniotomy appears to be difficult at this time.

Hence, a standardization of the monitoring procedure would be mandatory to improve intraoperative assessment of sensory-motor function and provide reliable postsurgical evaluation. However, to the best of our knowledge, no attempts have been made to adapt the existing neurological scales for the application in awake craniotomy so far.

To bridge this gap, we designed a rating scale suitable for this purpose. By this, we aimed at combining the advantages of existing neurological scales used for preoperative and postoperative evalu-

ation in this setting (i.e., the Modified Rankin Scale (mRS) [31], the British Medical Council Research Scale (MCRS) [32,33], the Canadian neurological scale (CNS) [34] and the Graded neurologic scale [35]). Furthermore we tried to overcome the following limitations of the previous scales: (a) *lack of practicability*: mRS, CNS and Graded neurologic scale provide rating sections not suitable for intraoperative setting (e.g., flexion of thighs toward trunk with knees flexed at 90°; activities of daily living: gait), (b) *lack of highly relevant functions*: missing fine motor skills and/or sensory functions in all four scales, (c) *lack of precision in item phrasing or scoring system*: i. e. mixing motor and sensory functions (mRS), vague phrasings in scoring system like “moderate disability, requiring some help” (mRS) or limitation to strength (MCRS) and no qualitative assessment of deceleration or imprecise movements (CNS).

2. Material and methods

The result of our efforts is the “sensory-motor profile awake scale” (SMP-a) as displayed in Table 1. Whenever possible, we adopted suitable items and scoring schedules from existing scales and adapted them for intraoperative settings.

Somatosensory function can be assessed with the SMP-a by touching the face and extremities and recording the respective description of the sensation by the patient. The same holds true for cortical stimulation-elicited dysesthesia reported by the patient (see also 11,19,30). Our standardized scoring system (including an explanation of the grades) is shown in Table 2. It consists of six points covering three steps of impairment. For assessment of strength and sensory function, the numbers follow a continuum similar to the MCRS.

Table 2
Scoring system for assessment of complex sensory-motor functions with the SPM-a.

Grade of functionality	Classification of impairment					
	severe		moderate		slight/no	
	grade 0	grade 1	grade 2	grade 3	grade 4	grade 5
Motor functions	no contraction or muscle movement	trace of contraction visible or palpable, but no movement at the joint	hint towards a purposeful movement visible	uncoordinated execution of a purposeful movement visible	purposeful movement visible, but deceleration or imprecise execution	no deficit, purposeful movement visible, normal strength
Sensory functions	numbness, no sensory function	isolated dysesthesia, but rest numb	more severe dysesthesia, transposed assignment of fingers	dysesthesia	slight dysesthesia	no deficit, normal sensory function

2.1. Recommendation for patient preparation and intraoperative monitoring

In accordance with other authors [36,37], we recommend an **in-depth preparation** of the patient to enhance her/his intraoperative compliance. Special attention should be paid to functions that are highly important for the patient's professional and social life [38]. The total number of tasks during surgery might be decreased if deficits are tolerated or specific functions are not endangered. For a precise baseline assessment, the patient executes the demanded movements after a verbal command with and without visual control and if necessary by imitation (f. e. aphasic patients or non-native speakers). In addition, the patient's report of any changes during the operation is explicitly encouraged [39–41]. In our experience, one should keep in mind that some tasks might be not feasible due to restrictions in the operating theater. For instance, "frown forehead" is often hindered by the Mayfield head holder and local anesthesia and "lift shoulder" might be impossible due to the positioning of the patient. A well-trained examiner can do the whole preparation within 20 min.

Intraoperatively, the baseline-profile or the last noted profile changes enable a fast judgment of any alterations at one glance. The SMP-a is used in our clinic in a surgery mode following the DCS protocol introduced by Duffau et al. for stimulation of cortical as well as subcortical areas without additional measurement of somatosensory or motor evoked potentials (SSEP/MEP) [42]. For mapping purposes the cortical stimulation is done simultaneously with the execution of one task at a time. The intraoperative selection of the tasks for each stimulated site strongly depends on the patient's individual neuroanatomical structure and the tumors relationship to functional areas. For example, during the mapping of areas with specified functions like motor areas of the hand, the assessment can focus only on finger tapping. For areas with negative DCS results, resection can be initiated and a selection of tasks can be performed repeatedly until impairments emerge. Then, again, the monitoring may focus on the altered functions. In accordance with other authors, we prefer a continuous monitoring of the selected tasks during mapping and resection [7,25,27,28,30,43]. To date, intraoperative data acquisition is performed in two ways. The first part of data acquisition focuses on several time points of interest, including pre-stimulation assessment, measurement after change of resection site, before an intraoperative MRI or at the end of the resection. This data can be recorded with different colors or symbols on the SMP-a sheet. As extensive mapping as well as continuous monitoring may generate a lot of information beyond the time points of interest mentioned above, this additional data is currently noted on an extra sheet with exact test time and results. This extra data can be condensed in a postoperative neuropsychological operation report.

Postoperatively, the tasks of the SMP-a can be assessed at different follow-up dates.

2.2. Subjects

We retrospectively analyzed the data of patients eligible for undergoing an awake craniotomy (from 2012 to 2015) at the University Hospital, Kiel. We included patients whose preoperative assessments took place within one to five days before surgery by a neuropsychologist (J. B. and E. S.) with the assessment scale introduced here. Additional data on language ability and medical information was taken from the records. Permission for study participation was routinely obtained from all patients during inpatient stay.

3. Results

3.1. Group analysis

Table 3 displays the subjects' characteristics (n = 17, 9 female). 29.4% of the assessed patients had language impairments: all of these had difficulties in comprehension, four of them in naming objects. 47.1% of our patients underwent an operation due to tumor recurrence. All patients were able to complete the baseline assessment of the SMP-a sufficiently. The results on the preoperative SMP-a baseline are displayed in **Fig. 1**. Preoperatively sensory-motor functions showed no or only slight impairments except for finger tapping with a medium functional impairment.

3.2. Exemplary case

The 40 year old patient was hospitalized with a recurrence of an oligodendroglioma WHO °II in the left central region (see **Fig. 2** part B). A former partial resection under general anesthesia two years earlier had induced a spastic hemiparesis of her right body side that was treated with intensive rehabilitation training.

She was prepared for an awake craniotomy with the SMP-a as displayed in **Fig. 2** on the left side. The assessment revealed considerable deficits in the gross and fine motor functions of the right arm and leg. Additionally, corresponding to functional-anatomical location of the lesions, the patient experienced impairments in sensory functions and reported a lack of "feeling the extremities in the deep". The same assessment without visual control (closed eyes) showed a strong deceleration of the motor functions of the right hand.

Table 3
Sample characteristics (N = 17).

Variable	n	%
Mean age in years	M = 50.7 (SD = 10.87) range = 32–68	
Karnofsky Performance Status 0–100 [52]	M = 76.8 (SD = 10.9) range = 40–100	
Operation due to tumor recurrence		
No	9	52.9
Yes	8	47.1
Tumor-lateralization		
Right	5	29.4
Left	12	70.6
Main tumor-localization		
Frontal lobe	7	41.2
Central sulcus	2	11.8
Temporal lobe	1	5.9
Parietal lobe	6	35.3
Insula	1	5.9
Tumor-histological diagnosis		
Anaplastic Astrocytoma	3	17.6
Glioblastoma	8	47.1
Oligodendroglioma	2	11.8
Diffuse fibrillary Astrocytoma	1	5.9
Anaplastic Oligoastrocytoma	1	5.9
Oligoastrocytoma	1	5.9
Metastases	1	5.9
WHO classification (n = 16)[53]		
Grade 2	4	23.5
Grade 3	4	23.5
Grade 4	8	47.1
Language ability ^a		
Impaired	5	29.4
Naming impaired	4	23.5
Comprehension impaired	5	29.4

^a assessed with the Aachen Aphasia Test (AAT; [54]).

4. Discussion

The existing literature on awake craniotomy provides either no information on the methods used to monitor endangered functions during the operation, or is restricted to the assessment of somatosensory and motor evoked potentials or unstandardized behavioral monitoring [1,8–16]. While mRS, MCSR, CNS and Graded neurological scale were used for evaluation of motor functions before and/or after the operation [17,18,25,27–30,39–41,44–46] none of them seem to be generally suitable for intraoperative assessment. These instruments were originally designed for other clinical cohorts and include impractical tasks like gait. Moreover, they lack important tasks like fine motor skills, mix functional sections and do not provide a sufficient scoring system for qualitative changes in motor functions. With the SMP-a, we aimed to overcome these limitations and combine their benefits like valuable items and a template for the scoring system. To the best of our knowledge, our study represents the first attempt to adapt the existing formal neurological scales for awake craniotomies.

The strengths of the SMP-a are its standardization of the intraoperative tasks and its use in the preoperative phase with an in depth-preparation of the patient and a detailed baseline assessment. This enhances the patient’s intraoperative compliance and ensures valid data to compare intraoperative and postoperative changes. Previous studies frequently reported that tumor-induced impairment of proprioception and/or fine motor skills often allows normal movements under visual control but reveals deficits with closed eyes [47]. Such differences can be assessed with the SMP-a baseline by comparing task performance with and without visual control. Thereby, the possibility of missing preoperative impair-

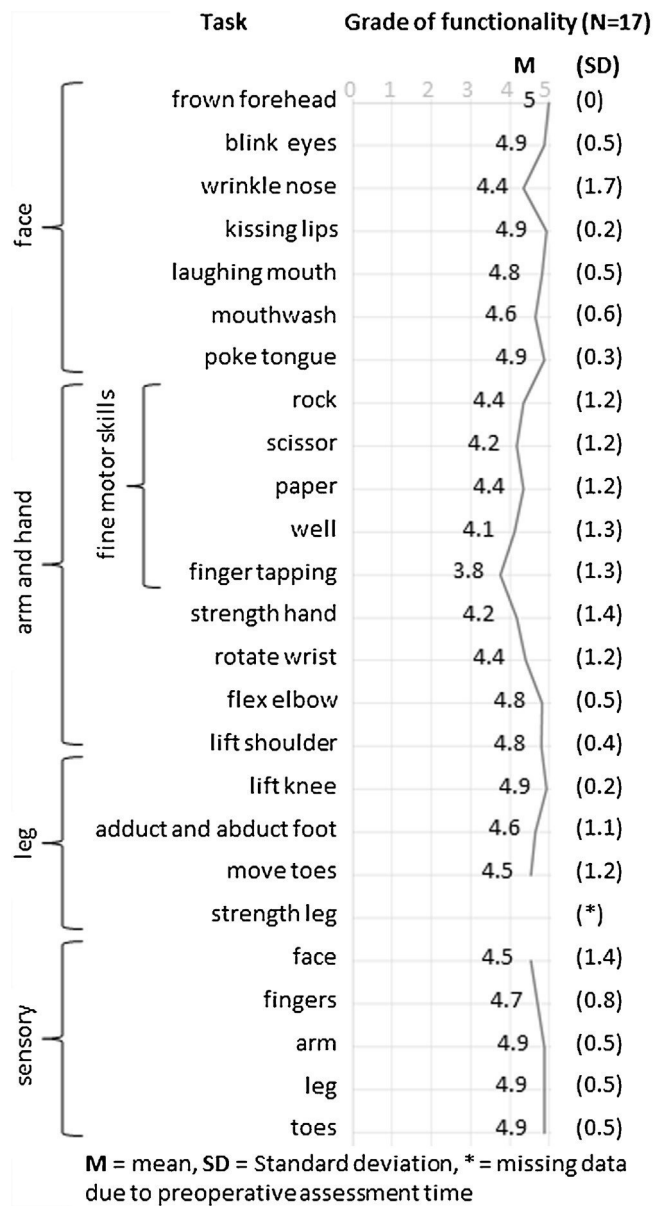


Fig. 1. Grade of functionality measured on the SMP-a for patients eligible for awake craniotomy (0/1 = severe impairment, 2/3 = medium impairment, 4/5 = slight/no impairment; data obtained from 17 patients).

ments might be substantially reduced, which could otherwise easily be mistaken for operation outcomes. Since the SMP-a enables rating of separate functions instead of providing summary scores, it is possible to reduce the intraoperatively used tasks to the individually requirements of the patient’s social and professional life, while still preserving a standardized rating (see also [38,48]). In addition, the tasks are doable with minimum effort and therefore are repeatedly performable. The simple profile character of the data and repetition of the same task during the operation (continuous monitoring) allows to notice any changes like positive and negative effects of DCS as well as short term plasticity [49]. Given that the SMP-a includes all motor tasks reported in the main literature on awake craniotomy [7,25,27,28,30] the neurosurgeon can be confident to probe all functions located along the “human homunculus” of one hemisphere [47,50]. Specific intraoperative events like deceleration or imprecise execution of the motor tasks [7] are represented in the rating scale of the SMP-a. The repeated measure of the same tasks after the operation allows

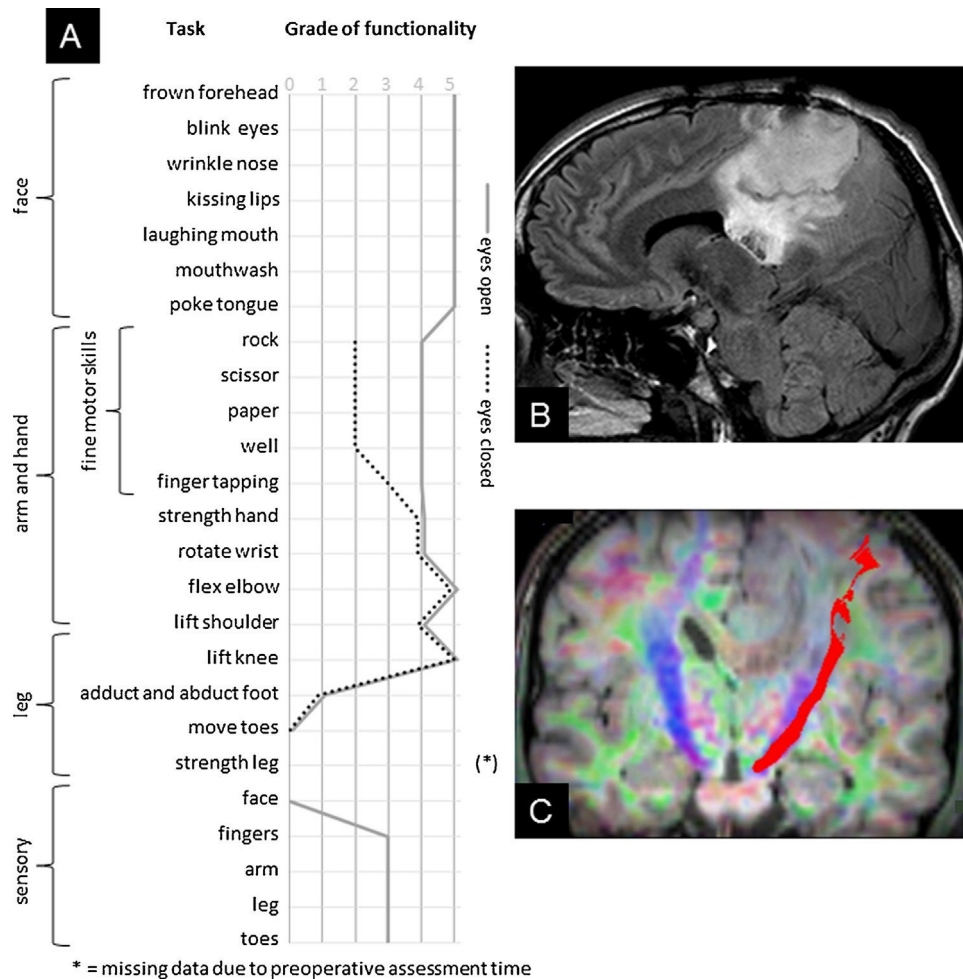


Fig. 2. Exemplary case. (A) Grade of functionality measured on the SMP-a with and without visual control. The assessment revealed a considerable latency for movements requiring an opening of the hand, despite visual control. Additionally, the patient reported numbness of the right side of the forehead as well as a strongly disturbed proprioception of the right sided extremities. Assessment with closed eyes (dotted line) revealed a strong increase in deceleration of fine motor skills (0/1 = severe impairment, 2/3 = medium impairment, 4/5 = slight/no impairment). (B) Preoperative sagittal T2-weighted MRI showing a tumor recurrence in the (post-) central region. (C) Preoperative fiber tracking of the pyramidal tract running in close vicinity to the tumor.

drawing a differentiated picture of the recovery of the intraoperatively monitored functions. By this, a survey of the intraoperative resection decisions and a comparison across patients and institutions becomes possible for the first time.

Our preliminary feasibility analysis shows the successful use of the SMP-a in 17 patients, 8 of them were operated due to tumor recurrence and 5 showed aphasic symptoms. Aphasic symptoms seem to be tolerable for the assessment of motor functions with the SMP-a, as it allows imitation of the tasks in case of comprehension deficits. For sensory functions, these impairments might have greater impact as for rating of these functions a reliable self-disclosure of the patient is necessary. Future studies should evaluate the influence of aphasic symptoms on the SMP-a.

Our preliminary data shows more severe impairments in fine motor tasks especially finger tapping than in facial motor functions or sensory functions in a cohort of patients eligible for awake craniotomy. These exploratory findings need to be reassessed in future studies. The presented exemplary case provides an illustration of the successful implementation of the SMP-a assessment during the inpatient stay in a patient with preoperative impairments. Compared to the neurological examination, the SMP-a baseline assessment revealed additional information useful for the awake craniotomy, i.e., the impact of visual control and proprioception on motor functions.” In addition, it shows the applicability of the

SMP-a in a patient with a tumor recurrence and thus more severe impairments as compared to the average awake patient. Future studies should address observations like a possible dissociation of motor function with or without visual control as well as the subjective feeling of weight before hemiparesis becomes apparent [39] as potentially useful information for awake craniotomy.

Although our proposed scale is more structured and comprehensive than the available ones, its ease of use during DCS needs to be evaluated beyond our subjective experience. A first hint that the SMP-a might be suitable for continuous monitoring without causing high exhaustion mimicking paresis is provided by the study of Goebel et al. [51] where monitoring was performed with the tasks of the SMP-a. In addition, a feasibility study carried out by an institution not familiar with this scale would be of great value and might help to improve the SMP-a significantly. Since a very limited number of patients is available for awake craniotomies, we were not able to provide data on objectivity (inter-rater reliability), validity (comparison with other neurological scales) or stability (test-retest reliability) to date. Additionally, the registration of the intraoperative monitoring data beyond specific time points via a pc and its collection in a database would enable further data analysis on relationships between standardized behavioral monitoring and different intraoperative variables like stimulation method (e.g., dif-

ferent electrode arrangements, frequency and amplitude), changes in blood pressure or other assessment methods like SSEP and MEP.

We hope that this preliminary study might encourage other centers to use this scale and provide data for a multi-center evaluation of its quality criteria. Because of the benefits of the SMP-a mentioned above, we are confident that the SMP-a represents a significant improvement as compared to previous techniques used in clinical settings so far. Nevertheless, further studies are necessary to evaluate the clinical relevance of a comprehensive tool like the SMP-a. These studies should test whether the SMP-a could serve the ultimately goal to evaluate outcome in awake craniotomy and compare data between institutions.

Conflicts of interest

None

Acknowledgements

The authors would like to thank an anonymous reviewer for helpful suggestions on the manuscript. We also thank Gesa Cohr, MD, for her support in picture editing. We thank Rauha Laurus, MA, PhD, for her feedback on an earlier version of this manuscript and we thank Christian Panke, PhD, for helpful discussions on this manuscript.

References

- [1] Y.N. Yordanova, S. Moritz-Gasser, H. Duffau, Awake surgery for WHO Grade II gliomas within noneloquent areas in the left dominant hemisphere: toward a supratotal resection. *Clinical article, J. Neurosurg.* 115 (2011) 232–239.
- [2] H. Duffau, Lessons from brain mapping in surgery for low-grade glioma: insights into associations between tumour and brain plasticity, *Lancet Neurol.* 4 (2005) 476–486.
- [3] A. Talacchi, B. Santini, F. Casagrande, F. Alessandrini, G. Zoccatelli, G.M. Squitani, Awake surgery between art and science. Part I: clinical and operative settings, *Funct. Neurol.* 28 (2013) 205–221.
- [4] K.R. Bulsara, J. Johnson, A.T. Villavicencio, Improvements in brain tumor surgery: the modern history of awake craniotomies, *Neurosurg. Focus* 18 (2005) e5.
- [5] J.G. Ojemann, J.W. Miller, D.L. Silbergeld, Preserved function in brain invaded by tumor, *Neurosurgery* 39 (1996) 253–258 (discussion 258–9).
- [6] N. Sanai, M.S. Berger, Operative techniques for gliomas and the value of extent of resection, *Neurotherapeutics* 6 (2009) 478–486.
- [7] A.G. Chacko, S.G. Thomas, K.S. Babu, R.T. Daniel, G. Chacko, K. Prabhu, V. Cherian, G. Korula, Awake craniotomy and electrophysiological mapping for eloquent area tumours, *Clin. Neurol. Neurosurg.* 115 (2013) 329–334.
- [8] D. Serletis, M. Bernstein, Prospective study of awake craniotomy used routinely and nonselectively for supratentorial tumors, *J. Neurosurg.* 107 (2007) 1–6.
- [9] N. Shinoura, A. Midorikawa, R. Yamada, T. Hana, A. Saito, K. Hiromitsu, C. Itoi, S. Saito, K. Yagi, Awake craniotomy for brain lesions within and near the primary motor area: a retrospective analysis of factors associated with worsened paresis in 102 consecutive patients, *Surg. Neurol. Int.* 4 (2013) 149.
- [10] T. Saito, Y. Muragaki, T. Maruyama, M. Tamura, M. Nitta, Y. Okada, Intraoperative functional mapping and monitoring during glioma surgery, *Neurol. Med. Chirurgical* 55 (2015) 1–13.
- [11] R.A. Danks, L.S. Aglio, L.D. Gugino, P.M. Black, Craniotomy under local anesthesia and monitored conscious sedation for the resection of tumors involving eloquent cortex, *J. Neurooncol.* 49 (2000) 131–139.
- [12] H. Ebel, M. Ebel, G. Schillinger, M. Klimek, J. Sobesky, N. Klug, Surgery of intrinsic cerebral neoplasms in eloquent areas under local anesthesia, *Minim. Invasive Neurosurg.* 43 (2000) 192–196.
- [13] K. Suzuki, T. Mikami, T. Sugino, M. Wanibuchi, S. Miyamoto, N. Hashimoto, N. Mikuni, Discrepancy between voluntary movement and motor-evoked potentials in evaluation of motor function during clipping of anterior circulation aneurysms, *World Neurosurg.* 82 (2014) e739–45.
- [14] M. Attari, S. Salimi, Awake craniotomy for tumor resection, *Adv. Biomed. Res.* 2 (2013) 63.
- [15] D.K. Gupta, P.S. Chandra, B.K. Ojha, B.S. Sharma, A.K. Mahapatra, V.S. Mehta, Awake craniotomy versus surgery under general anesthesia for resection of intrinsic lesions of eloquent cortex—a prospective randomised study, *Clin. Neurol. Neurosurg.* 109 (2007) 335–343.
- [16] P.M. Black, S.F. Ronner, Cortical mapping for defining the limits of tumor resection, *Neurosurgery* 20 (1987) 914–919.
- [17] J. Romstöck, R. Fahlbusch, O. Ganslandt, C. Nimsky, C. Strauss, Localisation of the sensorimotor cortex during surgery for brain tumours: feasibility and waveform patterns of somatosensory evoked potentials, *J. Neurol. Neurosurg. Psychiatr.* 72 (2002) 221–229.
- [18] F.B. Meyer, L.M. Bates, S.J. Goerss, J.A. Friedman, W.L. Windschitl, J.R. Duffy, W.J. Perkins, B.P. O'Neill, Awake craniotomy for aggressive resection of primary gliomas located in eloquent brain, *Mayo Clin. Proc.* 76 (2001) 677–687.
- [19] H. Duffau, New concepts in surgery of WHO grade II gliomas: functional brain mapping, connectionism and plasticity—a review, *J. Neurooncol.* 79 (2006) 77–115.
- [20] H. Duffau, Awake surgery for nonlanguage mapping, *Neurosurgery* 66 (2010) 523–529.
- [21] M. Trepel, *Neuroanatomie: Struktur Und Funktion*, 5th ed., Urban & Fischer in Elsevier, München, 2012.
- [22] G. Lafargue, H. Duffau, Awareness of intending to act following parietal cortex resection, *Neuropsychologia* 46 (2008) 2662–2667.
- [23] H.-J. Freund, The parietal lobe as a sensorimotor interface: a perspective from clinical and neuroimaging data, *Neuroimage* 14 (2001) S142.
- [24] M. Desmurget, A. Sirigu, Conscious motor intention emerges in the inferior parietal lobule, *Curr. Opin. Neurobiol.* 22 (2012) 1004–1011.
- [25] N. Shinoura, R. Yamada, T. Kodama, Y. Suzuki, M. Takahashi, K. Yagi, Preoperative fMRI, tractography and continuous task during awake surgery for maintenance of motor function following surgical resection of metastatic tumor spread to the primary motor area, *Minim. Invasive Neurosurg.* 48 (2005) 85–90.
- [26] N. Shinoura, M. Yoshida, R. Yamada, Y. Tabei, K. Saito, Y. Suzuki, Y. Takayama, K. Yagi, Awake surgery with continuous motor testing for resection of brain tumors in the primary motor area, *J. Clin. Neurosci.* 16 (2009) 188–194.
- [27] M.O. Pinsker, A. Nabavi, H.M. Mehdorn, Neuronavigation and resection of lesions located in eloquent brain areas under local anesthesia and neuropsychological-neurophysiological monitoring, *Minim. Invasive Neurosurg.* 50 (2007) 281–284.
- [28] D. Low, I. Ng, W.-H. Ng, Awake craniotomy under local anaesthesia and monitored conscious sedation for resection of brain tumours in eloquent cortex—outcomes in 20 patients, *Ann. Acad. Med. Singap.* 36 (2007) 326–331.
- [29] H. Duffau, L. Capelle, D. Denvil, N. Sichez, P. Gatignol, L. Taillandier, M. Lopes, M.-C. Mitchell, S. Roche, J.-C. Muller, A. Bitar, J.-P. Sichez, R. van Effenterre, Usefulness of intraoperative electrical subcortical mapping during surgery for low-grade gliomas located within eloquent brain regions: functional results in a consecutive series of 103 patients, *J. Neurosurg.* 98 (2003) 764–778.
- [30] I.R. Whittle, S. Borthwick, N. Haq, Brain dysfunction following 'awake' craniotomy, brain mapping and resection of glioma, *Br. J. Neurosurg.* 17 (2003) 130–137.
- [31] R. Bonita, R. Beaglehole, Recovery of motor function after stroke, *Stroke* 19 (1988) 1497–1500.
- [32] T. Paternostro-Sluga, M. Grim-Stieger, M. Posch, O. Schuhfried, G. Vacariu, C. Mittermaier, C. Bittner, V. Fialka-Moser, Reliability and validity of the Medical Research Council (MRC) scale and a modified scale for testing muscle strength in patients with radial palsy, *J. Rehabil. Med.* 40 (2008) 665–671.
- [33] L.C.M. Pereira, K.M. Oliveira, G.L. L' Abbate, R. Sugai, J.A. Ferreira, L.A. Motta, Outcome of fully awake craniotomy for lesions near the eloquent cortex: analysis of a prospective surgical series of 79 supratentorial primary brain tumors with long follow-up, *Acta Neurochir.* 151 (2009) 1215–1230.
- [34] R. Côté, R.N. Battista, C. Wolfson, J. Boucher, J. Adam, V. Hachinski, The canadian neurological scale: validation and reliability assessment, *Neurology* 39 (1989) 638–643.
- [35] R.J. Adams, K.J. Meador, K.D. Sethi, J.C. Grotta, D.S. Thomson, Graded neurologic scale for use in acute hemispheric stroke treatment protocols, *Stroke* 18 (1987) 665–669.
- [36] J.-W. Potters, M. Klimek, Awake craniotomy: improving the patient's experience, *Curr. Opin. Anaesthesiol.* (2015).
- [37] A.L. Benabid, Futile circuits in functional neurosurgery, in: H. Duffau (Ed.), *Brain Mapping: From Neural Basis of Cognition to Surgical Applications*, Springer WienNewYork, Vienna, New York, 2011, pp. 389–392.
- [38] A. Fernández Coello, S. Moritz-Gasser, J. Martino, M. Martinoni, R. Matsuda, H. Duffau, Selection of intraoperative tasks for awake mapping based on relationships between tumor location and functional networks, *J. Neurosurg.* 119 (2013) 1380–1394.
- [39] A. Szelényi, L. Bello, H. Duffau, E. Fava, G.C. Feigl, M. Galanda, G. Neuloh, F. Signorelli, F. Sala, Intraoperative electrical stimulation in awake craniotomy: methodological aspects of current practice, *Neurosurg. Focus* 28 (2010) E7.
- [40] M.D. Taylor, M. Bernstein, Awake craniotomy with brain mapping as the routine surgical approach to treating patients with supratentorial intraaxial tumors: a prospective trial of 200 cases, *J. Neurosurg.* 90 (1999) 35–41.
- [41] H.J. Reulen, U.D. Schmid, J. Ilmberger, W. Eisner, K. Bise, Tumorchirurgie im Sprachkortex in Lokalanästhesie. Neuropsychologisches und neurophysiologisches Monitoring während Operationen in der dominanten Hirnhälfte, *Nervenarzt* 68 (1997) 813–824.
- [42] H. Duffau, Awake mapping and tumor surgery, in: H. Duffau (Ed.), *Brain Mapping: From Neural Basis of Cognition to Surgical Applications*, Springer WienNewYork, Vienna, New York, 2011, pp. 305–318.
- [43] H. Duffau, *Brain Mapping: From Neural Basis of Cognition to Surgical Applications*, Springer WienNewYork, Vienna, New York, 2011.

- [44] K. Roessler, M. Donat, R. Lanzenberger, K. Novak, A. Geissler, A. Gartus, A.R. Tahamtan, D. Milakara, T. Czech, M. Barth, E. Knosp, R. Beisteiner, Evaluation of preoperative high magnetic field motor functional MRI (3 Tesla) in glioma patients by navigated electrocortical stimulation and postoperative outcome, *J. Neurol.* 76 (2005) 1152–1157.
- [45] G.E. Keles, D.A. Lundin, K.R. Lamborn, E.F. Chang, G. Ojemann, M.S. Berger, Intraoperative subcortical stimulation mapping for hemispherical perirolandic gliomas located within or adjacent to the descending motor pathways: evaluation of morbidity and assessment of functional outcome in 294 patients, *J. Neurosurg.* 100 (2004) 369–375.
- [46] M.O. Ulu, N. Tanriöver, F. Ozlen, G.Z. Sanus, T. Tanriverdi, C. Ozkara, M. Uzan, Surgical treatment of lesions involving the supplementary motor area: clinical results of 12 patients, *Turk Neurosurg.* 18 (2008) 286–293.
- [47] M.R. Longo, P. Haggard, An implicit body representation underlying human position sense, *Proc. Natl. Acad. Sci. U. S. A.* 107 (2010) 11727–11732.
- [48] A. Talacchi, B. Santini, M. Casartelli, A. Monti, R. Capasso, G. Miceli, Awake surgery between art and science. Part II: language and cognitive mapping, *Funct. Neurol.* 28 (2013) 223–229.
- [49] E. Mandonnet, Intraoperative electrical mapping: advances, limitations and perspectives, in: H. Duffau (Ed.), *Brain Mapping: From Neural Basis of Cognition to Surgical Applications*, Springer WienNewYork, Vienna, New York, 2011, pp. 101–108.
- [50] R.F. Becker, *The cerebral cortex of man*. by wilder penfield and theodore rasmussen. the macmillan company, New York N.Y. 1950. 248 pp, *Am. J. Phys. Anthropol.* 11 (1953) 441–444.
- [51] S. Goebel, A. Nabavi, S. Schubert, H.M. Mehdorn, Patient perception of combined awake brain tumor surgery and intraoperative 1.5-T magnetic resonance imaging, *Neurosurgery* 67 (2010) 594–600.
- [52] V. Crooks, S. Waller, T. Smith, T.J. Hahn, The use of the Karnofsky Performance Scale in determining outcomes and risk in geriatric outpatients, *J. Gerontol.* 46 (1991) M139–44.
- [53] D.N. Louis (Ed.), *WHO Classification of Tumours of the Central Nervous System*, 4th ed., Distributed by WHO Press, World Health Organization Geneva Switzerland, 2007.
- [54] *Aachener aphasie Test (AAT): handanweisung*, Verl. für Psychologie Hogrefe, Göttingen, 1983.

Appendix III

Glioblastoma in hemihydranencephaly: preoperative and postoperative language ability of the right hemisphere

Juliane Becker¹ · Margit Jehna² · Naomi Larsen³ ·
Michael Synowitz¹ · Gesa Hartwigsen⁴

Received: 29 February 2016 / Accepted: 25 April 2016
© Springer-Verlag Wien 2016

Abstract We present the first case report describing a craniotomy for a glioblastoma in a patient with hemihydranencephaly (HHE). Ten years ago our patient had average cognitive and language functions, indicating very good adaption of his single right hemisphere. Due to the tumour he developed a deceleration, deficits in language functions and mild impairments of basic cognitive functions. Further neuroplastic reorganisations of his right hemisphere in response to the tumour growth are discussed. The favourable postoperative outcome supported the decision for careful tumour resection in this patient with HHE.

Keywords Neuropsychological diagnostic · Hemihydranencephaly · Neurosurgery · Brain tumour · Hemisphere agenesis

Electronic supplementary material The online version of this article (doi:10.1007/s00701-016-2825-1) contains supplementary material, which is available to authorised users.

✉ Juliane Becker
juliane.becker@uksh.de

¹ Department of Neurosurgery, University Hospital Schleswig–Holstein, Arnold-Heller-Straße 3, 24105 Kiel, Germany

² Division of Neuroradiology, vascular and interventional Radiology, Department of Radiology, Medical University of Graz, Graz, Austria

³ Department of Radiology and Neuroradiology, University Hospital Schleswig–Holstein, Kiel, Germany

⁴ Department of Neuropsychology, Max Planck Institute for Human Cognitive and Brain Sciences, Leipzig, Germany

Introduction

Hemihydranencephaly (HHE) describes the condition of one brain hemisphere being absent due to prenatal vascular complications. So far, only nine cases have been reported in the literature [10]. The space of the missing hemisphere is filled with a cyst containing cerebrospinal fluid, minimal residual neurons, glial tissue and remaining blood vessels [7]. Central nervous structures fed by the vertebra-basilar blood system like the basal ganglia, pons, medulla, cerebellum, meninges and falx are not affected [10]. Glioblastoma multiforme (GBM) represents a malignant primary brain tumour affecting only about 3 of 100,000 adults per year [3]. The growth of a GBM causes multiple physical and cognitive symptoms and its treatment with surgery is the first line therapy [2]. The case we report is the first illustration of a treatment of a GBM in HHE so far and a follow-up on the probably oldest patient alive with HHE [12].

Case report

The 48-year-old patient with a known history of HHE [12] was diagnosed with a GBM in the right frontal lobe (Fig. 1). The tumour size was about 5.2 × 6.1 cm with cystic and solid portions and surrounded by oedema in the apical direction to the tumour. Despite a considerable deceleration, the patient was awake, oriented and compliant in the neurological examination. He only presented the formerly diagnosed spastic hemiparesis of the right side. The patient complained about a loss of physical strength within the last 4 weeks, but no recent alteration of the hemiparesis. He had to wear varifocal glasses for about

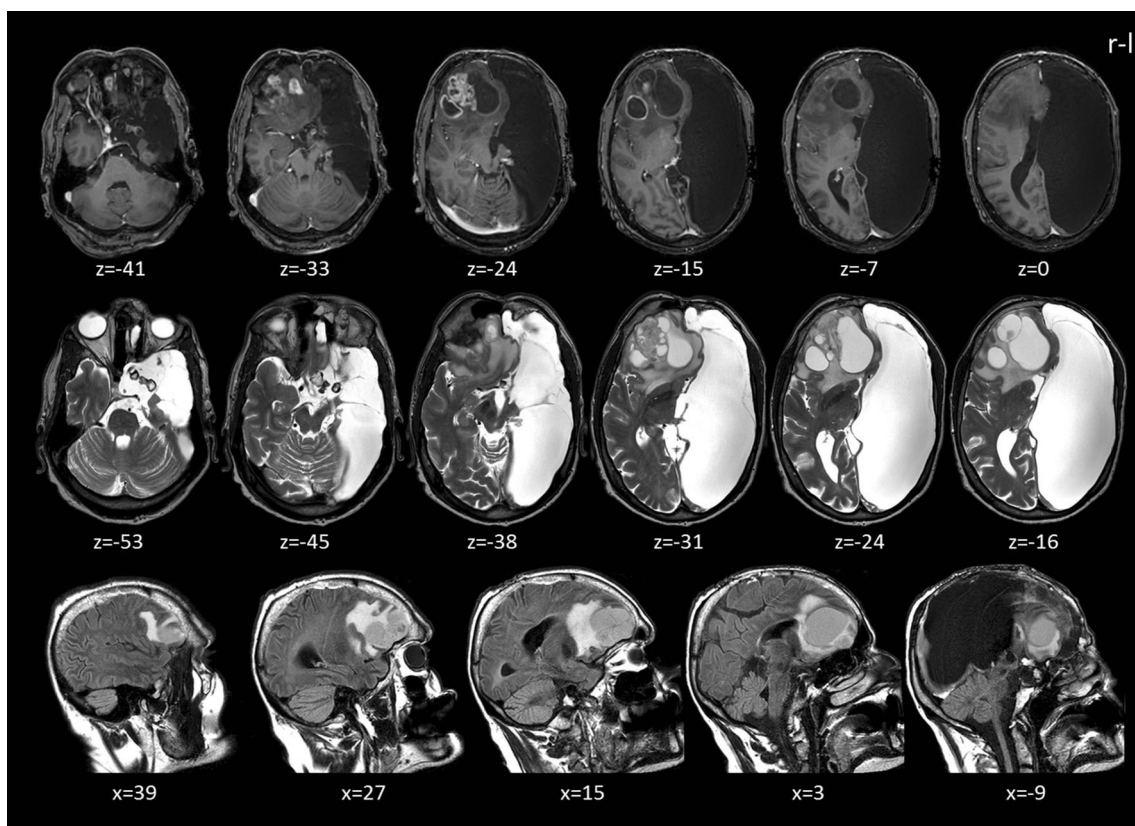


Fig. 1 Preoperative magnetic resonance imaging (MRI) scans in transverse and sagittal views showing the defect of the left hemisphere and the GBM in the right frontal lobe surrounded by oedema (frontal midline shift about 1.7 cm). *Top row:* T1-weighted images (voxel size, $1 \times 1 \times 2$ mm; TR = 7.37 ms; TE = 3.576 ms; field of

view = 224×224 mm², flip angle, 8). *Middle row:* T2-weighted images (voxel size, $0.43 \times 0.43 \times 2.60$ mm; TR = 5,501 ms; TE = 80 ms; field of view = 512×512 mm², flip angle, 90). *Bottom row:* T2-weighted FLAIR images (voxel size, $0.45 \times 0.45 \times 3$ mm; TR = 12,000 ms; TE = 160 ms; field of view = 512×512 mm², flip angle, 90)

4 years. A semi-structured interview for eyesight revealed new impairments of basic and spatial visual functions after approximately 2 years [9].

Functional magnetic resonance imaging (fMRI) of the left foot showed BOLD-signal alterations in areas similar to that observed in healthy subjects (Fig. 2) [11]. However, abnormal activation for foot movement was found near the hand knob in the precentral gyrus. A deterministic tractography reconstructed the pyramidal tracts in distance to the tumour-induced oedema (Fig. 2 middle and bottom rows). The fMRI of language could not be interpreted due to the patient's deceleration.

Preoperative cognitive and language ability

The patient complained of perceived personality changes in the last 7 weeks. Additionally, he reported a decline in memory functions and recently occurring problems in pronunciation for the last 3 months. His pre-morbid cognitive functional level was estimated to be 90 IQ points [6]. A cognitive screening tool, the Montreal Cognitive Assessment (MoCA) [8], revealed an overall result of 17 out of 30 points, indicating

mild cognitive impairment (for details, see Table 1). In summary, the patient showed preoperative impairments in tasks involving executive functions, attention, verbal fluency, abstraction and memory.

In contrast to a previous assessment 10 years previously [12], the standardised diagnostic of aphasia [5] revealed clear symptoms of an aphasic disorder and signs of dysarthria (see Table 2). His spontaneous speech was repeatedly slurred, but showed no neologisms, semantic or phonematic paraphasic errors or repeated speech. In summary, the patient had mild impairments of receptive, expressive and academic verbal skills.

Surgical procedure

The strategy for microsurgical removal of the mass was to minimise frontal lobe alteration and associated risk of neurological deterioration. Therefore, a right-sided supra-orbital approach was chosen. Insufficient compliance of the patient prevented an awake craniotomy. After opening the dura the tumour appeared clearly distinct from the

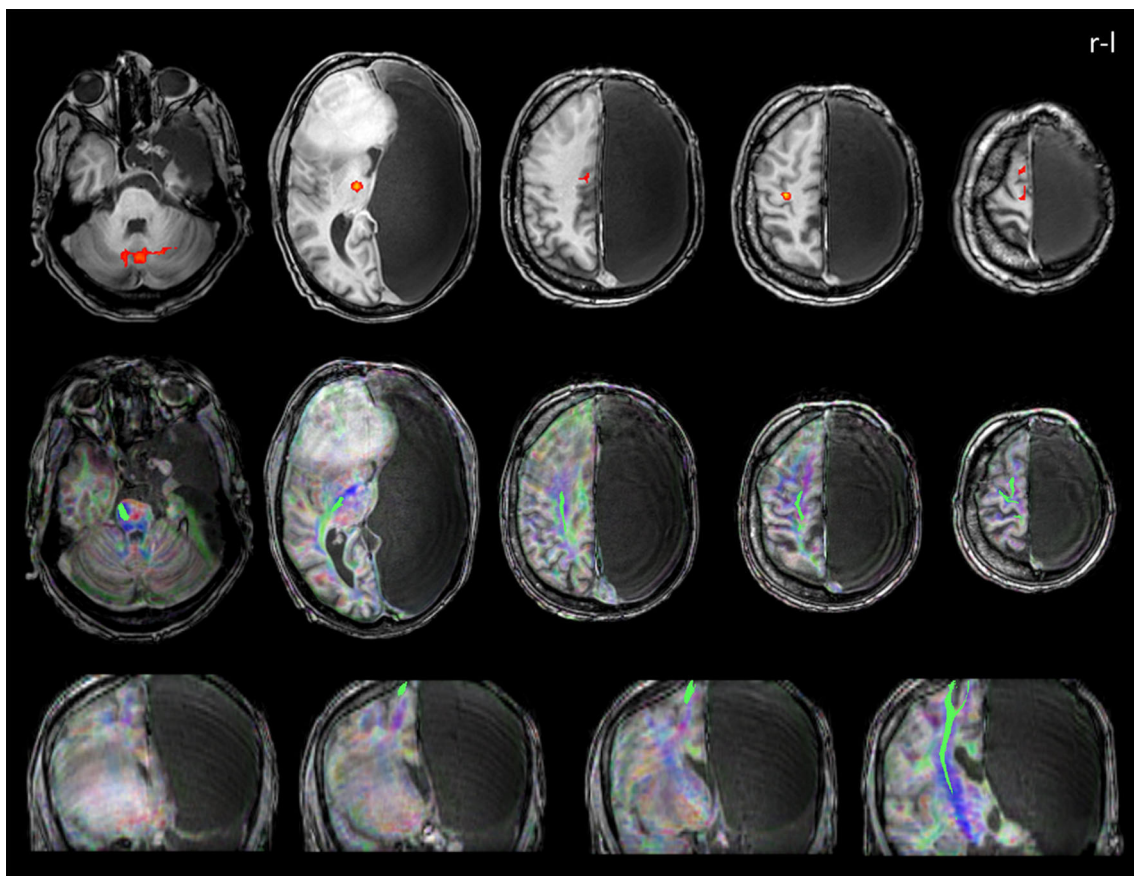


Fig. 2 *Top row:* Functional MRI for movement of the left foot (*t*-test, MC) showing BOLD-signal alterations (*red*) in the cerebellum (bilateral), right thalamus, right anterior cingulate cortex, right precentral gyrus, and the right supplementary motor cortex (block design with six active and six passive conditions, 96 volumes; voxel size, $3.3 \times 3.3 \times 3$ mm; TR = 2,500 ms; TE = 33 ms; field of view = 224×224 mm²; flip angle, 90). *Middle and bottom rows:* Deterministic tractography results from

diffusion-weighted images for the pyramidal tracts (*green*; seed: inferior cerebellar peduncle) in transverse and coronal views (FA-colour-coded MRI registered onto a T1-TFE scan with TR/TE: 7/3.4, $1 \times 1 \times 1$ mm³ voxel size covering 104 slices (field of view, 224×224 ; 32 directions; *b* value = 1,000 s/mm²; 52 slices; voxel size, $2 \times 2 \times 2$ mm, no gap; TR = 5,234 ms; TE = 69 ms; field of view = 512×512 mm²; flip angle, 90)

brain tissue in a grey-bluish (livid) discoloration. The tumour resection proceeded without complications: solid masses were resected completely and all cystic structures were opened. No resection beyond the tumour borders was performed to avoid the high risk of permanent neurological impairment in this patient. There were no intra-operative pictures available.

Postoperative surgical outcome

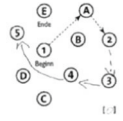
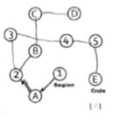


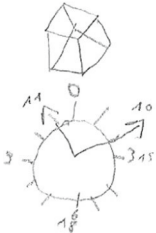

MRI with contrast agent revealed minor contrast enhancements at the margin dorso-laterally to the resection cavity and a bold ring-like enhancement at the right frontal base indicating small residual tumour parts (Fig. 3). Postoperative diffusion tensor imaging (DTI) showed that the pyramidal tracts were passing the rear corona radiate (Fig. 4). The capsula interna as well as the cingulum were visually intact on MRI. The right hemispheric arcuate fasciculus and the

inferior fronto-occipital fasciculus (IFOF) could not be followed to their origin in anterior direction due to oedema. Our Supplementary Material (ESM 1) displays additional probabilistic tractography results of main fibre tracts. Aside from slight subjectively reported postoperative physical weakness (circulatory disturbances, balance), the neurological exam revealed no novel postoperative sensory-motor deficits. The patient reported no alteration of the hemiparesis in comparison to the preoperative impairment and no changes in hearing and vision [9]. In addition, there were no more signs of deceleration.

Postoperative cognitive and language ability

Six days after the resection, the patient no longer reported problems in memory or pronunciation. It also negated changes in the patient's ability to concentrate. With 19

Table 1 Preoperative and postoperative assessment results for basic cognitive functioning with the MoCA [7]

Items	preoperative raw score	postoperative raw score	Δ	max.
Visual-spatial and executive functions				
alternating Trail Making	 0	 0	=	1
visuo-construction (rectangle)	 1	 0	↓	1
clock drawing test	 2	 3	↑	3
Naming	3	2	↓	3
Attention				
digit span	2	2	=	2
vigilance	0	1	↑	1
serial 7s	2	2	=	3
Language				
sentence repetition	0	0	=	2
verbal fluency	0	0	=	1
Abstraction	0	2	↑	2
Memory: Delayed recall				
free recall	0	1	↑	5
cued recall ^a	(0)	(2)		
multiple choice ^a	(1)	(2)		
Orientation	5	5	=	6
wrong item	exact date	day of the week		
Sum Score +1 for education fewer than 12 years	17	19		30

Δ pre-post comparison; max. (achievable) maximum score; ^a not relevant for final sum score

of 30 points, the postoperative MoCA (alternative version 2) [8] still indicated mild cognitive impairment (Table 1). In contrast to the preoperative assessment, the patient was

not able to solve the visual-constructive item. On the contrary, the clock-drawing-task was easily carried out this time. One error was made in the naming task

Table 2 Preoperative and postoperative language functions assessed with the Aachen Aphasia Test (AAT [5])

Subtest of AAT	Preoperative		Postoperative		Δ	max.
	Raw score	Classification ^a	Raw score	Classification ^a		
Token test	35	Impaired	48	Unimpaired	↑	50
Reading	27	Marginal	29	Unimpaired	↑	30
Writing to dictation	28	Unimpaired	30	Unimpaired	↑	30
Naming	106	Impaired	114	Unimpaired	↑	120
Auditory comprehension	43	Impaired	41	Impaired	↓	60
Reading comprehension	49	Impaired	47	Impaired	↓	60

Δ pre-post comparison, max. (achievable) maximum score

^a In comparison to other aphasic patients according to the manual of the AAT

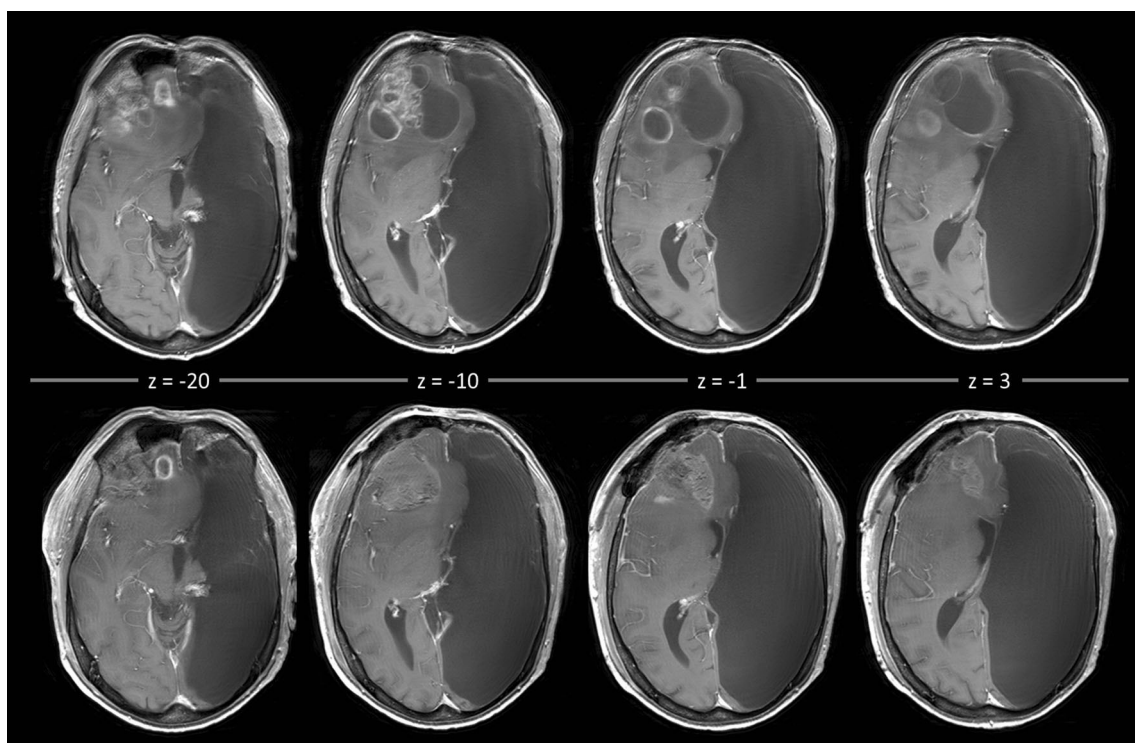


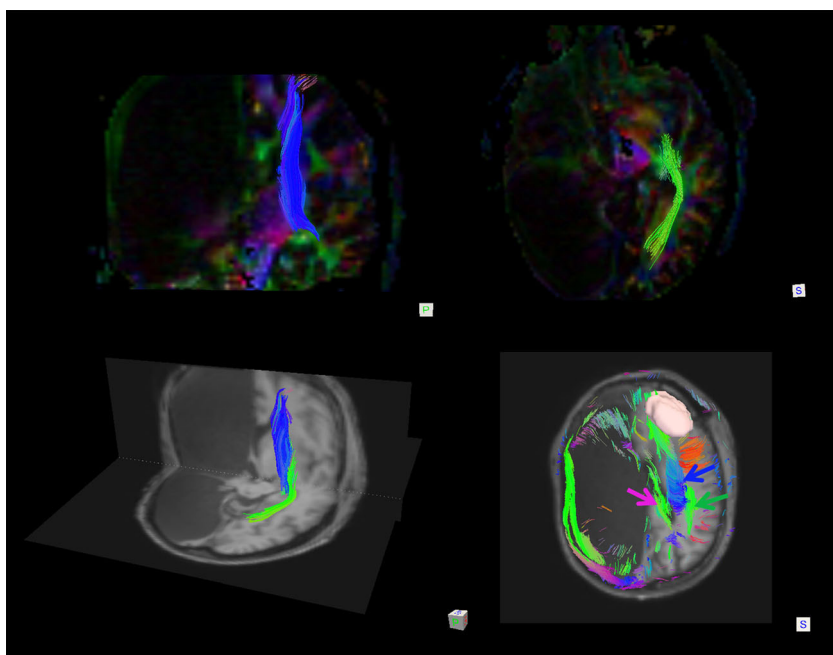
Fig. 3 Comparison of preoperative and postoperative MRI scans *Top row*: Preoperative T1-weighted MRI with contrast agents (voxel size, $0.43 \times 0.43 \times 5$). *Bottom row*: Postoperative T1-weighted MRI with contrast agents (voxel size, $0.43 \times 0.43 \times 5$) 1 day after the operation

displaying the slightly regressive midline shift. The resection cavity exhibited hemorrhagic areas, was partially filled with fluid and showed slight infarctions at the cavity margins (not displayed here)

postoperatively. In contrast to the preoperative results, the patient was able to solve the vigilance item correctly, indicating clear improvement of the deceleration. In addition, he showed better performance on the assessment of abstraction and memory. Moreover, the patient exhibited

no more symptoms of dysarthria (spontaneous speech was no longer slurred and no new aphasic symptoms occurred). Improvements in expressive and academic verbal skills occurred. Mild impairments of receptive language were still present (Table 2).

Fig. 4 Postoperative deterministic tractography. *Top row*: Pyramidal tract (blue, coronal view) and inferior fronto-occipital fasciculus (IFOF) (green, transverse view) displayed on the background of the colour-coded FA map and selected by slice filtering. *Bottom row, left*: Display of pyramidal tracts (blue) and IFOF (green) (selected by slice filtering) in coronal and transverse view from posterior view from posterior overlaid on a T1-weighted MRI scan registered to the DTI native space. *Bottom row, right*: Reconstruction of the tumour volume (rosy), the cingulum (pink), pyramidal tracts (blue) and the right hemispheric arcuate fasciculus (green). The tracts were selected by slice filtering and are marked by arrows



Immediately after the patient's release, radio-chemotherapy according to the Stupp regimen was started [11]. The treatment is not yet completed, but to date well tolerated by the patient without major changes in cognitive or physical status.

Discussion

Here, we present the first report of a craniotomy of a right frontal GBM in a patient with HHE. Despite the high risk of causing permanent neurological deficits during an intracranial tumour resection in HHE, this case documents an almost complete tumour resection with a good outcome regarding language and basic cognitive functions. In contrast to the patient's normal cognitive functionality 10 years earlier [12], he presented preoperatively with a severe deceleration, mild impairments in basic cognitive functions (memory, attention, executive functions) and mild impairments in receptive, expressive and academic verbal skills. One might speculate that these new symptoms were tumour induced. The deceleration vanished after tumour resection and some basic cognitive functions including language functions improved. No severe cognitive deficits emerged postoperatively.

Cognitive performance in HHE is generally judged as relatively normal, independent of which hemisphere is affected [1, 10]. This is explained by the fact that already in utero, no corresponding hemisphere is present for a longer time period and the full "functional potential of a single cerebral hemisphere" might be able to develop [4, 10]. HHE can be considered as the earliest time point for a cerebral lesion inducing neuroplastic changes, which likely differ from the observed reorganisations in patients with hemispherectomy [10] or patients with intracranial tumours. To date, however, it remains unclear whether patients with HHE show further plastic changes after additional lesions and how much adaptation can be achieved by one hemisphere. It may be speculated for the reported case that after prenatal insult, formerly left hemispheric functions were successfully organised in the intact right hemisphere, which might explain his relatively normal cognitive ability 10 years ago. This is supported by the respective fMRI and tractography results of our case, indicating nearly normal functional areas and courses of assessed tracts in comparison to healthy subjects. The later tumour growth might have induced additional neuronal reorganisation in this patient. The formerly good adaptation to the missing hemisphere could have provided capacity for additional plasticity. This might explain the relatively mild cognitive and language impairments before and after the operation. The divergent BOLD signal for the fMRI of the left leg near the hand knob might be regarded as one indication for a divergent functional-neuroanatomical proportion.

In general, in case of a missing hemisphere, it can be speculated that this reduces the brain's ability to compensate for tumour and treatment-induced cognitive deficits compared to patients without HHE. In addition, we might observe unique functional-anatomical relationships which have been formed during early development and were modulated later by additional occurrence of a GBM. This draws special attention to a good balance between a conservative resection and maximal tumour resection. The operative outcome of our case suggests that even if only one hemisphere is functioning, a careful tumour resection can be performed.

Conclusions

Although neurosurgical extirpation of an intracranial tumour in a patient with HHE has a high risk for permanent neurological impairments, this case report documents an almost complete tumour resection (frontal lobe) with a good outcome regarding language and basic cognitive functions. The results of our case study support the assumption of a strong potential for adaptive plasticity in the human brain. Specifically, our results suggest that even in the absence of the entire left hemisphere, the right hemisphere was able to develop language functions and reorganise them after occurrence of a GBM.

Acknowledgments We would like to thank Thomas Lindner, MSc, for his help in data acquisition and Christian Panke, PhD, for his helpful comments on the draft of this manuscript.

Compliance with ethical standards All procedures performed in this study were in accordance with the ethical standards of the institutional and/or national research committee and with the 1964 Helsinki declaration and its later amendments or comparable ethical standards.

Conflicts of interest The authors declare that they have no conflicts of interest.

Patient consent The patient gave written informed consent for publication of his data.

Funding No funding was received for this research.

References

1. Altschuler EL, Matsumura B, Capoor J, Weinschelbaum K, Ghuznavi H (2005) Left-hemispheric hydranencephaly with less favorable findings. *Pediatrics* 116(6):1603–1604, author reply 1604
2. Duffau H (2011) Brain mapping. From neural basis of cognition to surgical applications. Springer, Vienna
3. Gallego O (2015) Nonsurgical treatment of recurrent glioblastoma. *Curr Oncol* 22(4):e273–e281 (Toronto, Ont)

4. Hassanein SMA, Abbas YA, Monib AM, Alfay E, Mohsen S (2011) Hemihydranencephaly syndrome: case report and review. *Dev Neurorehabil* 14(5):323–329
5. Huber W, Poeck K, Weniger D, Willmes K (1983) Aachener Aphasie Test (AAT). Hogrefe, Göttingen
6. Jahn T, Beitlich D, Hepp S, Knecht R, Köhler K, Ortner C, Sperger E, Kerkhoff G (2013) Drei Sozialformeln zur Schätzung der (prä-morbiden) Intelligenzquotienten nach Wechsler. *Z Neuropsychol* 24(1):7–24
7. Mori K (1985) Anomalies of the central nervous system. *Neuroradiology and neurosurgery. Neuroradiological atlases.* Thieme-Stratton, New York
8. Nasreddine ZS, Phillips N, Chertkow H, Rossetti H, Lacritz L, Cullum M, Weiner M (2012) Normative data for the Montreal cognitive assessment (MoCA) in a population-based sample. *Neurology* 78(10):765–766
9. Niedeggen M, Jörgens S (2005) Visuelle Wahrnehmungsstörungen. *Fortschritte der Neuropsychologie*, Bd. 5. Hogrefe, Göttingen
10. Pavone P, Nigro F, Falsaperla R, Greco F, Ruggieri M, Rizzo R, Praticò AD, Pavone L (2013) Hemihydranencephaly: living with half brain dysfunction. *Ital J Pediatr* 39:3
11. Schneider F, Fink GR (2007) Funktionelle MRT in psychiatrie und neurologie. Springer, Heidelberg
12. Ulmer S, Moeller F, Brockmann MA, Kuhtz-Buschbeck JP, Stephani U, Jansen O (2005) Living a normal life with the nondominant hemisphere: magnetic resonance imaging findings and clinical outcome for a patient with left-hemispheric hydranencephaly. *Pediatrics* 116(1):242–245

Supplemental material for

Glioblastoma in Hemihydranencephaly: pre- and postoperative language ability of the right hemisphere

submitted to *Acta Neurochirurgica*

Authors:

Juliane Becker ¹, MA; Margit Jehna ², MA, PhD; Naomi, Larsen ³, MD; Michael Synowitz ¹, MD; Gesa Hartwigsen ⁴, MA, PhD

1 Department of Neurosurgery, University Hospital Schleswig–Holstein, Kiel, Germany

2 Division of Neuroradiology, vascular and interventional Radiology, Department of Radiology, Medical University of Graz, Austria

3 Department of Radiology and Neuroradiology, University Hospital Schleswig–Holstein, Kiel, Germany

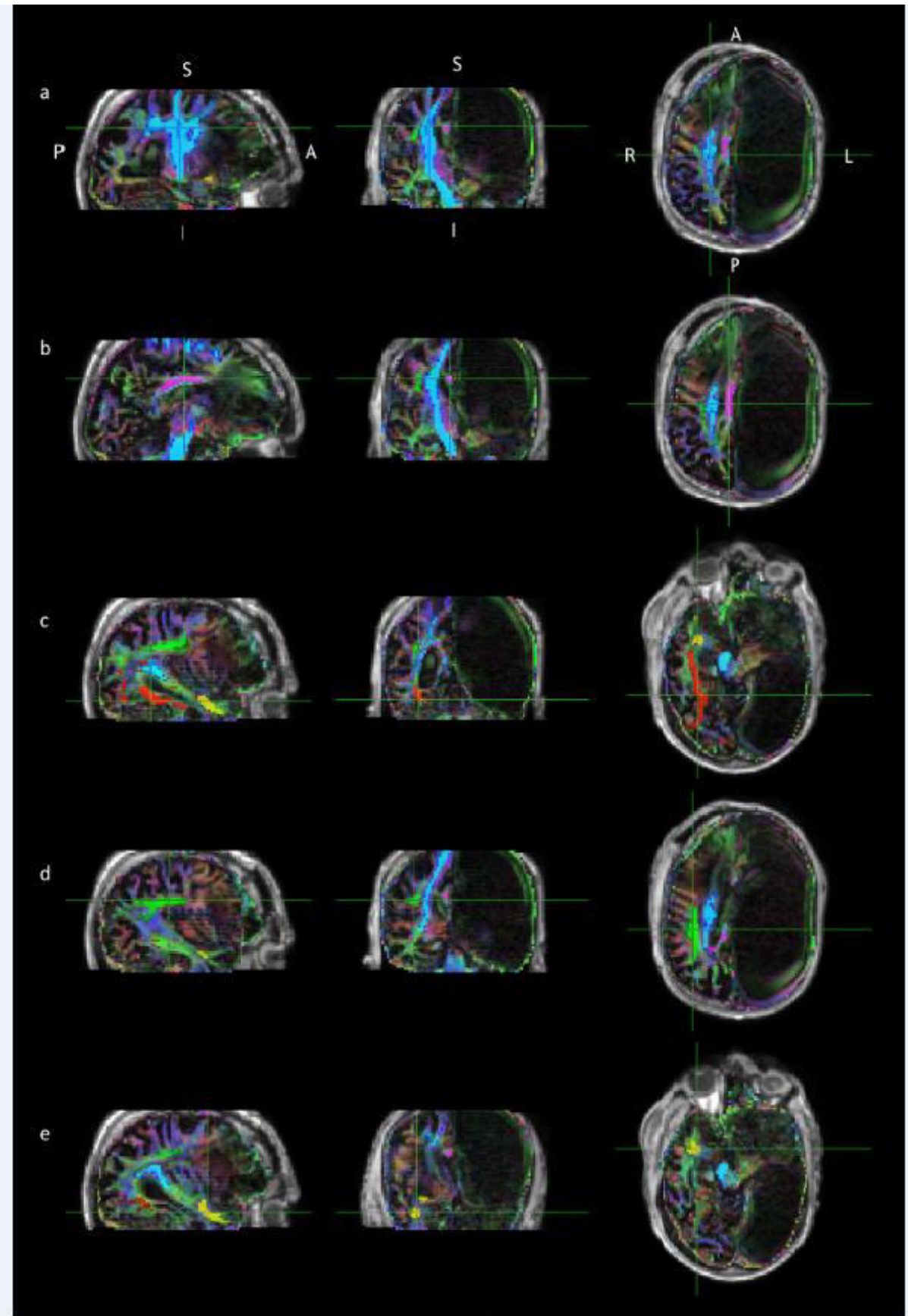
4 Department of Neuropsychology, Max Planck Institute for Human Cognitive and Brain Sciences, Leipzig, Germany

Address correspondence to Juliane Becker, Department of Neurosurgery, University Hospital Schleswig-Holstein, Arnold-Heller-Straße 3, D-24105 Kiel, Germany

Phone: +49431-597 4915

Fax: +49431-597 4981

E-Mail: juliane.becker@uksh.de



S-Fig. 1 Probabilistic tractography of main fibre tracts following the procedure outlined by Behrens et al. [1] **First row (a):** cortico-spinal tract (blue) **Second row (b):** cingulum (pink) **Third row (c):** inferior fronto-occipital fasciculus (red) **Fourth row (d):** arcuate fasciculus (green) **Fifth row (e):** uncinate fasciculus (yellow); A = anterior, P = posterior, L = left, R = right, S = superior, I = inferior

Additional information on methods and graphics programs used to create the artwork

The following programs were used to create the figures: Philips-Software from Phillips MRI-Scanner (“View Bold”), MRICron for Fig. 1, (<http://www.mccauslandcenter.sc.edu/mricro/mricron/>), ImageJ for Fig. 2 (<http://imagej.nih.gov/ij/>), MRICro for Fig. 3 (<http://www.mccauslandcenter.sc.edu/mricro/>), Diffusion Toolkit and TrackVis for Fig. 4 (<http://trackvis.org/>), and BedpostX, ProbtrackX, and fslview from fsl for Fig. S-Fig. 1 (<http://fsl.fmrib.ox.ac.uk/fsl/fslwiki/fsl>),

References

1. Behrens, T E J, Woolrich MW, Jenkinson M, Johansen-Berg H, Nunes RG, Clare S, Matthews PM, Brady JM, Smith SM (2003) Characterization and propagation of uncertainty in diffusion-weighted MR imaging. *Magnetic resonance in medicine* 50(5): 1077–1088

Curriculum Vitae

Juliane Becker

18.03.1985

deutsche Staatsangehörigkeit

06/2013 –
01/2017

Promotion zum Dr. phil. an der Christian-Albrechts-Universität, Kiel

01/2011 –
12/2016

Wissenschaftliche Mitarbeiterin in der Klinik für Neurochirurgie, UKSH, Campus Kiel

2004 - 2010

Studium der Psychologie an der Christian-Albrechts-Universität, Kiel